

Available online at www.sciencedirect.com

ScienceDirect

journal homepage: www.elsevier.com/locate/radcr

Spinal arteriovenous malformations causing Foix-Alajouanine syndrome, a case report and review of the literature ☆,☆☆

Nahid Sadighi, MD^a, Abasin Tajmalzai, MD^{b,*}, Faeze Salahshour, MD^c

^aDepartment of Radiology, Tehran University of Medical Sciences, Tehran, Iran

^bDepartment of Radiology, Kabul University of Medical Sciences, Kabul, Afghanistan

^cDepartment of Radiology, Tehran University of Medical Sciences (TUMS), Tehran, Iran

ARTICLE INFO

Article history:

Received 30 April 2021

Revised 16 May 2021

Accepted 16 May 2021

Keywords:

Foix-Alajouanine syndrome

AVM

AVF

MRI

ABSTRACT

Foix-Alajouanine syndrome is a rare progressive form of spinal AVM predominantly affecting the lower thoracic and/or lumbosacral regions. This study aims to describe the imaging findings of spinal AVM causing Foix-Alajouanine syndrome and to review the literature. We present a 48-year-old man with progressive back pain, leg weakness, and gait imbalance without urinary retention. We discuss the clinical and imaging findings and the significance of MRI in establishing the diagnosis. A definitive diagnosis of spinal AVM requires radiographic demonstration of the vascular anomaly. Despite the high sensitivity of angiography for the diagnosis of spinal AVM, the result of the study may be inconclusive and/or negative. The key MRI findings are the presence of abnormally dilated perimedullary vessels with signal voids from a high-velocity flow on T1 and T2 weighted images.

© 2021 The Authors. Published by Elsevier Inc. on behalf of University of Washington.

This is an open access article under the CC BY-NC-ND license

(<http://creativecommons.org/licenses/by-nc-nd/4.0/>)

Background

Spinal arteriovenous malformation (AVM) is characterized by an abnormal shunt between the artery and vein. Spinal AVM represent about 25% of spinal vascular malformations which are broadly classified into 2 groups; intramedullary and extramedullary [1]. The most common classification system separates spinal AVM into the following 4 types: spinal dural ar-

teriovenous fistula (AVF) with a single coiled vessel (Type I), intramedullary glomus AVM (Type II), extensive juvenile or metamerically intramedullary AVM (Type III), and intradural perimedullary spinal cord AVFs (Type IV) which is further subdivided into 3 subtypes; a single feeding artery with single small AVF and slow ascending perimedullary venous drainage (Subtype I), multiple feeding arteries with multiple medium sizes AVFs and relatively slow ascending perimedullary venous drainage (Subtype II), and multiple feeding arteries with

Abbreviations: AVF, arteriovenous fistula; AVM, arteriovenous malformation; DSA, digital subtraction angiography; MOG, myelin oligodendrocyte glycoprotein; MRI, magnetic resonance imaging; NMOSD, neuromyelitis optica spectrum disorder; STIR, short-T1 inversion recovery; T1WI, T1-weighted image; T2WI, T2-weighted image.

☆ Acknowledgments: Not applicable

☆☆ Competing Interest: The authors declare that they have no competing interests and their work is not funded by any institution or organ.

* Corresponding author.

E-mail address: abasin.tajmalzai@yahoo.com (A. Tajmalzai).

<https://doi.org/10.1016/j.radcr.2021.05.048>

1930-0433/© 2021 The Authors. Published by Elsevier Inc. on behalf of University of Washington. This is an open access article under the CC BY-NC-ND license (<http://creativecommons.org/licenses/by-nc-nd/4.0/>)

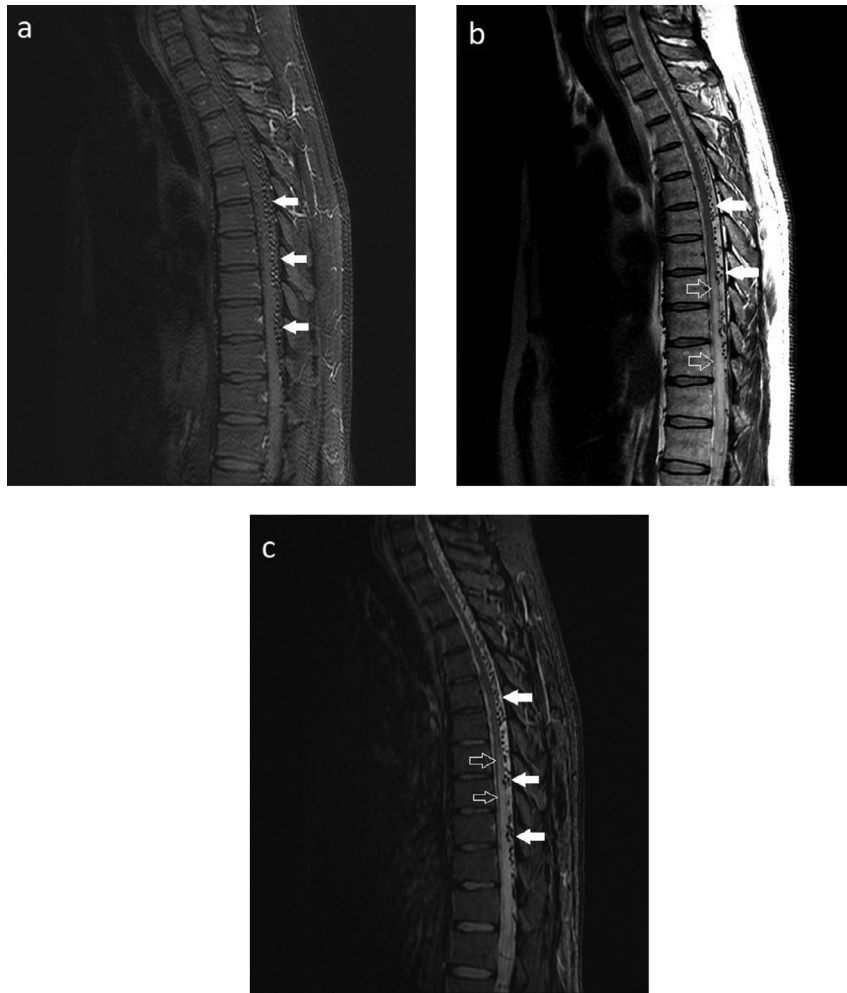

Fig. 1 – (A-C). Sagittal T1W with gadolinium (A), T2W (B), and T2W STIR (C) MR images illustrating abnormally dilated perimedullary vessels in the posterior epidural space of the entire thecal sac of the dorsal and lumbar regions which shows signal voids from high-velocity flow (white solid arrows). Edema and swelling of the mid-dorsal cord down to the conus medullaris are also noted (white hollow arrows).

a single giant AVF and extensive ectatic venous drainage (Sub-type III) [1-3].

Enlarged, tortuous, and thick-walled subarachnoid veins with masslike appearance are usually observed overlying the surface (primarily on the posterior aspect) of the spinal cord. Smaller blood vessels with thickened fibrotic walls are also present within the affected spinal cord segments [4]. These AV shunts are associated with reflux of arterial blood into the venous drainage and cause congestion of venous outflow of the cord, resulting in increased venous pressure in the affected regions, which often leads to ischemic spinal cord injury [5].

Foix-Alajouanine syndrome which was first described by Foix and Alajouanine in 1926, is a rare cause of myelopathy caused by dural arteriovenous malformations of the spinal cord. This syndrome is a progressive form of spinal AVM predominantly affecting the lower thoracic and/or lumbosacral regions. Cervical spinal cord involvement is rarely seen. No specific statistics are available about its frequency and the condition is likely underdiagnosed. It has a male-to-female

ratio of 4:1 with no racial predilection. Although it is a well-known clinical entity in the neurosurgic setting, the exact cause of this syndrome is not well understood. Most patients have an AVF in the lower thoracic region. There is an etiologic hypothesis that the elevated arterial pressure within the dura is transmitted through the intraductal venous system to the spinal vascular plexus, compromising blood supply and leading to spinal cord parenchymal infarction. Arterial blood originating from the dural fistula enters the venous system, increases the pressure, and disrupts the normal drainage of the spinal cord parenchyma. The primary cause of cord infarction may be venous stasis, not thrombosis, as venous thrombosis usually occurs in the late course of the disease [4,6,7]. The present case highlights an important point, that when the clinical and radiological suspicion for a spinal vascular lesion is high, an initial negative or inconclusive DSA does not rule out spinal AVM and should not mislead the clinicians. Follow-up imaging with MRI and/or DSA should be recommended at appropriate intervals.

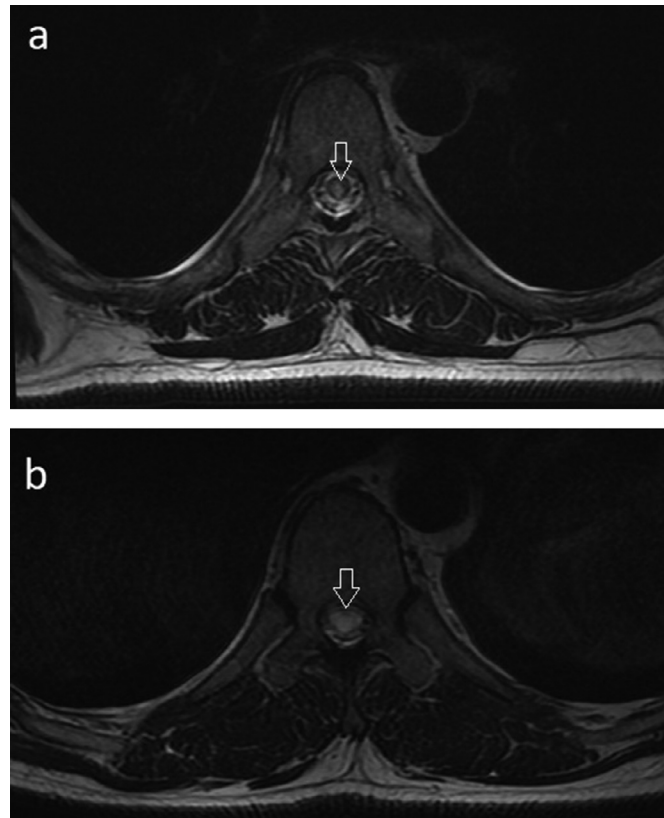


Fig. 2 – (A-B). Axial T2W (A) MR image showing spinal cord edema at mid-dorsal cord level (white hollow arrow). Axial T2W (B) MR image showing extensive spinal cord edema and swelling at conus medullaris (white hollow arrow).

Case Presentation

A 48-year-old man presented to the neurology department of our hospital with back pain, lower limb weakness, and gait imbalance for 2 years, which is progressing slowly and recently worsened. Physical examination revealed paresis and muscular wasting of both legs. The patellar reflex and the plantar cutaneous reflex were bilaterally lowered and indifferent. He was a smoker but not an alcoholic and has no history of previous surgery, diabetes, hypertension, or any other chronic health conditions. The sphincter's function was normal (no urinary retention). He was not taking any specific medication and did all his childhood vaccination on time. His spinal fluid analysis was unremarkable. Aquaporin-4 antibody and anti-MOG antibody tests were also negative. A contrast-enhanced spinal MRI was performed which revealed extensive abnormally dilated perimedullary vessels in the entire thecal sac of the thoracolumbar region. These abnormally dilated vessels show signal voids from a high-velocity flow on T1-weighted image (T1WI), T2-weighted image (T2WI), and short-T1 inversion recovery (STIR) image (Figs 1A and c). Most of the abnormally dilated vessels are in the posterior epidural space which slightly indents and/or scallop the spinal cord anteriorly. Increased signal intensity and swelling of the spinal cord due to cytotoxic edema or myelomalacia are also seen in the mid-dorsal cord down to the conus medullaris on T2WI (Figs. 1B and -C, 2A and B). The patient had a negative MRI

cervical spine imaging. No cord atrophy or any obvious intramedullary component was seen. The patient also underwent spinal angiography via external carotid arteries, vertebral arteries, subclavian arteries, and aortogram. No obvious vascular pathology was observed on the angiographic study, probably due to multiple origins feeding arteries or very small vessels that are not adequately filled with contrast. The above-mentioned clinical, laboratory, and MRI findings are characteristic of the spinal AVM (type IV) causing Foix-Alajouanine syndrome. Although other condition with transverse myelitis including neuromyelitis optica spectrum disorder (NMOSD) can demonstrate similar imaging findings of longitudinally extensive high T2 signal involving the spinal cord, in the present case, the presence of abnormally dilated perimedullary vessels with flow void in the posterior epidural space of the thoracolumbar region is in favor of vascular malformations. The patient was managed conservatively and eventually discharged with a minimal improvement of the clinical symptoms. A 6 months' later control imaging follow-up was recommended for the patient.

Discussion

Spinal AVM are characterized by an abnormal shunting between the artery and vein with and/or without a true nidus. They represent about 25% of spinal vascular malformations

[1]. The clinical presentation of AVM is variable, ranging from slowly progressive myelopathy with neurologic deficits (Foix-Alajouanine syndrome), to a rapidly progressive form with spinal subarachnoid hemorrhage (coup de poignard of Michon) [8]. Foix-Alajouanine syndrome is not a distinct entity but a complication of spinal AVM probably caused by venous stasis and thrombosis of the abnormally dilated vessels of the spinal cord. This syndrome is the end-stage of progressive myelopathy due to venous congestion that develops gradually over 1-5 years. Patients with Foix-Alajouanine syndrome may present with increasing unilateral and/or bilateral weakness, dysesthesias, and numbness or tingling in the lower extremities, which may be symmetrical or asymmetrical. Problems with bowel, bladder, and sexual function are also seen [8-10]. Complaints of non-radiating lower back pain in the lumbosacral or coccygeal regions, that may initially be interpreted as sciatica are common. Weakness or numbness eventually can progress to the upper extremities. In most patients, Foix-Alajouanine syndrome follows a protracted course of a few years before a diagnosis is made, however, in a minority of patients, acute onset of symptoms is also reported [11]. In the present case, the patient presented with back pain, lower limb weakness and paresis, gait imbalance, and muscular wasting of both legs which slowly progress over 2 years and has recently worsened.

Radiological evaluation is important which allows the referring physician; to differentiate the syndrome from other causes of progressive myelopathy, follow-up the patients, and develop a correct management plan to prevent disease progression.

MRI and digital subtraction angiography (DSA) are 2 important imaging modalities with the ability to accurately diagnose spinal vascular anomalies including spinal AVM. MRI studies may be normal during the early stages of Foix-Alajouanine syndrome, but with disease progression, T1WI can reveal swelling of the cord and decreased signal intensity peripherally within the affected spinal cord levels. On T2WI, the spinal cord lesions are hyperintense in central locations. Contrast administration often produces serpentine areas of enhancement and reveals the presence of enlarged, tortuous vessels in the subarachnoid space with associated "flow void" phenomena. MR angiograms can predict the site and extent of the fistula before the use of the more invasive technique of catheter angiography. MR angiograms generally demonstrate flow in serpentine perimedullary vessels. In general, the key MRI findings of spinal cord AVM are: signal voids from the high-velocity flow and dilated perimedullary vessels which may indent and/or scallop the cord, and increased cord signal due to cytotoxic edema or myelomalacia [1,4,6,7,12]. Conventional intra-arterial DSA is the standard for the diagnosis, treatment evaluation, and follow-up examination for spinal AVM. Immediately after surgical or endovascular treatment, DSA is usually performed to evaluate the success of treatment. In the follow-up period, DSA is performed when the patient symptoms worsen [12-14]. Despite the high sensitivity of angiography for the diagnosis of spinal cord AVM, in some cases, the result of the study may be inconclusive and/or negative for Foix-Alajouanine syndrome. Van Dijk et al. described 2 cases with normal angiograms for spinal AV fistula, although the patients had classic clinical signs and symptoms, and MRI find-

ings. Criscuolo et al. also reported 2 patients with the diagnosis of Foix-Alajouanine syndrome and negative spinal arteriography [15,16]. In the present case, however, suggestive defects of arteriovenous malformations could not be seen on the angiographic study, probably due to very small vessels of different origins, but the MRI findings were very useful and characteristic for the diagnosis of spinal AVM causing Foix-Alajouanine syndrome.

There is a long list of differential diagnoses of spinal AVM which can be divided into 2 categories. The first category includes conditions mimicking the clinical picture of spinal AVM but has typical radiological features such as vertebral disk syndromes, polyradiculopathy, spinal injury, spinal epidural hemorrhage and/or abscess, primary or metastatic neoplastic diseases, and so on. The second category includes diseases causing almost similar imaging findings of transverse myelitis such as multiple sclerosis, systemic autoimmune diseases, post-vaccinated conditions, vasculitis, paraneoplastic syndrome, and infectious diseases. Clinical history, laboratory examination, and radiological findings together play an important role in the differential diagnosis of spinal AVM. Conditions associated with transverse myelitis including neuromyelitis optica spectrum disorder (NMOSD) can demonstrate similar imaging findings of longitudinally extensive high T2 signal involving the spinal cord, but the presence of abnormally dilated perimedullary vessels with flow void in the posterior epidural space of the thoracolumbar region, as seen in the present case, is highly suggestive of spinal vascular malformations [17-19].

The choice of treatment for Foix-Alajouanine syndrome is either endovascular embolization or surgical ligation of the fistula; in some cases, both modalities are used. Initially, the affected patients have spastic paraplegia which may eventually develop flaccid paralysis of the limbs with and/or without loss of sphincter control and may even become wheelchair-bound. Death can occur with terminal sepsis or other sequelae. The prognosis is poor if treatment is not administered before neurologic deterioration occurs [11,17].

Conclusion

A definitive diagnosis of spinal AVM causing Foix-Alajouanine syndrome requires radiographic demonstration of the vascular anomaly usually made by MRI and/or angiography. Despite the high sensitivity of the angiography for the diagnosis of spinal cord AVM, the result of the study may be inconclusive and/or negative. Enhanced MRI of the spine is the first-line diagnostic procedure in patients with spinal AVM and provides valuable information. The key MRI findings are abnormally dilated perimedullary vessels with signal voids from a high-velocity flow on T1 and T2 weighted images.

Patient consent

Written informed consent was obtained for publication of this case report and any accompanying images.

Authors' contributions

Concept-AT, NS; Radiological diagnosis-NS; Resources & data collection-AT; Literature research and writing the manuscript-AT; Critical review-NS & FS. All authors have read and approved the final manuscript.

REFERENCES

- [1] Minami S, Sagoh T, Nishimura K, Yamashita K, Fujisawa I, Noma S, et al. Spinal arteriovenous malformation: MR imaging. *Radiology* 1988;169(1):109–15. doi:10.1148/radiology.169.1.3420244.
- [2] Doppman JL, Di Chiro G, Oldfield EH. Origin of spinal arteriovenous malformation and normal cord vasculature from a common segmental artery: angiographic and therapeutic considerations. *Radiology* 1985;154(3):687–9. doi:10.1148/radiology.154.3.3969471.
- [3] Kim LJ, Spetzler RF. Classification and surgical management of spinal arteriovenous lesions: arteriovenous fistulae and arteriovenous malformations. *Neurosurgery* 2006;59(5 Suppl 3):S195–201. doi:10.1227/01.NEU.0000237335.82234.CE.
- [4] Rodriguez FJ, Crum BA, Krauss WE, Scheithauer BW, Giannini C. Venous congestive myelopathy: a mimic of neoplasia. *Mod Pathol* 2005;18(5):710–18. doi:10.1038/modpathol.3800350.
- [5] Krishnan P, Banerjee TK, Saha M. Congestive myelopathy (Foix-Alajouanine Syndrome) due to intradural arteriovenous fistula of the filum terminale fed by anterior spinal artery: Case report and review of literature. *Ann Indian Acad Neurol* 2013;16(3):432–6. doi:10.4103/0972-2327.116931.
- [6] Di Chiro G. Foix-Alajouanine syndrome. *AJNR Am J Neuroradiol* 1990;11(6):1286.
- [7] Ferrell AS, Tubbs RS, Acakpo-Satchivi L, Deveikis JP, Harrigan MR. Legacy and current understanding of the often-misunderstood Foix-Alajouanine syndrome. Historical vignette. *J Neurosurg Nov* 2009;111(5):902–6. doi:10.3171/2007.11.17656.
- [8] Greenberg MS. *Handbook of neurosurgery*. 7th edition. New York, NY: Thieme Medical Publishers; 2010. ISBN: 978-1-60406-326-4.
- [9] Iovtchev I, Hiller N, Ofra Y, Schwartz I, Cohen J, Rubin SA, et al. Late diagnosis of spinal dural arteriovenous fistulas resulting in severe lower-extremity weakness: a case series. *Spine J* 2015;15(6):e39–44. doi:10.1016/j.spinee.2013.08.029.
- [10] Bordignon KC, Montú MB, Ramina R, Arruda WO. Foix-Alajouanine syndrome: case report. *Arq Neuropsiquiatr* 2005;63(2B):527–9. doi:10.1590/s0004-282x2005000300030.
- [11] Mishra R, Kaw R. Foix-Alajouanine syndrome: an uncommon cause of myelopathy from an anatomic variant circulation. *South Med J* 2005;98(5):567–9. doi:10.1097/01.SMJ.0000154409.48800.43.
- [12] Rodesch G, Lasjaunias P. Spinal cord arteriovenous shunts: from imaging to management. *Eur J Radiol* 2003;46(3):221–32. doi:10.1016/s0720-048x(03)00093-7.
- [13] Veznedaroglu E, Nelson PK, Jabbour PM, Rosenwasser RH. Endovascular treatment of spinal cord arteriovenous malformations. *Neurosurgery* 2006;59(5 Suppl 3):S202–9. doi:10.1227/01.NEU.0000237409.28906.96.
- [14] Narvid J, Hetts SW, Larsen D, Neuhaus J, Singh TP, McSwain H, et al. Spinal dural arteriovenous fistulae: clinical features and long-term results. *Neurosurgery* 2008;62(1):159–66. doi:10.1227/01.NEU.0000311073.71733.C4.
- [15] Criscuolo GR, Oldfield EH, Doppman JL. Reversible acute and subacute myelopathy in patients with dural arteriovenous fistulas. Foix-Alajouanine syndrome reconsidered. *J Neurosurg* 1989;70(3):354–9. doi:10.3171/jns.1989.70.3.0354.
- [16] Van Dijk JM, TerBrugge KG, Willinsky RA, Farb RI, Wallace MC. Multidisciplinary management of spinal dural arteriovenous fistulas: clinical presentation and long-term follow-up in 49 patients. *Stroke* 2002;33(6):1578–83. doi:10.1161/01.str.0000018009.83713.06.
- [17] Jellema K, Tijssen CC, van Gijn J. Spinal dural arteriovenous fistulas: a congestive myelopathy that initially mimics a peripheral nerve disorder. *Brain* 2006;129(Pt 12):3150–64. doi:10.1093/brain/awl220.
- [18] Suthiphosuwat S, Oh J, Bharatha A. Clinical pitfall: false-positive aquaporin-4 IgG leading to misdiagnosis of neuromyelitis optica spectrum disorder in patient with spinal arteriovenous fistula. *Spinal Cord Ser Cases*. 2017;3:17030. doi: 10.1038/scsandc.2017.30..
- [19] Rathnam AS, Memon AB. Foix-alajouanine syndrome mimicking longitudinally extensive transverse myelitis. *Eur J Case Rep Intern Med* 2020 Nov 10;7(12):002063. doi:10.12890/2020_002063.