



## Identification of a Dental Anomaly in a Tiriyo Indigenous Park Patient by Computed Tomography: A Case Report

Patrícia de Almeida Rodrigues<sup>a\*</sup> , Camila Ribeiro Ribeiro<sup>a</sup> , Bianca Rodrigues de Freitas<sup>a</sup> ,  
Thamires Campos Gomes<sup>b</sup> , Ellen Gaby Neves Rocha<sup>a</sup> , Fabrício Mesquita Tuji<sup>a</sup>

<sup>a</sup> Pará State University Center, Belém, Pará, Brazil; <sup>b</sup> Federal University of Pará, Belém, Pará, Brazil

### ARTICLE INFO

Article Type: Case Report

Received: 11 Dec 2018

Revised: 13 Feb 2019

Accepted: 27 Feb 2019

Doi: 10.22037/iej.v14i2.23354

\*Corresponding author: Patrícia de Almeida Rodrigues, Centro Universitário do Pará, Clínica Odontológica, Travessa Nove de Janeiro; n 927; São Brás; CEP: 66037000; Belém, PA, Brazil.

E-mail: patriciasouza@cesupa.br



© The Author(s). 2018 Open Access This work is licensed under the terms of the Creative Commons Attribution-NonCommercial-ShareAlike 4.0 International.

### ABSTRACT

This report describes anatomical variations in an indigenous patient from the Brazilian Amazon. A 13-year-old indigenous girl attended the dental clinic for a routine examination. Clinically, a change in the coronary morphology of all upper incisors was observed; characterized by a shovel-shaped lingual surface—a feature considered a polygenic hereditary trait commonly found in native American people. The x-ray examination revealed the presence of a root anomaly in the left upper central incisor. A cone-beam computed tomography (CBCT) scan was performed, revealing the presence of a supernumerary root located on the lingual surface. A single wide canal, which bifurcated in the middle-third level into two canals with different foramina, was observed in the cervical portion. It is essential for dental surgeons to be aware of possible anatomical differences, especially considering the origin of the patient, to avoid interference in treatment success.

**Keywords:** Abnormalities; Cone-beam Computed Tomography; Health Services; Indigenous; Tooth Root

### Introduction

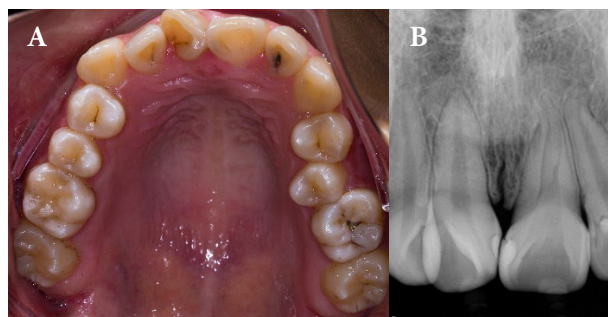
The dental anatomy has basic genetically transmitted and secondary traits. These traits are observable and related to number of cusps, dimensions and shapes of crowns, and number of roots in each group of teeth found in humans. However, these traits can vary. The importance of studying dental morphological traits, in the context of anthropology, allows the acquisition of knowledge and possible comparative analysis amongst human races. These studies are an attempt to clarify the biological differences of humans and contribute to the recognition of characteristics of a particular human race [1-3].

Shovel-shaped incisors have coronary changes, and are considered as a morphological trait on the lingual surface. They have a deep triangular or round fossa, thick marginal ridges that cover the cervical region, a prominent cingulum, and a broad and convex buccal surface in the cervical-incisal direction [4].

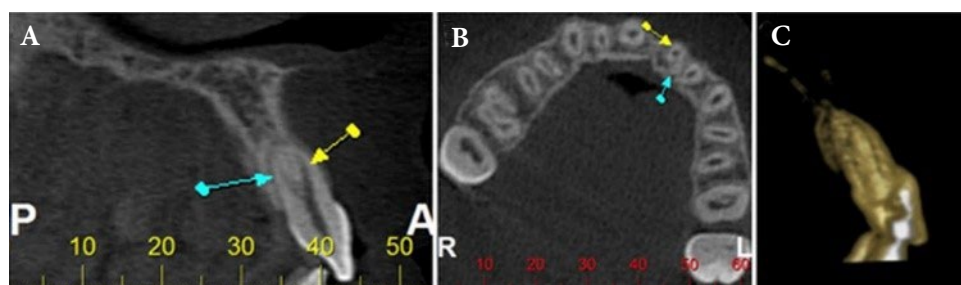
This anatomical alteration was observed in American Indians for the first time [4] and was later observed in other populations [1, 5, 6]. High incidence rates of shovel-shaped incisors have been reported in an Argentinean population and also, in indigenous groups of the Colombian Amazon [7, 8].

The internal anatomy of the upper incisors is usually simple, with a root and root canal [9-12]. However, some reports in the literature describe anatomical variations in the number of canals and roots [13-16] which occur in approximately 2% to 4% of cases [17, 18].

Periapical and panoramic radiographs are widely used in planning dental procedures. However, they provide only a two-dimensional representation of three-dimensional anatomical structures [19]. Currently, the American Association of Endodontists (AAE) and the American Academy of Oral and Maxillofacial Radiology (AAOMR) recommend that “Cone-beam Computed Tomography” (CBCT) should be considered the imaging



**Figure 1.** A) Intraoral photograph, shovel-shaped anatomical change in the upper incisors; B) Digital periapical radiograph with non-defined anatomical alteration



**Figure 2.** A) Sagittal section, buccal root (yellow arrow) and lingual root (green arrow); B) Axial cut, bifurcation of the two roots; C) 3D reconstruction, mesial aspect of the maxillary left central incisor

modality of choice for the initial treatment of teeth with the possibility of extra canals and/or suspected complex morphology [20].

The aim of this report was to demonstrate anatomical variations in the upper central incisors that may exist in patients of indigenous origin.

## Case Report

A 13-year-old indigenous girl from the Tiriyo tribe of the Missão Nova indigenous village in the Brazilian Amazon attended the dental clinic of Pará State University Center (Centro Universitário do Estado do Pará, CESUPA) for routine consultation. In the clinical interview, no medical changes were reported. During the clinical examination, dental crowding and altered coronary morphology of all upper incisors were observed, with well delimited and prominent marginal ridges, giving the lingual surface a shovel-like appearance (Figure 1A). In addition, carious lesions without pain were observed in these teeth.

X-ray examination revealed the presence of a root anomaly in the left upper central incisor, but it was not possible to define the type of anatomical variation. The initial diagnostic suspicion was dens invaginatus (Figure 1B). Vitality tests were in normal limits and clinically, no signs or symptoms outside normal tooth patterns were present. A CBCT scan was performed, to obtain a better anatomical survey of the tooth, which then became essential for the diagnosis of the case.

The examination was performed by volumetric acquisition on an I-Cat tomography device (Imaging Sciences, Kavo, Hatfield, PA, USA). The CBCT scan revealed the presence of a supernumerary root (sagittal slice) located on the lingual surface of the left upper central incisor (Figure 2). Three-dimensional reconstruction was performed to conduct a better spatial evaluation of the tooth in question and facilitate visualization of the anomaly. A single, bulky canal was observed in the cervical portion. In the middle-third level, at 13.5 mm, the main canal divided into two canals, buccal and lingual, ending in different foramina. The lingual canal was less bulky and had a shorter length than the buccal canal.

## Discussion

Knowledge of dental morphology and careful interpretation of radiographic examinations are essential prerequisites for successful treatment [11]. Using the information observed on radiographs, along with knowledge of possible internal anatomies, dentists should be able to determine which type of canal configuration is present. This information, obtained prior to the initiation of therapy, will greatly facilitate the subsequent treatment. The lack of knowledge of the internal anatomy and non-recognition of an additional canal are one of the main reasons for failure of endodontic therapy [10, 21].

A probable origin for teeth with a supernumerary root is the bilateral growth of tissue flaps from Hertwig's epithelial sheath that merge and form a template for a bi-rooted tooth [22]. Root canal morphology may vary as a result of many factors, including cellular changes induced by the environment or of genetic origin, including the ethnic origin [12, 23].

The shovel-shaped incisor is predominant in Asian populations, Asian descendants and Amerindians and is rare or almost entirely absent in African and European populations [5]. This characteristic is considered as a polygenic hereditary trait, and its absence is deemed a criterion to attribute a Caucasian origin to a population [4, 24]. Since the report by Hrdlička [4] of shovel-shaped incisors in 1920, this phenomenon has been considered a Mongoloid dentition trait. Its high prevalence has been reported in indigenous races of Brazil, Venezuela and Chile [7]. This case reported a patient of indigenous origin, belonging to the Tiriyo tribe -an indigenous group that inhabits in northern Brazil, more precisely in Pará state, as well as Suriname- representing an example.

This dental anomaly may also be associated with some syndromes such as Apert syndrome [25] and Ekman-Westborg-Julín trait [26]. However, the patient did not present other signs and symptoms that could indicate the presence of any syndromes. The presence of this morphological alteration in other members of the Tiriyo tribe was also reported in clinical interview, corroborating with the hypothesis of being a genetic trait.

The literature reports several cases in which a combination of shovel-shaped teeth and dens invaginatus were observed [27, 28]. However, no case of a patient, presenting shovel-shaped incisors combined with a supernumerary root, has been reported; and thus, this case was probably atypical.

In the case presented, the initial hypothesis was dens invaginatus. When dens invaginatus is present, there is an increased risk of tooth cavities due to greater accumulation of debris in these teeth. Therefore, it is crucial to provide oral hygiene instructions to such patients. For this reason, in cases of suspected anomaly, a correct diagnosis becomes very important [29].

Imaging examinations, such as periapical radiography at different angles and CBCT, are methods that aid in the diagnosis of the problem [13]. CBCT is an increasingly used resource that provides accurate three dimensional anatomical details for the diagnosis and planning of the treatment prior to dental therapy [17]. It is thus an important tool, particularly in endodontics, where the configuration of the root canal system can present variations that will interfere with the successful treatment.

## Conclusion

It is essential for dental surgeons to be aware of such possible anatomical differences, especially considering the origin of the patient.

## Acknowledgement

The authors are grateful to PROPEP (Pro-rector of research and post-graduation of Federal University of Pará) for supporting this study.

Conflict of Interest: 'None declared'.

## References

- Díaz E, García L, Hernández M, Palacio L, Ruiz D, Velandia N, Villavicencio J, Moreno F. Frequency and variability of dental morphology in deciduous and permanent dentition of a Nasa indigenous group in the municipality of Morales, Cauca, Colombia. *Colombia Médica*. 2014;45(1):15-24.
- Kimura R, Yamaguchi T, Takeda M, Kondo O, Toma T, Haneji K, Hanihara T, Matsukusa H, Kawamura S, Maki K, Osawa M, Ishida H, Oota H. A Common Variation in EDAR Is a Genetic Determinant of Shovel-Shaped Incisors. *Am J Hum Genet*. 2009;85(4):528-35.
- Rodríguez Flórez CD. Antropología dental en Colombia . Comienzos, estado actual y perspectivas de investigación. *Antropo*. 2003;4:17-27.
- Hrdlička A. Shovel-Shaped Teeth. *Am J Phys Anthropol*. 1920;3(4):429-65.
- Canger EM, Çelenk P, Çankaya S. Shovel-shaped incisors in the Black Sea region population of Turkey. *J Dent Sci*. 2014;9(3):253-7.
- Hasegawa Y, Terada K, Kageyama I, Tsukada S, Uzuka S, Nakahara R, Nakahara S. Influence of shovel-shaped incisors on the dental arch crowding in Mongolian females. *Okajimas Folia Anat Jpn*. 2009;86(2):67-72.
- Devoto C, Arias N, Ringuélet S, Palma N. Shovel-shaped incisors in a North Western Argentine population. *J Dent Res*. 1968;47(5):820-3.
- Aragón N, Bastidas C, Bedón LK, Duque P, Sánchez M, Rivera S, Triana F, Bedoya IIN, Od FM. Rasgos morfológicos dentales corales en dentición temporal y permanente: Distancia biológica entre tres grupos indígenas del Amazonas Colombiano. *Rev Odontol (B Aires)*. 2008;12(1):13-28.
- Cantatore G, Berutti E, Castellucci A. Missed anatomy: frequency and clinical impact. *Endod Topics*. 2006;15(1):3-31.
- Vertucci FJ. Root canal anatomy of the human permanent teeth. *Oral Surg Oral Med Oral Pathol*. 1984;58(5):589-99.

11. Vertucci FJ. Root canal morphology and its relationship to endodontic procedures. *Endod Topics*. 2005;10(1):3-29.
12. Sert S, Bayirli GS. Evaluation of the Root Canal Configurations of the Mandibular and Maxillary Permanent Teeth by. *J Endod*. 2004;30(6):391-8.
13. Sponchiado EC, Awwad H, Qader A. Maxillary Central Incisor With Two Root Canals : A Case Report. *J Endod*. 2006;32(40):1002-4.
14. Gondim E, Setzer F, Zingg P. A Maxillary Central Incisor with Three Root Canals : A Case Report. *J Endod*. 2009;35(10):1445-7.
15. Saberi E, Bijari S, Farahi F. Endodontic Treatment of a Maxillary Lateral Incisor with Two Canals: A Case Report. *Iran Endod J*. 2018;13(3):406-8.
16. Shubbar A, Bolhari B, Fakhari N, Alemi P, Nosrat A. Non-Surgical Retreatment of Maxillary Lateral Incisor with Unusual Anatomy: A Case Report and Mini Review. *Iran Endod J*. 2017;12(3):381-5.
17. Silva E, JNLd, Castro RWQd, Silva AIV, Haiter-Neto F, Silberman A, Cohenca N. Evaluation of root canal configuration of maxillary and mandibular anterior teeth using cone beam computed tomography : An in-vivo study. *Quintessence Int*. 2016;47(1):19-24.
18. Rahimi S, Shahi S, Yavari HR, Reyhani MF, Ebrahimi ME, Rajabi E. A stereomicroscopy study of root apices of human maxillary central incisors and mandibular second premolars in an Iranian population. *J Oral Sci*. 2009;51(3):411-5.
19. Patel S, Horner K. The use of cone beam computed tomography in endodontics. *Int Endod J*. 2009;42(9):755-6.
20. AAE and AAOMR Joint Position Statement: Use of Cone Beam Computed Tomography in Endodontics 2015 Update. *J Endod*. 2015;41(9):1393-6.
21. Vertucci FJ. Root canal anatomy of the mandibular anterior teeth. *J Am Dent Associat* (1939). 1974;89(2):369-71.
22. Kelly JR. Birooted Primaty Canines. *Oral Surg Oral Med Oral Pathol*. 1978;46(6):872-.
23. Mochizuki K, Ohtawa Y, Kubo S, Machida Y. Bifurcation , birooted primary canines : a case report. *Int J Paediatric Dent*. 2001;3:380-5.
24. Saini TS, Kharat DU, Mokeem S. Prevalence of shovel-shaped incisors in Saudi Arabian dental patients. *Oral Surg Oral Med Oral Pathol*. 1990;70(4):540-4.
25. Gawande M, Chaudhary M, Patel M. Apert's Syndrome: A Case Report with Review International *J Oral & Max Pathol*. 2012;3(4):39-43.
26. Nakajima J, Nakayama H, Higuchi K, Takano Y, Sato Y. A variant of the Ekman-Westborg-Julin trait. A case report and review of the literature. *J Oral Maxillofac Surg Med Pathol*. 2016;28(1):30-5.
27. Miles AEW. Malformations of teeth. *Proc R Soc Med*. 1954;47(10):817-26.
28. Casimiro-Iriarte S, Caballero-García S, Geller-Palti D. Asociación del Dens in Dente con el Diente en Pala y Diente Cónico en Piezas Anteriores. *Odontol Pediatr*. 2016;15(1):16-25.
29. de Oliveira NG, da Silveira MT, Batista SM, Veloso SRM, Carvalho MV, Travassos RMC. Endodontic Treatment of Complex Dens Invaginatus Teeth with Long Term Follow-Up Periods. *Iran Endod J*. 2018;13(2):263-6.

*Please cite this paper as:* de Almeida Rodrigues P, Ribeiro Ribeiro C, Rodrigues de Freitas B, Campos Gomes Th, Neves Rocha EG, Mesquita Tuji F. Identification of a Dental Anomaly in a Tiriyo Indigenous Park Patient by Computed Tomography: A Case Report. *Iran Endod J*. 2019;14(2): 152-5. Doi: 10.22037/iej.v14i2.23354.