

Available online at [www.sciencedirect.com](http://www.sciencedirect.com)

ScienceDirect

journal homepage: [www.elsevier.com/locate/radcr](http://www.elsevier.com/locate/radcr)

## Case Report

# Tuberculous peritonitis post orchiectomy for testicular tuberculosis; a case report and literature review <sup>☆</sup>

Sakher Tahaine, MD<sup>a</sup>, Rawan Abu Mughli, MD<sup>b,c</sup>, Khaled Seetan, MD<sup>d</sup>, Sulieman Alriyalat, MD<sup>a</sup>, Daniel Agahi, OSSD<sup>e,\*</sup>

<sup>a</sup> Al-Balqa' Applied University, Al-Salt, Jordan

<sup>b</sup> Sunnybrook Health Sciences Centre, Toronto, ON, Canada

<sup>c</sup> Department of Medical Imaging, University of Toronto, Toronto, ON, Canada

<sup>d</sup> Yarmouk University Faculty of Medicine, Irbid, Jordan

<sup>e</sup> University of Western Ontario, London, 106 Wood Rim dr, L4E 4M9, Richmond Hill, ON, Canada

## ARTICLE INFO

## Article history:

Received 17 September 2022

Revised 29 November 2022

Accepted 6 December 2022

## Keywords:

Tuberculous

Peritonitis

Epididymo-orchitis

## ABSTRACT

Tuberculous peritonitis, though rare, is a serious condition and its diagnosis is challenging due to nonspecific clinical symptoms and imaging findings. Likewise, tuberculous epididymo-orchitis is a clinical dilemma, as it often mimics testicular tumors. We report a case of a 62-year-old patient diagnosed to have TB peritonitis, following tuberculous epididymo-orchitis with review of the imaging features of both entities. A high index of suspicion and careful clinical assessment will help in early diagnosis and treatment of TB peritonitis, preventing potential complications. Moreover, testicular tuberculosis should be considered in the differential diagnosis of scrotal mass.

© 2022 The Authors. Published by Elsevier Inc. on behalf of University of Washington.

This is an open access article under the CC BY-NC-ND license

(<http://creativecommons.org/licenses/by-nc-nd/4.0/>)

## Introduction

Although TB peritonitis is a rare disease, its prevalence is increasing, particularly in immunosuppressed people [1]. Peritoneal involvement is mainly via a hematogenous route, directly from the gastrointestinal system, or rupture of a mesenteric lymph node [2]. Its diagnosis is quite challenging due to the nonspecific insidious presentation and lack of specific imaging criteria. TB peritonitis is associated with significant morbidity and mortality rates if not diagnosed early.

Likewise, TB epididymo-orchitis is uncommon and often mimics testicular tumors. The clinical scenario, scrotal imaging, and tumor markers may help in the diagnosis. However, surgical intervention is often required for confirmation [3].

## Case presentation

A 62-year-old male patient - not known to have any chronic medical illness - was referred to our urology clinic from the emergency department complaining of right testicular

<sup>☆</sup> Competing Interests: None.

\* Corresponding author.

E-mail address: [dagahi@uwo.ca](mailto:dagahi@uwo.ca) (D. Agahi).

<https://doi.org/10.1016/j.radcr.2022.12.011>

1930-0433/© 2022 The Authors. Published by Elsevier Inc. on behalf of University of Washington. This is an open access article under the CC BY-NC-ND license (<http://creativecommons.org/licenses/by-nc-nd/4.0/>)

swelling and pain. Physical examination was unremarkable apart from tenderness and swelling of the right testis. The patient was prescribed levofloxacin for 2 weeks for presumed bacterial epididymo-orchitis. After 3 weeks the patient returned to the clinic still complaining of the same symptoms. Scrotal ultrasound, at that visit, showed normal testis with minimal hydrocele. Three months later, the patient returned with persistent pain and swelling in the right testis. Physical examination revealed a tender mass. Scrotal ultrasound confirmed the presence of testicular mass. Serum hCG, AFP, and LDH were within normal range. Given the clinical scenario, negative tumor markers and prior normal ultrasound, the most favored diagnosis was an abscess. Scrotal MRI was also performed and showed a 28×23×31 mm peripherally enhancing testicular mass, suggestive of an abscess. Accordingly, surgery was performed. Scrotal exploration showed multi-loculated abscess and severely inflamed right testis and epididymis. The abscess was drained, and orchiectomy was done. Histopathology showed necrotizing granulomatous epididymo-orchitis highly suggestive of tuberculosis. Of note, a chest X-ray done earlier was normal.

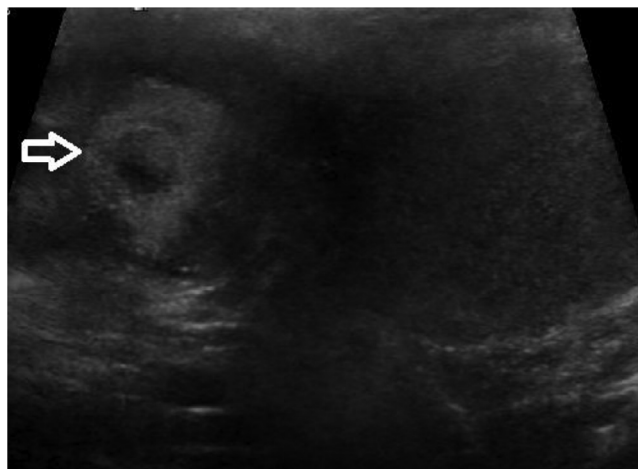The patient was referred to an infectious diseases specialist for further work up and treatment but he never went and was lost to follow-up. Three months later, the patient presented again to our urology clinic complaining of mild vague lower abdominal pain. Abdominal ultrasound showed a left inguinal hernia and possible thickening of the descending colon. Therefore, CT was performed. This showed trace free fluid in the abdomen and pelvis with stranding of the mesenteric fat planes. Given the clinical scenario, we suspected TB peritonitis and ordered TB polymerase chain reaction (PCR) test that was positive. The patient was prescribed rifamycin, isoniazid, pyrazinamide, and ethambutol for 3 months and was followed by the infectious disease team.

## Discussion

Although tuberculosis was historically linked to the lungs, in reality it can affect almost every part of the body. TB has many manifestations, affecting bone, the central nervous system, and many other organ systems [1,4]. Tuberculous peritonitis (TBP) is a rare and uncommon site of extra-pulmonary TB. TB can spread to the peritoneum through the gastrointestinal tract via mesenteric lymph nodes or directly from the blood, lymph, and fallopian tubes [2,5]. The risk is increased in patients with cirrhosis, HIV, diabetes mellitus, malignancy, following treatment with anti-tumor necrosis factor and peritoneal dialysis [6].

Tuberculous peritonitis is slightly more common in women than in men (1.4:1) and is commonly encountered in the third and fourth decades of life. The commonest presenting symptoms were abdominal swelling (73.1%), fever and night sweats (53.8%), anorexia (46.9%), weight loss (44.1%), and abdominal pain (35.9%) [7].

TB Peritonitis is difficult to diagnose, primarily due to its insidious onset and variability in radiographic findings. The CT findings in patients with tuberculosis peritonitis include ascites with the ascitic fluid demonstrating high attenua-



**Fig. 1 – Scrotal ultrasound showing heterogeneous right scrotal mass with anechoic center suggestive of necrotic component.**

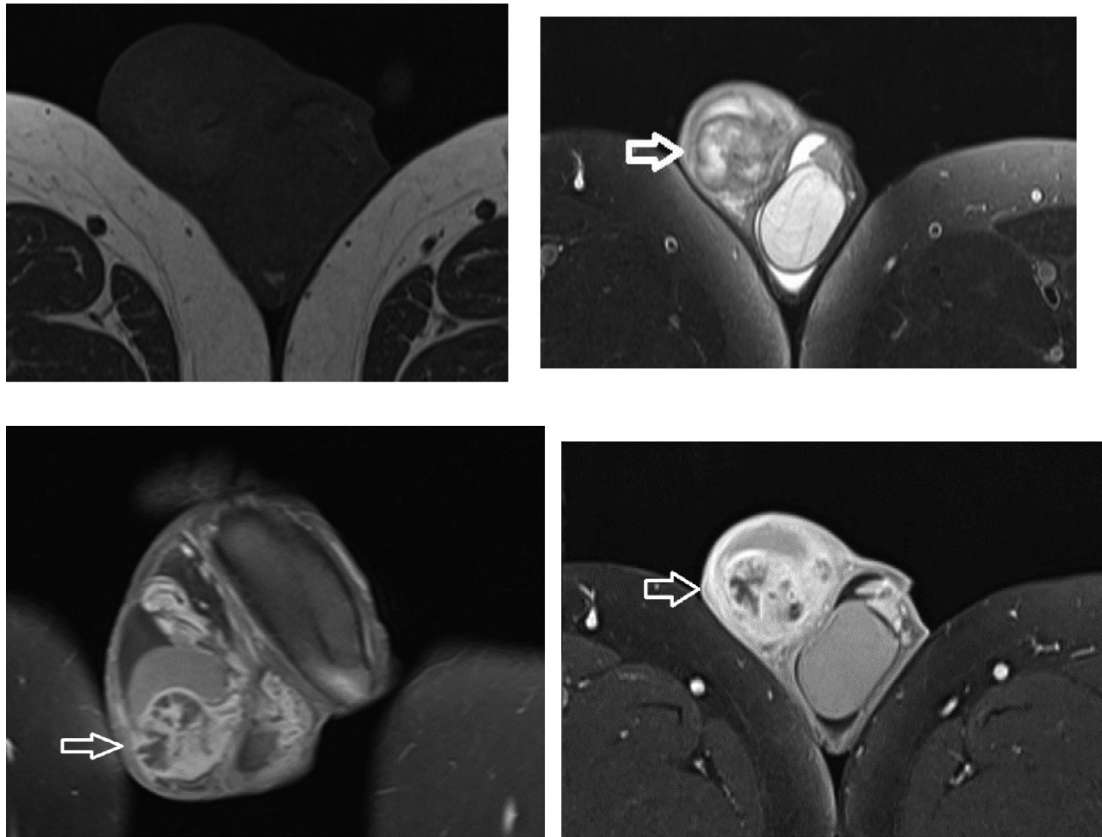
tion values on computerized tomographic (CT) imaging (20–45 HU), multiple, fine, delicate septations with congested vessels within the mesentery, thickened mesentery with mesenteric lymph nodes, matting of the bowel loops, omental masses, and peritoneal thickening and nodularity [8–10]. Hence, imaging features really overlap with peritoneal carcinomatosis (Figs. 1–3).

Peritoneal tuberculosis should be considered in the differential diagnosis of exudative ascites. The presence of lymphocytic ascites together with suggestive history should raise suspicion for TB peritonitis [5,10]. Microbiological or pathological confirmation remains the gold standard for diagnosis. An image-guided—either ultrasound or CT guided—percutaneous peritoneal biopsy is proven to be a sufficient, safe, and inexpensive method for the definitive diagnosis of peritoneal tuberculosis [1,11]. In uncomplicated cases of TB Peritonitis, treatment for 6 months with the first-line antituberculous drugs (isoniazid, rifampicin, ethambutol, and pyrazinamide) is usually sufficient [1].

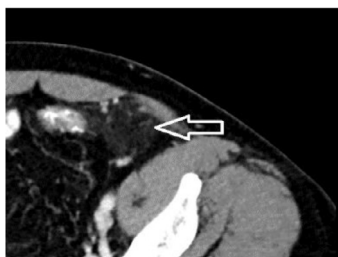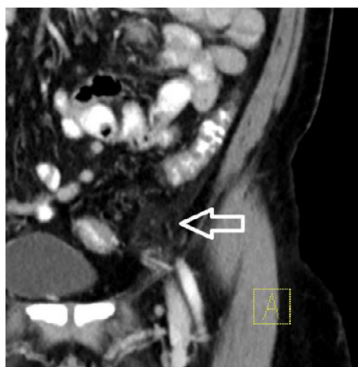On the other hand, Testicular tuberculosis is a rare form of genitourinary TB. It usually presents as painful or painless testicular swelling with or without scrotal ulceration or discharging sinus. In most cases, genital TB is associated with TB involvement of kidneys or lower urinary tract. Genital TB is uncommon, and testicular TB is exceptionally rare, comprising only 3% of genital TB [12].

TB of the gastrointestinal system presents with atypical manifestations. Only 20%–30% of patients with genitourinary TB have a history of respiratory infection. TB often affects the lower genitourinary system rather than the kidneys. The epididymis is the commonest organ to be involved, followed by the seminal vesicles, prostate, testis, and the vas deferens. Genital TB occurs through hematogenous spread to the epididymis and prostate or through the urinary system to the prostate and canalicular spread to the seminal vesicles, deferent ducts, and epididymis [13].

Testicular TB is a rare condition but should be kept in consideration when assessing focal abnormalities of the testes.



**Fig. 2 – (a) Axial T1 SE precontrast where the mass is intense to the remainder of the testis, (b) T2 FAT SAT MRI demonstrates the right scrotal cystic mass, (c) T1 FAT SAT postcontrast coronal, and (d) axial shows the marked predominantly peripheral enhancement.**



**Fig. 3 – CT abdomen shows nonspecific fat stranding.**

Ultrasound is the investigation of choice for diagnosis of testicular TB. Imaging features include: diffusely enlarged hypoechoic testis which could be homogenous or heterogeneous, nodular enlarged heterogeneous hypoechoic testis, and multiple small hypoechoic nodules (military pattern). Additional more specific imaging findings is the presence of smooth peripheral calcification of tunica vaginalis [14]. Sonographic evaluation is also helpful in determining the presence of complication like an abscess, or associated findings like hydrocele or skin thickening. Since the appearances on ultrasound are not specific, the differential considerations usually include other etiologies like; other infectious orchitis, sarcoidosis, lymphoma, infarction, and primary testicular malignancy. Fine needle aspiration cytology is critical to diagnostic accuracy, optimal treatment, and the possibility of avoiding surgery in those with testicular tuberculosis. As for MRI, normal testis appears hyperintense on T2-weighted images, and hypo to isointense on T1-weighted images, and it homogeneously enhances after contrast administration. In testicular tuberculosis, the lesion usually appears hypointense on T2 weight images due to fibrosis but can appear hyperintense in early orchitis stage [15]. Once genitourinary TB is diagnosed, antituberculosis chemotherapy is the first line therapy that includes rifampin, isoniazid, pyrazinamide, and ethambutol (RIPE) for an initial 2-month period followed by 4- to 7-month period of isoniazid and rifampin [16].

In our case, there was a delay in the diagnosis of testicular TB given the nonspecific symptoms, but TB peritonitis was suspected early and treated accordingly. Our case emphasizes that though both these entities are rare, high clinical index of suspicion and knowledge of the imaging features can lead to proper management and save the patient from complications and unnecessary surgery.

## Conclusion

TB peritonitis, despite being rare, is a serious condition. Careful clinical assessment helps early diagnosis and treatment, preventing complications. Similarly, testicular tuberculosis should be considered as a differential diagnosis in cases presenting with scrotal mass. Knowledge of the imaging features of those entities would significantly reduce any delays in the establishment of an accurate diagnosis and enhance the chances for a prompt management and recovery, thus avoiding unnecessary surgery.

## Patient consent

The patient was informed that data concerning the case would be submitted for publication, and he provided consent.

## REFERENCES

- [1] Vaid U, Kane GC. Tuberculous peritonitis. *Microbiol Spectr* 2017;5(1). doi:10.1128/microbiolspec.TNMI7-0006-2016.
- [2] Sharma MP, Bhatia V. Abdominal tuberculosis. *Indian J Med Res* 2004;120(4):305–15.
- [3] Dayal S, Kumar A, Singh SP, Verma A. Tuberculous orchitis mimicking a testicular tumor: a diagnostic dilemma. *Asian Pacific J Reprod* 2014;3(1):80–2. doi:10.1016/S2305-0500(14)60007-5.
- [4] Smith I. *Mycobacterium tuberculosis* pathogenesis and molecular determinants of virulence. *Clin Microbiol Rev* 2003;16(3):463–96. doi:10.1128/CMR.16.3.463-496.
- [5] Kaya M, Kaplan MA, Isikdogan A, Celik Y. Differentiation of tuberculous peritonitis from peritonitis carcinomatosa without surgical intervention. *Saudi J Gastroenterol* 2011;17(5):312–17. doi:10.4103/1319-3767.84484.
- [6] Lahbabi M, Brini J, Massaoudi K. Tuberculous peritonitis in pregnancy: a case report. *J Med Case Rep* 2014;8:3. doi:10.1186/1752-1947-8-3.
- [7] Manohar A, Simjee AE, Haffejee AA, Pettengell KE. Symptoms and investigative findings in 145 patients with tuberculous peritonitis diagnosed by peritoneoscopy and biopsy over a five year period. *Gut* 1990;31(10):1130–2. doi:10.1136/gut.31.10.1130.
- [8] Srivastava U, Almusa O, Tung KW, Heller MT. Tuberculous peritonitis. *Radiol Case Rep* 2015;9(3):971. doi:10.2484/rcr.v9i3.971.
- [9] Akhan O, Demirkazik FB, Demirkazik A, Gülekon N, Eryilmaz M, Unsal M, et al. Tuberculous peritonitis: ultrasonic diagnosis. *J Clin Ultrasound* 1990;18(9):711–14.
- [10] Sanai FM, Bzeizi KI. Systematic review: tuberculous peritonitis—presenting features, diagnostic strategies and treatment. *Aliment Pharmacol Ther* 2005;22(8):685–700. doi:10.1111/j.1365-2036.2005.02645.x.
- [11] Vardareli E, Kebapci M, Saricam T, Pasaoglu O, Açikalin M. Tuberculous peritonitis of the wet ascitic type: clinical features and diagnostic value of image-guided peritoneal biopsy. *Dig Liver Dis* 2004;36(3):199–204. doi:10.1016/j.dld.2003.10.016.
- [12] Das A, Batabyal S, Bhattacharjee S, Sengupta A. A rare case of isolated testicular tuberculosis and review of literature. *J Fam Med Prim Care* 2016;5(2):468–70. doi:10.4103/2249-4863.192334.
- [13] Yadav S, Singh P, Hemal A, Kumar R. Genital tuberculosis: current status of diagnosis and management. *Transl Androl Urol* 2017;6(2):222–33. doi:10.21037/tau.2016.12.04.
- [14] Nepal P, Ojili V, Songmen S, Kaur N, Olsavsky T, Nagar A. The great masquerader": sonographic pictorial review of testicular tuberculosis and its mimics. *J Clin Imaging Sci* 2019;9:27. doi:10.25259/JCIS-14-2019.
- [15] Naeem M, Zulfiqar M, Siddiqui MA, Shetty AS, Haq A, Varela C, et al. Imaging manifestations of genitourinary tuberculosis. *Radiographics* 2021;41(4):1123–43 Erratum in: *Radiographics*. 2022 Jul-Aug;42(4):E134. PMID: 34048278. doi:10.1148/rg.2021200154.
- [16] Abraham S, Izaguirre Anariba DE, Dua K, Mir M, Ankireddypalli A. A case of testicular tuberculosis mimicking malignancy in a healthy young man. *Ther Adv Infect Dis* 2016;3(3-4):110–13. doi:10.1177/2049936116655261.