

Recurrent hemarthrosis after total knee arthroplasty in rheumatoid arthritis successfully treated with selective embolization: A case report

SAGE Open Medical Case Reports
Volume 8: 1–4
© The Author(s) 2020
Article reuse guidelines:
sagepub.com/journals-permissions
DOI: 10.1177/2050313X20964116
journals.sagepub.com/home/sco



Takeo Mammoto¹ , Toshiyuki Irie², Nobuyuki Takahashi²,
Shun Nakajima¹ and Atsushi Hirano¹

Abstract

Recurrent hemarthrosis after total knee arthroplasty is a rare complication. This usually occurs in osteoarthritis, but is relatively rare in rheumatoid arthritis. This is a report of recurrent hemarthrosis after total knee arthroplasty in a rheumatoid arthritis patient. An 85-year-old woman with rheumatoid arthritis had received total knee arthroplasty without acute complications. At 6 months after surgery, the first hemarthrosis occurred and an initial conservative treatment failed. Contrast computed tomography showed prominent synovial enhancement in the superior lateral suprapatellar pouch. Selective catheterization revealed an abnormal hyperemic blush supplied from the branches of the superior lateral genicular artery. After embolization with N-butyl-2-cyanoacrylate, abnormal staining of the synovium diminished and knee swelling and pain disappeared without complications. Selective embolization is favorable for successful treatment of recurrent hemarthrosis after total knee arthroplasty in patients with rheumatoid arthritis.

Keywords

Recurrent hemarthrosis, knee arthroplasty, rheumatoid arthritis, embolization

Date received: 24 July 2020; accepted: 14 September 2020

Introduction

Recurrent hemarthrosis is a rare complication after total knee arthroplasty (TKA) with a prevalence of 0.3%–1.6%.^{1–4} This causes joint pain and stiffness, deteriorates joint function, and leads to poor patient satisfaction. If it occurs, early and adequate diagnosis is necessary, and urgent appropriate treatment is crucial.

In most cases, hemarthrosis after TKA has been reported in osteoarthritis (OA) patients. Worland and Jessup¹ reported that recurrent hemarthrosis occurred in 7 (0.5%) of 1400 OA patients after TKA. Yoo et al.³ reported recurrent hemarthrosis in 17 (0.3%) of 5510 OA patients after TKA. Other single cases and case series reported recurrent hemarthrosis after TKA in patients with OA.^{4–9}

There were only two reports of recurrent hemarthrosis after TKA in patients with rheumatoid arthritis (RA). Ohdera et al.² reported that recurrent hemarthrosis occurred in one (0.1%) of 625 RA patients after TKA. Kindsfater and Scott¹⁰ reported the largest case series of 30 recurrent hemarthroses after TKA. Only 16% of hemarthrosis after

TKA occurred in RA patients. In both reports, conservative and open or arthroscopic synovectomy treatment was performed, although arterial angiography and embolization were not performed.^{2,10}

Here, we report a case of recurrent hemarthrosis after TKA in an RA patient. Selective angiography was performed, and embolization was successfully used to treat recurrent hemarthrosis.

¹Department of Orthopaedic Surgery and Sports Medicine, Tsukuba University Hospital Mito Clinical Education and Training Center, Mito Kyodo General Hospital, University of Tsukuba, Mito, Japan

²Department of Radiology, Tsukuba University Hospital Mito Clinical Education and Training Center, Mito Kyodo General Hospital, University of Tsukuba, Mito, Japan

Corresponding Author:

Takeo Mammoto, Department of Orthopaedic Surgery and Sports Medicine, Tsukuba University Hospital Mito Clinical Education and Training Center, Mito Kyodo General Hospital, University of Tsukuba, 3-2-7 Miya-Machi, Mito, Ibaraki 310-0015, Japan.
Email: mammototakeo@mitokyodo-hp.jp



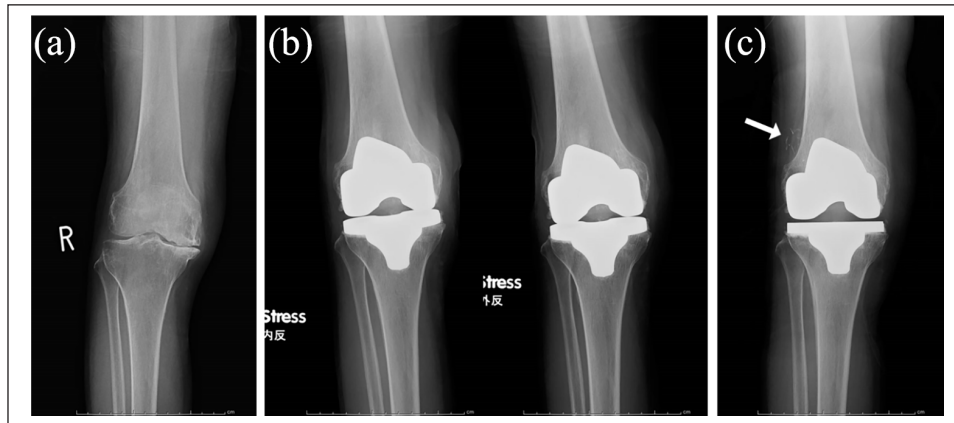


Figure 1. (a) Radiograph shows preoperative anteroposterior (AP) view of the right knee. (b) Radiographs at 6 months after surgery show no findings of instability, loosening, or osteolysis (right: varus stress AP view, left: valgus stress AP view). (c) Radiograph at 8 months after embolization shows Lipiodol in the superior lateral aspect (white arrow).

Case

An 85-year-old woman was referred to our institution with right knee pain (Figure 1(a)). She had RA for 4 years and was treated with infliximab and methotrexate. At surgery, a blood test showed normal white blood cells (WBC), normal IgG-rheumatoid factor (RF), positive anti-cyclic citrullinated peptide antibody (CCP), and negative C-reactive protein (CRP) levels. A cemented posterior stabilized TKA (Triathlon Systems; Stryker Orthopaedics, NJ, USA) was performed in her right knee. A pneumatic tourniquet was used in surgery, and careful hemostasis was confirmed. Oral thromboembolic prophylaxis (edoxaban, a direct inhibitor of activated factor X; Daiichi Sankyo, Tokyo, Japan) was administered to prevent thrombosis for 7 days after surgery. The patient was discharged on the 14th day after surgery. No abnormal bleedings and no acute complications were noted.

At 6 months post-surgery, pain and swelling occurred in the knee while she weeded her garden. The knee was swollen, with warmth and no redness. A blood test showed normal WBC with differential, negative CRP and normal erythrocyte sedimentation rate (ESR). There were no abnormalities in blood coagulation screening. No anticoagulation or antiplatelet medications were prescribed. Radiographs showed no signs of instability, loosening, or osteolysis (Figure 1(b)). Aspiration of the joint showed a 35-mL hemarthrosis. An arthrocentesis was performed showing gross blood. The fluid analysis showed 1381 white cells and 119 mg/dL of sugar, and cultures for bacteria and fungi were negative. During the next 4 weeks, hemarthrosis was confirmed by a total of three aspirations of 35, 40, and 30 mL. She was diagnosed with hemarthrosis following TKA.

Initially, conservative treatment involving rest, ice, and compression was performed, and oral tranexamic acid was prescribed. However, hemarthrosis recurred and aspiration was needed. As an advanced diagnostic test, contrast-enhanced computed tomography (CT) was performed. This

showed joint effusion and prominent synovial enhancement in the superior lateral suprapatellar pouch (Figure 2(a)).

Angiography revealed hyperemic blush in the superior lateral aspect of the knee (Figure 2(b)). Selective catheterization revealed a source of abnormal hyperemic blush supplied from branches of the superior lateral genicular artery (Figure 2(c)). Then, branches from the superior lateral genicular artery were selectively cannulated and embolized with a suspension of N-butyl-2-cyanoacrylate (NBCA) and Lipiodol. After embolization, abnormal staining of the synovium was diminished (Figure 2(d)). At 1 week post-embolization, knee swelling and pain disappeared without any complications. No recurrence was observed 8 months after embolization (Figure 1(c)).

Discussion

The importance of this report was that recurrent hemarthrosis after TKA in RA patients was relatively rare, and selective arterial embolization could be one approach that has utility in the management of these patients.

The pathogenesis of hemarthrosis after TKA is not fully understood. Some possible explanations of the pathogenesis of hemarthrosis involve intraoperative vascular injury, leading to genicular pseudoaneurysms and arteriovenous fistulas.^{1,2,5,9,11} Generally, most cases of hemarthrosis occur without any history of trauma. Recently, hypertrophic vascular synovium has been described as a cause of hemarthrosis.^{1,4,5,10} Although the etiology of hypervascularity and proliferation of synovium has not been clearly elucidated, stimulation of production and activation of inflammatory mediators in the joint result in the occurrence of synovitis and proliferation of blood vessels in the synovium.^{3,8}

RA is characterized by synovial inflammation and hyperplasia.¹² In the synovial tissues, endothelial activation occurs in synovial microvessels, leading to synovitis and an increase in blood vessels.¹² RA after total joint replacement might

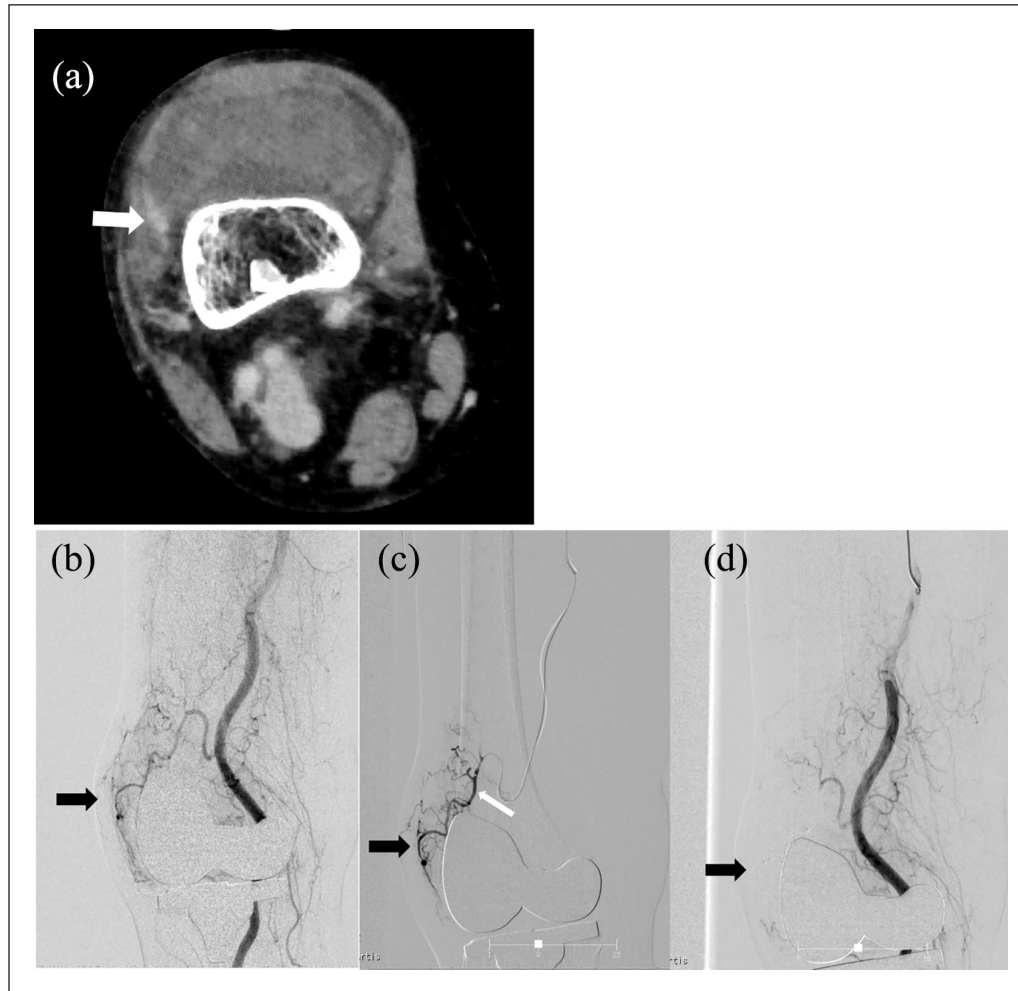


Figure 2. (a) A contrast-enhanced computed tomography (CT) shows joint effusion and prominent synovial enhancement (white arrow), and suspected hyperemic synovium in superior lateral suprapatellar pouch. (b) A digital subtraction angiography shows hyperemic blush in the superior lateral aspect of the knee (black arrow). (c) Selective catheterization reveals abnormal hyperemic blush supplied from branches of the superior lateral genicular artery (white arrow). (d) After embolizing selectively with a suspension of N-butyl-2-cyanoacrylate (NBCA) and Lipiodol, subtotal devascularization of branches from superior lateral genicular artery is observed.

cause synovial tissue inflammation with microvascular hyperplasia. However, it seems that preoperative diagnosis has not been emphasized as the cause of hemarthrosis. Although detailed studies should be required in the future, we believe that this report highlights the importance of preoperative diagnosis and might be useful for elucidating the etiology.

The standard treatment protocol for recurrent hemarthrosis remains unclear. The usual cases could be treated conservatively with a high success rate.^{2,3,5,10} When hemarthrosis is unresolved conservatively, contrast-enhanced CT, magnetic resonance imaging (MRI) angiography, and Doppler ultrasound could identify vascular anatomy and active bleeding, being less invasive than angiography.^{11,13} In this case, contrast-enhanced CT was performed, suggesting hypervascularity of the synovium in the superior lateral suprapatellar pouch, and then interventional angiography was performed for diagnosis and treatment.

Previously, recurrent hemarthrosis in RA was treated by open or arthroscopic synovectomy.^{2,10} Selective arterial angiography is reportedly a useful tool for diagnosis and treatment of unexplained hemarthrosis, and high success rates of embolization are reported in OA patients.^{1,3-5,7-9} In this case, selective angiography demonstrated hypervascularity of the synovium, and embolization successfully treated hemarthrosis. Various sources of bleeding, including the superior or inferior, lateral or medial geniculate artery branches and other areas, are possible; therefore, thorough examination should be performed.^{3,9,13} In addition, hemorrhage occurs intermittently and acutely, and appropriate timing for angiographic therapy might be crucial for the successful treatment of hemarthrosis.³ If embolization is unsuccessful, repeat attempts should be considered, with careful detection of bleeding sources.^{3,5} In case of failure of embolization, surgical treatment could be performed arthroscopically at first in order to be less invasive compared to open surgery.^{2,3,10}

Conclusion

Recurrent hemarthrosis after TKA in patients with RA is relatively rare. RA might have a potential risk of developing hemarthrosis; however, there have been no reports that hematomas frequently occur in RA. Further detailed studies should be considered necessary. If conservative treatment fails, angiography should be considered. Selective embolization might have utility for treatment of recurrent hemarthrosis after TKA in RA patients.

Declaration of conflicting interests

The author(s) declared no potential conflicts of interest with respect to the research, authorship, and/or publication of this article.

Funding

The author(s) received no financial support for the research, authorship, and/or publication of this article.

Ethical approval

Ethical approval to report this case was obtained from Tsukuba University Hospital Mito Clinical Education and Training Center, Mitokyo General Hospital (Approval Number 20-13).

Informed consent

Written informed consent was obtained from the patient for their anonymized information to be published in this article.

ORCID iD

Takeo Mammoto  <https://orcid.org/0000-0002-9055-0756>

References

1. Worland RL and Jessup DE. Recurrent hemarthrosis after total knee arthroplasty. *J Arthroplasty* 1996; 11: 977–978.
2. Ohdera T, Tokunaga M, Hiroshima S, et al. Recurrent hemarthrosis after knee joint arthroplasty: etiology and treatment. *J Arthroplasty* 2004; 19(2): 157–161.
3. Yoo JH, Oh HC, Park SH, et al. Treatment of recurrent hemarthrosis after total knee arthroplasty. *Knee Surg Relat Res* 2018; 30: 147–152.
4. Oishi CS, Elliott ML, Colwell CW, et al. Recurrent hemarthrosis following a total knee arthroplasty. *J Arthroplasty* 1995; 10(Suppl): S56–58.
5. Dhondt E, Vanhoenacker FM, D'Archambeau O, et al. Angiographic findings and therapeutic embolization of late hemarthrosis after total joint arthroplasty. *Skeletal Radiol* 2009; 38(1): 31–36.
6. Fine S and Klestov A. Recurrent hemarthroses after TKA treated with an intraarticular injection of yttrium-90. *Clin Orthop Relat Res* 2016; 474(3): 850–853.
7. Katsimihis M, Robinson D, Thornton M, et al. Therapeutic embolization of the genicular arteries for recurrent hemarthrosis after total knee arthroplasty. *J Arthroplasty* 2001; 16(7): 935–937.
8. Pritsch T, Pritsch M and Halperin N. Therapeutic embolization for late hemarthrosis after total knee arthroplasty. *J Bone Joint Surg Am* 2003; 85(9): 1802–1804.
9. Ibrahim M, Booth RE Jr and Clark TW. Embolization of traumatic pseudoaneurysms after total knee arthroplasty. *J Arthroplasty* 2004; 19: 123–128.
10. Kindsfater K and Scott R. Recurrent hemarthrosis after total knee arthroplasty. *J Arthroplasty* 1995; 10(Suppl): S52–15.
11. Hash TW 2nd, Maderazo AB, Haas SB, et al. Magnetic resonance angiography in the management of recurrent hemarthrosis after total knee arthroplasty. *J Arthroplasty* 2011; 26(8): 1357–1361.
12. McInnes IB and Schett G. The pathogenesis of rheumatoid arthritis. *N Engl J Med* 2011; 365: 2205–2219.
13. Weidner ZD, Hamilton WG, Smirniotopoulos J, et al. Recurrent hemarthrosis following knee arthroplasty treated with arterial embolization. *J Arthroplasty* 2015; 30: 2004–2007.