



# Isometric Anterolateral Ligament Reconstruction Using the Semitendinosus Tendon With Suspensory Tibial Fixation

Man Soo Kim, M.D., In Jun Koh, M.D., Ph.D., and Yong In, M.D., Ph.D.

**Abstract:** The anterolateral ligament (ALL) plays an important role in isolated anterior cruciate ligament reconstruction by providing rotational stability in a combined anterior cruciate ligament and anterolaterally injured knee. Although the ALL has been difficult to characterize anatomically, it originates near the lateral epicondyle of the distal femur and inserts into the proximal tibia between Gerdy's tubercle and the fibula head. Here, we describe an isometric ALL reconstruction using the semitendinosus tendon and an adjustable length loop suspensory tibial fixation. With this technique, it is possible to provide good stability and satisfactory results for patients with rotational instability of the knee.

## Introduction (With Video Illustration)

Surgical treatments due to anterior cruciate ligament (ACL) rupture are common in the orthopaedic field.<sup>1</sup> Various studies have reported that the results of ACL reconstruction are satisfactory and stable.<sup>2</sup> However, despite undergoing this procedure, many ACL-reconstructed knees demonstrate persistent instability and positive pivot shifts.<sup>3</sup> There are a variety of causes, but recent attention has focused on concomitant injury of the anterolateral ligament (ALL) of the knee.<sup>4,5</sup>

The ALL is important in restraining internal tibial rotation<sup>4,6</sup> and also can improve the results of isolated ACL reconstruction by providing rotational stability.<sup>4,6</sup> A systematic review reported a significant decrease in the proportion of pivot shifts in all cases of ACL and

ALL reconstruction in patients with ACL rupture with a high grade of pivot shift.<sup>7</sup>

Various surgical methods have been reported for anterolateral structure reconstruction. Although extra-articular tenodesis procedures have historically been used and subsequently abandoned,<sup>8</sup> other techniques, such as the modified Lemaire procedure, remain in use.<sup>9</sup> Recent techniques for ALL reconstruction have been introduced and have produced good clinical results.<sup>10</sup> These methods have shown that anatomical ALL reconstruction is not isometric, and the length of the graft varies with the individual knee's optimal range of motion (ROM).<sup>11</sup> The anatomy of the ALL has not been clearly characterized. It originates near the lateral epicondyle of the distal femur and inserts into the proximal tibia between Gerdy's tubercle and the fibula head.<sup>6</sup> Although no clear consensus has yet been established,<sup>10</sup> a minimal length change in the ALL graft without excessive tightening or slackening during ROM is desirable. In this technical note, we describe our technique for isometric ALL reconstruction using the semitendinosus tendon and an adjustable length loop suspensory cortical fixation device for tibial fixation and describe the clinical results (Video 1).

## ALL Reconstruction Technique

The patient is placed supine on the operating table with an appropriate tourniquet applied over the cast padding. Routine arthroscopic examination is performed first using the anteromedial, anterolateral, and superomedial portals. ACL reconstruction is first performed for ACL rupture or a re-rupture state. The

*From the Department of Orthopaedic Surgery, Seoul St. Mary's Hospital, College of Medicine, The Catholic University of Korea (M.S.K., Y.I.); and Department of Orthopaedic Surgery, Eunpyeong St. Mary's Hospital, College of Medicine, The Catholic University of Korea (I.J.K.), Seoul, Republic of Korea.*

*The authors report that they have no conflicts of interest in the authorship and publication of this article. Full ICMJE author disclosure forms are available for this article online, as [supplementary material](#).*

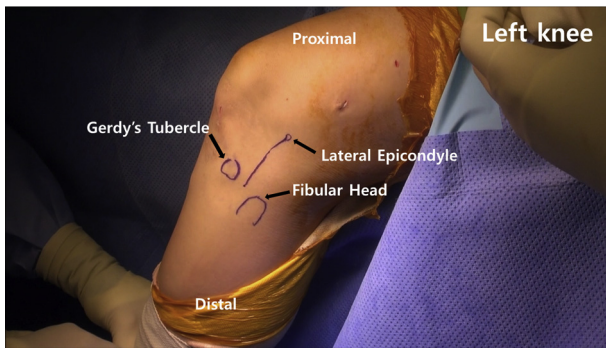
*Received January 15, 2020; accepted March 14, 2020.*

*Address correspondence to Yong In, M.D., Department of Orthopaedic Surgery, Seoul St. Mary's Hospital, College of Medicine, The Catholic University of Korea, 222 Banpo-Daero, Seocho-Gu, Seoul, 06591, Korea. E-mail: [iy1000@catholic.ac.kr](mailto:iy1000@catholic.ac.kr)*

*© 2020 by the Arthroscopy Association of North America. Published by Elsevier. This is an open access article under the CC BY-NC-ND license (<http://creativecommons.org/licenses/by-nc-nd/4.0/>).*

*2212-6287/20102*

*<https://doi.org/10.1016/j.eats.2020.03.017>*

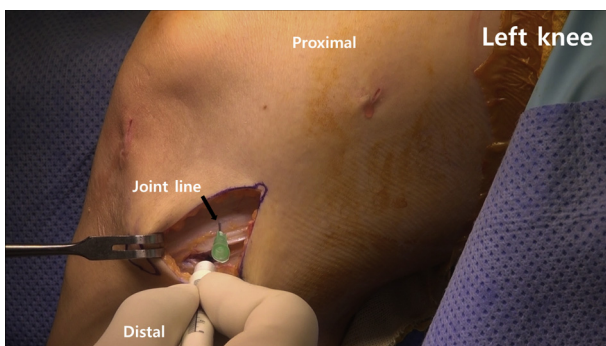


**Fig 1.** The left knee is shown. The anatomic landmarks are drawn: the fibular head, Gerdy's tubercle, and the lateral femoral epicondyle. A skin incision is made from the lateral femoral epicondyle and extended distally between Gerdy's tubercle and the fibular head.

semitendinosus tendon is harvested from the contralateral side because the semitendinosus tendon of the operated knee has already been used for ACL reconstruction or a previous hamstring ACL reconstruction. The end of the graft is sutured with whipstitch using a nonabsorbable, no. 5 ETHIBOND suture (Ethicon, Somerville, NJ). After passing the graft through an adjustable length loop button (TightRope RT, Arthrex, Naples, FL), it is folded symmetrically over the loops.

The anatomic landmarks are as follows: the fibular head, Gerdy's tubercle, and the lateral femoral epicondyle. A 4-cm oblique skin incision is made from the lateral femoral epicondyle and extended distally between Gerdy's tubercle and the fibular head (Fig 1). Sharp dissection is performed down to the fascia overlying the iliotibial band (ITB). The joint line is indicated with a needle. The tibial attachment site of the ALL is marked with a ruler, and it is approximately midway between Gerdy's tubercle and the fibular head 6 (Fig 2).

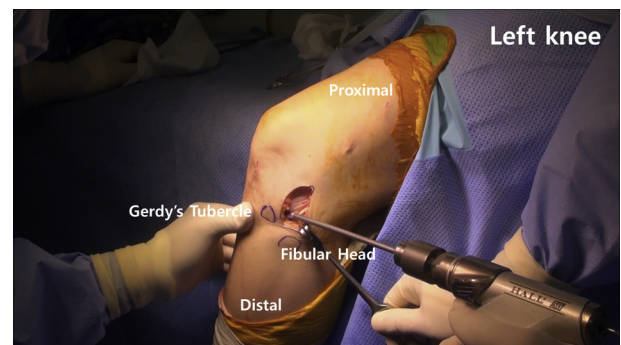
Next, a spade-tipped drill bit (Arthrex) is inserted into the tibial attachment site of the ALL. This location should also be the approximate midpoint between



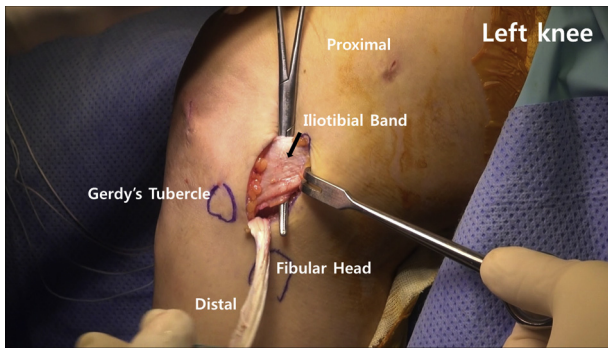
**Fig 2.** The left knee is shown. The joint line is marked with a needle. The distal attachment site of the anterolateral ligament is marked with a ruler and is approximately midway between Gerdy's tubercle and the fibular head.

Gerdy's tubercle and the center of the fibular head. The aiming point of the drill bit is slightly anterior to the ACL tibial tunnel aperture of the medial tibial surface (Fig 3). Overdrilling with a reamer (Arthrex) of an appropriate diameter is performed with a tunnel depth of 25 mm. A nonabsorbable suture (no. 5 ETHIBOND; Ethicon) is passed to the far cortex. The blue passing suture and white tensioning strands are retrieved through the tibia. We take care to ensure that the button of the suspensory device is located outside of the far cortex of the tibia. The position of the adjustable suspensory device is confirmed, and the graft is fixed distally on the tibia by pulling the tensioning strands.

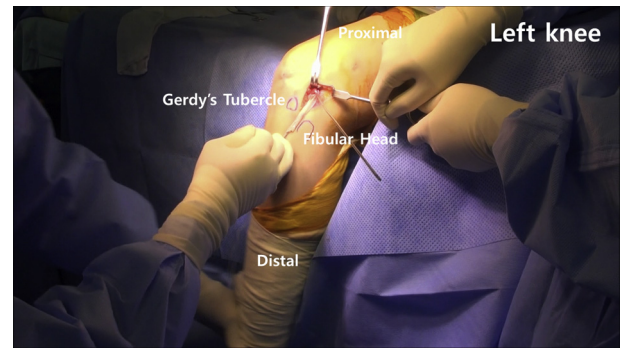
The ITB around the lateral femoral epicondyle is dissected along the course of its fibers to locate the femoral attachment area. Blunt dissection is performed to create the path for the ALL graft beneath the ITB. Both strands of the graft are passed underneath the ITB by pulling the sutures from the femoral side (Fig 4). The femoral tunnel guide pin (Arthrex) is inserted near the lateral femoral epicondyle in a slightly proximal and posterior location. The direction of the guide pin is slightly anterior and proximal to the perpendicular direction to avoid drilling into the femoral socket of the ACL reconstruction (Fig 5). The graft is folded over the guide pin, and the isometric point of the graft is tested through the full ROM (Fig 6). When a discrepancy of more than 2 mm is detected between the length of the grafts during flexion and extension of the knee, adjustments of the isometric point are essential. Lengthening of the graft during extension means that the graft is tight in extension. Therefore, the femoral guide pin should be moved anteriorly to an isometric point. Both ends of the graft are marked 2 cm proximal to the isometric point and then whipstitched with a no. 5 ETHIBOND suture. The proximal ends are cut with a knife (Fig 7). A femoral tunnel with a depth of 30 mm and the same diameter as the tibial tunnel is created over this guide pin. The sutures (no. 5 ETHIBOND suture) are passed with the guide pin through the femoral



**Fig 3.** The left knee is shown. The aiming point of the tibial guide is slightly anterior to the anterior cruciate ligament tibial tunnel aperture of the medial tibial surface.



**Fig 4.** The left knee is shown. Blunt dissection is performed to create a path underneath the iliotibial band. A passing device is placed from proximal to distal, and the graft is passed to the femoral side.



**Fig 6.** The left knee is shown. The isometric point of the graft is tested throughout the range of motion. When differences in length of the grafts during flexion and extension of the knee are detected, adjustments of the isometric point are essential.

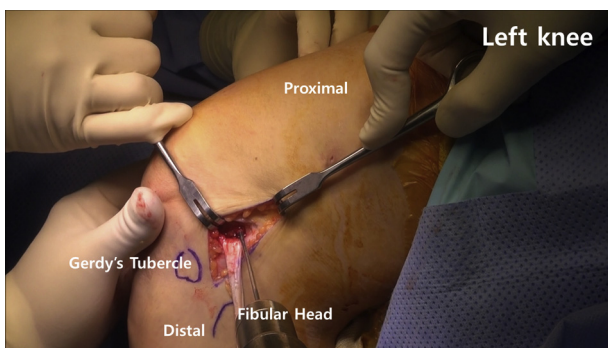
condyle from the lateral to the medial side, and the graft is inserted into the femoral tunnel. The inserted graft is then fixed in the femoral tunnel with a bio-absorbable interference screw (BioComposite screw; Arthrex). The fixation is performed with 30° of knee flexion and neutral rotation of the foot (Fig 8). After the operation, full ROM of the knee is confirmed. Stability also is confirmed with a negative Lachman test and a pivot shift test (Fig 9).

After the operation, a hinged brace is applied for the first postoperative 6 weeks. The patient is allowed partial weight bearing with crutches following the procedure. ROM exercises are started and gradually increased to 90° until 2 weeks postoperatively. After 2 weeks, patients are allowed to walk without crutches and proceed with active ROM. A return to sports activities should not occur until 6 months after surgery.

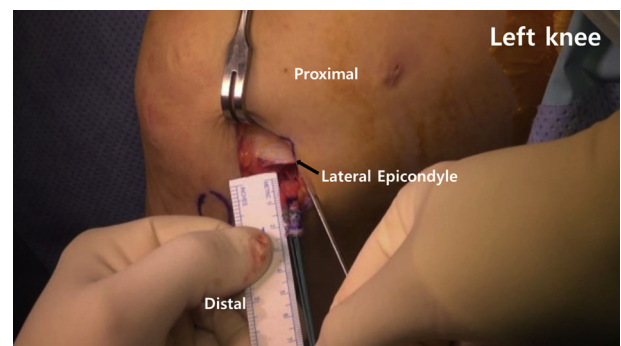
## Discussion

Since surgeons aim to provide consistent restoration of function, including rotational control, there is a

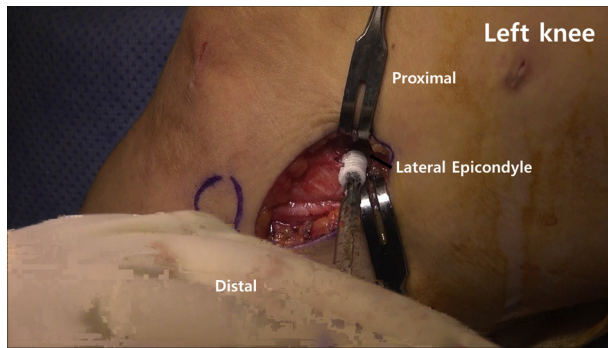
growing interest in combining extra-articular reconstruction techniques with ACL reconstruction.<sup>10</sup> Although the existence, anatomy, and role of the ALL of the knee are still a matter of controversy, the importance of the anterolateral structure for rotational stability in patients undergoing ACL reconstruction has been highlighted.<sup>12</sup> Currently used extra-articular augmentation techniques include lateral extra-articular tenodesis or ALL reconstruction.<sup>8,10</sup> There are 2 recent debates regarding the ALL reconstruction technique. The first debate concerns the femoral fixation site of the ALL graft. Although greater consensus appears to exist with regard to the tibial attachment site, the femoral attachment site has been the subject of much debate in the literature.<sup>13</sup> Some authors found the insertion to be proximal and posterior to the origin of the lateral collateral ligament (LCL),<sup>14,15</sup> whereas others reported it to be anterior and distal to the origin of the LCL.<sup>16</sup> The second debate is the overconstraint issue of the graft. Although the ALL is not an isometric ligament, which means that the length of the ligament increases during knee flexion, surgical reconstruction of the ALL cannot reproduce the length changes of the



**Fig 5.** The left knee is shown. The anterolateral ligament femoral attachment is located slightly proximal and posterior to the lateral epicondyle. The femoral guide pin is inserted slightly anteriorly and proximally to avoid drilling into the femoral socket of the anterior cruciate ligament reconstruction.



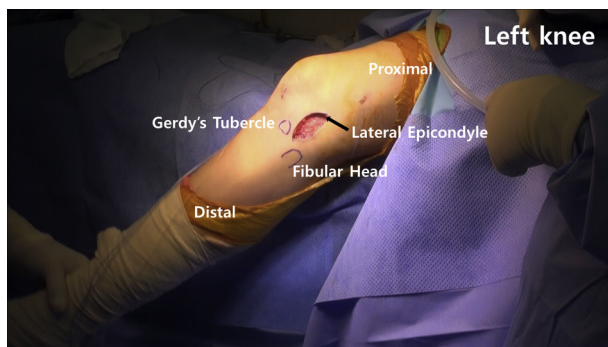
**Fig 7.** The left knee is shown. Both ends of the graft are marked 2 cm proximal to the isometric point and then whipstitched with non-absorbable suture. The proximal ends are cut with a knife.



**Fig 8.** The left knee is shown. The inserted graft is fixed in the femoral tunnel with a bioabsorbable interference screw. The fixation is performed with 30° of knee flexion and neutral rotation of the foot.

native ALL.<sup>6,17</sup> In addition, there has been no consensus regarding the optimum knee flexion angle of fixation.<sup>14,18,19</sup> In our technique, an isometric point that allowed a 2-mm length change during ROM could be found and was suggested. Femoral attachment was fixed at 30° of knee flexion and neutral rotation of the foot. The ALL graft was not excessively tightened or slackened during ROM.

There are several surgical approaches for ALL reconstruction. The various differences in these surgical methods are largely determined by the difference in femoral insertion site of the ALL.<sup>8,10</sup> As mentioned previously, the femoral insertion site of the ALL in anatomical reconstruction is divided into anterior and distal<sup>19</sup> or posterior and proximal<sup>14,15,18</sup> to the lateral epicondyle. However, previous studies have shown that an anatomical ALL reconstruction is not isometric, and the length of the graft varies with the individual knee's ROM.<sup>10,11</sup> In addition, the proximal and posterior point to the lateral epicondyle showed significantly smaller changes in graft length and graft tension during knee ROM than the distal and anterior points.<sup>10,11</sup> Therefore, our technique determined the femoral insertion site both proximally and posteriorly to the lateral



**Fig 9.** The left knee is shown. The reconstructed graft is identified once again. The stability is assessed through the complete range of motion.

**Table 1.** Pearls and Pitfalls

1. It is important to identify the correct femoral and tibial graft attachment sites to maintain ideal graft-tensioning properties.
2. The ALL graft should be passed superficially to the LCL and deep to the ITB.
3. The femoral tunnel should be positioned anteriorly and proximally to prevent injury to the ACL tunnel.
4. It is important not to injure the LCL when performing dissection beneath the ITB.
5. Applying a figure-of-four position to the knee will help identify the LCL.

ACL, anterior cruciate ligament; ALL, anterolateral ligament; ITB, iliotibial band; LCL, lateral collateral ligament.

epicondyle and also attempted to find the maximum isometric point while maintaining ROM to adjust the femoral insertion site.

There are several pearls and pitfalls to our technique. It is important to identify the correct femoral and tibial graft insertion locations to maintain ideal graft-tensioning properties. The ALL graft was passed superficial to the LCL and deep to the ITB. The femoral tunnel was positioned anteriorly and proximally to the ACL tunnel to prevent injury to the ACL graft. It is necessary not to injure the LCL during the dissection beneath the ITB. Applying a figure-of-four position to the knee helped us to identify the LCL (Table 1).

This technique also has advantages and disadvantages. Fixation can be performed more easily and simply through tibial fixation using a suspensory fixation device with an adjustable loop. In general, in cases of ALL reconstruction or lateral extra-articular tenodesis, knee lateral structures, including the LCL and ITB, may be damaged. With our technique, the ITB is preserved, and LCL injury can be avoided. A recent study by Wieser et al.<sup>20</sup> offered perhaps the most accurate radiographic landmarks for the femoral tunnel position using 3-dimensional weight-bearing computed tomography simulation. However, we were able to locate the isometric footprint of the ALL simply using palpation and checking the graft excursion during ROM. It is necessary to have the ability to palpate anatomic landmarks such as the lateral epicondyle.

Our technique of isometric reconstruction of the ALL concomitantly using an autogenous hamstring tendon with an adjustable loop length suspensory fixation device provided good stability and satisfactory results for anterolateral rotational instability of the knee using a constant isometric graft during ROM without overconstraint.

## References

1. Chambat P, Guier C, Sonnery-Cottet B, Fayard JM, Thaumat M. The evolution of ACL reconstruction over the last fifty years. *Int Orthop* 2013;37:181-186.
2. Chen Y, Chua KH, Singh A, et al. Outcome of single-bundle hamstring anterior cruciate ligament

- reconstruction using the anteromedial versus the trans-tibial technique: A systematic review and meta-analysis. *Arthroscopy* 2015;31:1784-1794.
3. van Eck CF, Schkrohowsky JG, Working ZM, Irrgang JJ, Fu FH. Prospective analysis of failure rate and predictors of failure after anatomic anterior cruciate ligament reconstruction with allograft. *Am J Sports Med* 2012;40:800-807.
  4. Ahn JH, Patel NA, Lin CC, Lee TQ. The anterolateral ligament of the knee joint: A review of the anatomy, biomechanics, and anterolateral ligament surgery. *Knee Surg Rel Res* 2019;31:12.
  5. Helito CP, Demange MK, Bonadio MB, et al. Anatomy and histology of the knee anterolateral ligament. *Orthop J Sports Med* 2013;1:2325967113513546.
  6. Kennedy MI, Claes S, Fuso FA, et al. The anterolateral ligament: An anatomic, radiographic, and biomechanical analysis. *Am J Sports Med* 2015;43:1606-1615.
  7. Piefer JW, Pflugner TR, Hwang MD, Lubowitz JH. Anterior cruciate ligament femoral footprint anatomy: Systematic review of the 21st century literature. *Arthroscopy* 2012;28:872-881.
  8. Slette EL, Mikula JD, Schon JM, et al. Biomechanical results of lateral extra-articular tenodesis procedures of the knee: A systematic review. *Arthroscopy* 2016;32:2592-2611.
  9. Williams A, Ball S, Stephen J, White N, Jones M, Amis A. The scientific rationale for lateral tenodesis augmentation of intra-articular ACL reconstruction using a modified 'Lemaire' procedure. *Knee Surg Sports Traumatol Arthrosc* 2017;25:1339-1344.
  10. DePhillipo NN, Cinque ME, Chahla J, Geeslin AG, LaPrade RF. Anterolateral ligament reconstruction techniques, biomechanics, and clinical outcomes: A systematic review. *Arthroscopy* 2017;33:1575-1583.
  11. Van de Velde SK, Kernkamp WA, Hosseini A, LaPrade RF, van Arkel ER, Li G. In vivo length changes of the anterolateral ligament and related extra-articular reconstructions. *Am J Sports Med* 2016;44:2557-2562.
  12. Zaffagnini S, Grassi A, Marcheggiani Muccioli GM, et al. The anterolateral ligament does exist: An anatomic description. *Clin Sports Med* 2018;37:9-19.
  13. Kraeutler MJ, Welton KL, Chahla J, LaPrade RF, McCarty EC. Current concepts of the anterolateral ligament of the knee: Anatomy, biomechanics, and reconstruction. *Am J Sports Med* 2018;46:1235-1242.
  14. Chahla J, Menge TJ, Mitchell JJ, Dean CS, LaPrade RF. Anterolateral ligament reconstruction technique: An anatomic-based approach. *Arthrosc Tech* 2016;5:e453-e457.
  15. Sonnery-Cottet B, Barbosa NC, Tuteja S, Daggett M, Kajetanek C, Thauinat M. Minimally invasive anterolateral ligament reconstruction in the setting of anterior cruciate ligament injury. *Arthrosc Tech* 2016;5:e211-e215.
  16. Wagih AM, Elguindy AM. Percutaneous reconstruction of the anterolateral ligament of the knee with a polyester tape. *Arthrosc Tech* 2016;5:e691-e697.
  17. Helito CP, Helito PV, Bonadio MB, et al. Evaluation of the length and isometric pattern of the anterolateral ligament with serial computer tomography. *Orthop J Sports Med* 2014;2:2325967114562205.
  18. Helito CP, Saithna A, Bonadio MB, et al. Anterolateral ligament reconstruction: A possible option in the therapeutic arsenal for persistent rotatory instability after ACL reconstruction. *Orthop J Sports Med* 2018;6:2325967117751348.
  19. Sonnery-Cottet B, Daggett M, Fayard JM, et al. Anterolateral Ligament Expert Group consensus paper on the management of internal rotation and instability of the anterior cruciate ligament-deficient knee. *J Orthop Traumatol* 2017;18:91-106.
  20. Wieser K, Furnstahl P, Carrillo F, Fucntese SF, Vlachopoulos L. Assessment of the isometry of the anterolateral ligament in a 3-dimensional weight-bearing computed tomography simulation. *Arthroscopy* 2017;33:1016-1023.