JOURNAL OF NEUROSURGERY:
Case Lessons

J Neurosurg Case Lessons 3(4): CASE21630, 2022
DOI: 10.3171/CASE21630

Ten-year survival in glioblastoma patient with neurofibromatosis type 1: illustrative case

Sarah Basindwah, MD,[1] Hisham Alkhalidi, FRCPath,[2] Ahmed Abdelwarith, MD,[3] and Sherif Elwatidy, PhD, FRCS(SN)[1]

[1]Department of Surgery, Division of Neurosurgery, [2]Department of Pathology, and [3]Department of Oncology, College of Medicine, King Saud University, Riyadh, Saudi Arabia

BACKGROUND Gliomas are commonly detected in patients with neurofibromatosis type 1 (NF1) at an early age. Few patients with NF1 are diagnosed with glioblastoma. The course of management, response to therapy, and prognosis of such patients are unknown. Few reports have shown longer-than-average survival rates for patients with NF1 with glioblastoma.

OBSERVATIONS A 27-year-old man with NF1 presented with symptoms of high intracranial pressure. Imaging and pathology showed left frontotemporal glioblastoma. Gross total resection was achieved, and concurrent chemoradiotherapy was administered. Recurrence of tumor was detected 48 months later, and the patient underwent tumor debulking and concurrent chemoradiotherapy. The patient received first-, second-, and third-line chemotherapy (temozolomide, bevacizumab, bevacizumab/irinotecan) with good tolerance and has survived >10 years since then with good functional status.

LESSONS This case demonstrates >10 years overall survival of glioblastoma in a patient with NF1. Reports of patients with NF1 with longer survival may be attributed to the young age at diagnosis and relatively better tolerance for therapy. It might also support the growing evidence of a unique subset of glioblastoma associated with NF1 and opens the door for a more molecular targeted therapy in the future.

https://thejns.org/doi/abs/10.3171/CASE21630

KEYWORDS glioblastoma survival; neurofibromatosis type 1 glioma; long-term survival; IDH wild-type glioma

Neurofibromatosis type 1 (NF1) is an autosomal dominant tumor predisposition syndrome. Patients with NF1 are diagnosed clinically and radiologically with pathognomonic cutaneous and neural axis tumors.[1] Gliomas are commonly detected early in life and are usually low-grade tumors.[2] Although patients with NF1 are at a higher risk of glioblastoma than the general population, they are relatively uncommon compared with low-grade gliomas in patients with NF1.[3] The epidemiology, pathogenesis, prognosis, and survival of such patients are poorly understood. There are few reports on gliomas that are more aggressive than predicted in patients with NF1,[4] whereas other reports have shown prolonged glioblastoma survival in the same population,[5] with the longest reported overall survival being 104.4 months (8.7 years).[5] In pediatric patients with NF1, although they are at a higher risk of developing glioblastoma, they have a better prognosis than their non-NF1 peers.[6] This might indicate a different genetic landscape of glioblastoma in patients with NF1 and perhaps the need for different or combined therapy in this population.

In this case report, we present a case of 10-year overall survival in a patient with glioblastoma with NF1 along with the disease course, and we review the literature on similar reported cases and their overall survival.

Illustrative Case

A 27-year-old man with a known case of NF1 diagnosed after meeting the clinical diagnostic criteria presented in 2010 with acute onset of severe headache, confusion, and bilateral high-grade papilledema. His physical examination revealed multiple café-au-lait spots on the trunk. Computed tomography (CT) showed a large heterogeneous mass lesion in the left frontotemporal region measuring approximately 6.4 × 4.3 cm associated with extensive surrounding

ABBREVIATIONS CCRT = concurrent chemoradiotherapy; CNS = central nervous system; CT = computed tomography; IDH-1 = isocitrate dehydrogenase 1; MEK = mitogen-activated protein kinase kinase; MRI = magnetic resonance imaging; NF1 = neurofibromatosis type 1; WHO = World Health Organization.

INCLUDE WHEN CITING Published January 24, 2022; DOI: 10.3171/CASE21630.
SUBMITTED November 3, 2021. **ACCEPTED** December 6, 2021.
© 2022 The authors, CC BY-NC-ND 4.0 (http://creativecommons.org/licenses/by-nc-nd/4.0/).

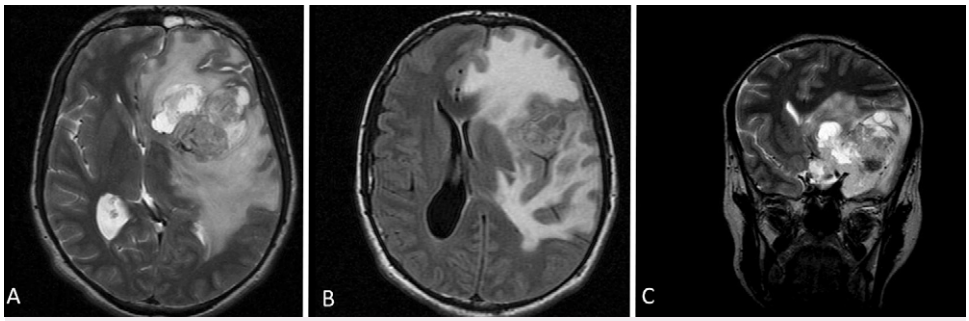

FIG. 1. A–C: Axial T2, axial fluid-attenuated inversion recovery, and coronal T2-weighted images showing a left frontotemporal mass with heterogeneous enhancement measuring 6 × 6 × 3 cm with significant surrounding edema and 1.6-cm midline shift and uncal herniation.

vasogenic edema and causing mass effect in the form of effacement of the adjacent cortical sulci and approximately 1.6 cm midline shift to the right side. Magnetic resonance imaging (MRI) showed a left frontotemporal large mass measuring 6 × 3 × 6 cm, with internal areas of cysts and necrosis. It exhibited heterogeneous signal intensity with significant thick postcontrast enhancement. Significant surrounding edema and contralateral midline shift by 1.6 cm as well as uncal herniation were seen (Fig. 1). Spinal MRI showed multiple neurofibromas scattered all over the spinal axis.

The patient underwent an urgent left pterional craniotomy and total excision of the lesion. Histopathology (Fig. 2) revealed cystic high-grade glioma. The tumor was cellular and showed a variety of cell patterns. These included anaplastic or giant cells with marked nuclear atypia and pleomorphism and sheets of smaller round to oval cells. The cytoplasm amount was variable, from scant to abundant, and many cells were exhibiting a minigemistocyte appearance. Microvascular proliferation and areas of necrosis were evident. The Ki-67 proliferative index was high and estimated to exceed 20% in multiple areas. Mitoses were easily found, including atypical figures. The result of isocitrate dehydrogenase 1 (IDH-1) immunohistochemistry was negative. Cytogenetic analysis showed the presence of 1p/19q codeletion.

The patient's postoperative course was uneventful, and he received the standard treatment for glioblastoma (concurrent chemoradiotherapy [CCRT] and adjuvant temozolomide).

Routine postoperative chest radiography showed a large shadow in the left upper mediastinum. Chest CT showed a heterogeneously enhancing mass in the apex of the left lung/left paravertebral region extending to the left supraclavicular region, measuring approximately 6 × 7.2 × 7.5 cm and extending into the left T2/T3 neural foramina. Six months later, the patient underwent thoracotomy and total excision of the chest lesion. Histopathology (Fig. 3) revealed features of malignant nerve sheath tumor. These included cellular fascicles of spindle cell proliferation with thin hyperchromatic or vesicular nuclei. The nuclear pleomorphism was moderate to focally marked. The mitotic count exceeded 5/10 high-power field in areas. Atypical mitotic figures were noted. The tumor cells were positive for S100, with scattered axons that exhibited neurofilament immunostaining reactivity. No necrosis was identified. The tumor remained stable throughout follow-up.

The patient continued regular clinical and radiological follow-up with MRI that showed no signs of recurrence or progression. He remained in good health and stable condition until the summer of 2015, when he underwent a redo craniotomy and tumor debulking for a recurrent tumor. The tumor pathology was glioblastoma multiforme, and the patient received CCRT. A follow-up MRI in the fall of 2016 showed extensive high-grade recurrence in the left cerebral hemisphere, and the patient received 6 cycles of temozolomide as palliative chemotherapy.

In the spring of the following year, the patient presented to the emergency department with bilateral lower limb weakness, and CT of his brain showed recurrent tumor. The patient received 3 cycles of a single-agent palliative chemotherapy (bevacizumab) with stable disease, followed by 4 cycles of a bevacizumab/irinotecan regimen, and then he sought a second opinion elsewhere.

The patient remined in stable status until the fall of 2019, when he showed recurrence in his follow-up MRI with no clinical neurological deterioration. The patient received 4 cycles of bevacizumab/irinotecan.

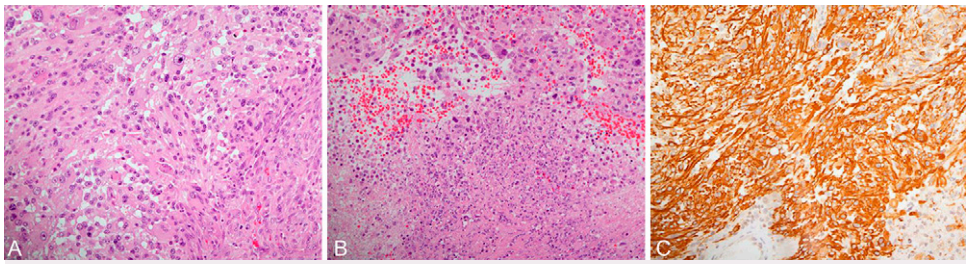

FIG. 2. A: The biopsies showed a high-grade glial tumor that exhibited a variety of cell patterns. These included anaplastic glial cells with marked nuclear atypia and pleomorphism and cell shapes that varied from small rounded to giant multinucleated (hematoxylin-eosin [H&E], original magnification ×200). **B:** Multiple foci of necrosis (lower half of the field) are evident (H&E, original magnification ×200). **C:** Glial fibrillary acidic protein (GFAP) confirms the glial nature of the tumor (GFAP, original magnification ×200).

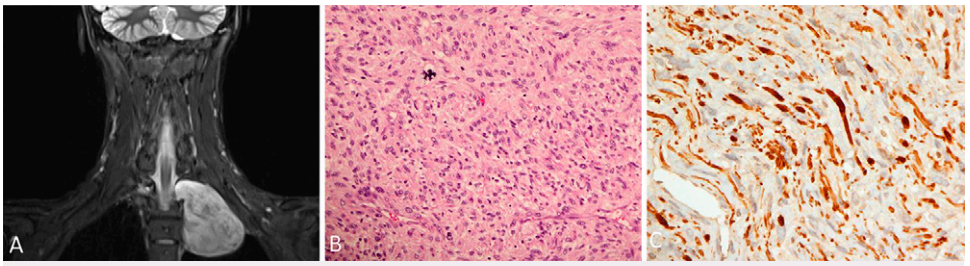

FIG. 3. A: Coronal T2-weighted images showing a large left supraclavicular mass with inhomogeneous enhancement that has intraforaminal but no intraspinal extension at T2–3 level. **B:** Sections from the lung mass show a sarcoma that exhibits high cellularity and marked nuclear pleomorphism. Atypical mitosis is noticeable in this field (hematoxylin-eosin, original magnification ×200). **C:** The tumor cells exhibit patchy S100 reactivity, which is compatible with a malignant peripheral nerve sheath tumor (S100, original magnification ×400).

One year later, the patient showed further progression of his tumor on MRI, with personality changes but no other symptoms, and he refused further treatment.

The patient was referred to psychiatry and is following up with our service with no evidence of clinical compromise, is communicating, and is able to walk with assistance.

Discussion

Observations

Our patient is a 27-year-old man with NF1 diagnosed with glioblastoma, wild type. He had a prolonged disease course with multiple lines of chemotherapy and radiotherapy and has survived for 10 years with no evidence of clinical compromise and with a good quality of life.

NF1-Associated Gliomas

NF1 is an autosomal dominant familial tumor syndrome with mutation of the NF1 gene located on chromosome 17q11.2. The incidence of NF1 is 1 in 2,000 to 5,000 individuals.[1] Alongside the characteristic café-au-lait spots and cutaneous nodules, low-grade brain tumors such as pilocytic astrocytomas and optic gliomas represent the majority of intracranial neoplasms in NF1.[7]

It is thought that the neurofibromin, the protein encoded by the NF1 gene, acts to inhibit the Ras signaling pathway. A mutation in the NF1 gene leads to uncontrolled cell growth, manifesting as multiple peripheral and central nervous system (CNS) tumors.[8] Gliomas are seen in approximately 20% of patients with NF1.[2] Although patients with NF1 are at a higher risk of developing low-grade gliomas (World Health Organization [WHO] CNS grade 1 and 2), the prevalence of high-grade gliomas in patients with NF1 is 10–50 times higher than in the general population.[9]

Optic pathway gliomas are the most common gliomas in patients with NF1. They usually present early in childhood (mean presenting age is 4.5 years). Nonoptic pathway gliomas usually present later in childhood or in early adulthood (mean presenting age is 7 years).[10] Gliomas presenting in adults with NF1 are usually high grade, arising in cerebral hemispheres.[11] A study on 100 NF1 individuals showed that 7% of patients with NF1 were diagnosed with grade IV gliomas.[12]

Glioblastoma in Adult Patients With NF1

In the general population, glioblastoma is the most common and most fatal primary brain tumor in adults.[13] It accounts for >60% of primary brain tumors in adults and 50% of gliomas across all age groups.[14] The global incidence of glioblastoma is 10 per 100,000 people.[15]

There are limited data on glioblastoma in patients with NF1. Few cases have been reported in the literature.[8,16] In the few reported cases (Table 1),[5,7,16–30] it is noted that the mean age of patients with NF1 with glioblastoma at diagnosis is much younger (mean age 34 years) than that of patients with sporadic glioblastoma (mean age 55 years).[31] In a systematic review of patients without NF1 with glioblastoma and >10-year survival, there was an inverse relationship between age at diagnosis and years of survival, where younger age at diagnosis by 4.7 years resulted in 1 year longer overall survival after 10 years of survival.[32]

Molecular Pathophysiology

The 2016 WHO classification of tumors in the CNS classifies gliomas on the basis of both histological and molecular features, including 1p/19q codeletion and IDH mutation.[33] In sporadic gliomas, an IDH mutation is detected in most cases, regardless of the grade.[34] Individuals harboring IDH mutation have a better prognosis than those with IDH wild type.[35,36]

Among the few reported glioblastoma cases in NF1, only 7 reported the molecular features of the tumors, with no IDH mutation detected (IDH wild type) except for 2 patients with IDH-1 mutation (Table 1). This might indicate that the NF1-associated glioblastomas have a different landscape from sporadic glioblastoma.[37]

A comprehensive genomic study included whole-exome sequencing for tumor and germline cells to further understand the rule of somatic mutations in tumorigenesis in patients with NF1. The data showed that there are no somatic mutations that clustered around the NF1 protein domain and supported the theory of a "second hit" of the heterozygous NF1 allele needed to develop a tumor.[37] In our patient, 1p/19q codeletion was present with no IDH mutation detected (glioblastoma, IDH wild type).

Treatment of Glioblastoma in Patients With NF1

All reported cases of glioblastoma in patients with NF1, including our case, received the standard therapy for glioblastoma (gross total resection followed by fractionated radiotherapy, with concurrent and adjuvant temozolomide), with second- and third-line administration at the time of recurrence as indicated.

The NF1 mutation is a marker for treatment-resistant gliomas. It leads to loss of neurofibromin and subsequent increase in RAS

TABLE 1. Summary of 24 adult patients with NF1 diagnosed with glioblastoma, with treatment, recurrence, and survival

Authors & Year	Age (yrs)/ Sex	Location	Molecular Features	Treatment	Recurrence	Survival (mos)	Functional Status
Miaux et al., 1997[17]	32/F	Occipital	NA	NA	NA	NA	NA
Miyata et al., 2005[18]	30/F	Right frontal	NA	SR + RT + chemotherapy (PCV)	10 mos	12 mos +	NA
Mehta et al., 2008[19]	63/M	Parietal	NA	Biopsy	NA	2 mos	NA
Hakan et al., 2008[20]	28/F	Frontal	NA	SR + RT + chemotherapy (TMZ)	NA	41 mos +	NA
Broekman et al, 2009[21]	28/F	Right cerebellar	NA	SR + RT + chemotherapy (TMZ)	6 mos	12 mos	Nystagmus, diplopia, facial numbness, ataxia
Theeler et al., 2014[5]	59/M	Right temporal	NA	SR + RT + chemotherapy (TMZ) + 17 cycles bevacizumab + irinotecan	24 mos	104.4 mos +	Stable
Theeler et al., 2014[5]	25/M	Thalamus	NA	RT + chemotherapy (TMZ) + 10 cycles bevacizumab + TMZ	2 mos	13.9 mos	Multiple ischemic strokes, sepsis
Theeler et al., 2014[5]	32/M	Cerebellar hemispheres	IDH wild type	RT + chemotherapy (TMZ) + adjuvant erlotinib 9 cycles + 37 cycles bevacizumab + irinotecan	3 mos	72.6 mos	Cardiac thrombosis
Jeong et al., 2014[7]	32/M	Right frontal	NA	SR + RT + chemotherapy (TMZ)	NA	9 mos +	NA
Varghese et al., 2015[22]	60/M	Right frontal	NA	SR + RT + chemotherapy (TMZ)	NA	NA	Hemiparesis improved
Ameratunga et al., 2016[23]	24/M	Left cerebellar	IDH wild type	Tumor debulking + RT + chemotherapy (TMZ) + SR + everolimus+ TMZ + MEK inhibitor (trametinib)	24 mos	24 mos +	Improved clinically, functional
Shibahara et al., 2018[24]	52/M	Occipital	NA	SR + RT + chemotherapy	NA	49 mos	NA
Shibahara et al., 2018[24]	34/M	Frontal	NA	SR + RT + chemotherapy	NA	106 mos +	NA
Shibahara et al., 2018[24]	28/M	Insula	NA	SR + RT + chemotherapy	NA	60 mos +	NA
Shibahara et al., 2018[24]	53/M	Frontal	NA	SR + RT + chemotherapy	NA	87 mos +	NA

CONTINUED ON PAGE 5 »

» CONTINUED FROM PAGE 4

TABLE 1. Summary of 24 adult patients with NF1 diagnosed with glioblastoma, with treatment, recurrence, and survival

Authors & Year	Age (yrs)/ Sex	Location	Molecular Features	Treatment	Recurrence	Survival (mos)	Functional Status
Singla et al., 2018[25]	25/M	Right frontal	NA	SR + RT	24 mos	36 mos +	Back to baseline, functional
Fortunato et al., 2018[26]	23/M	Brainstem	IDH wild type	SR + RT + chemotherapy (TMZ)	NA	1 mos	Adrenal insufficiency
Wong et al., 2019[27]	27/M	Multiple	IDH1 mutation	Subtotal resection + RT + chemotherapy (TMZ)	NA	39 mos	NA
Narasimhaiah et al., 2019[16]	21/F	Right frontoparietal lobe	NA	SR + RT + chemotherapy (TMZ)	NA	32 mos +	NA
Narasimhaiah et al., 2019[16]	26/M	Right paraventricular	NA	Subtotal resection + total resection 10 years later	120 mos	Lost follow up	NA
Flower & Gallo, 2019[28]	23/M	Cerebellar	NA	SR + RT + chemotherapy (TMZ)	17 mos	18 mos	Acute neurological decline, memory loss, unsteady gait, dysarthria, and dysphasia
Awada et al., 2020[29]	19/M	Brainstem	IDH 1 mutation	RT + chemotherapy (TMZ) + VEGF inhibitor (axitinib) + PCDL-1 inhibitor (avelumab) + axitinib + lomustine, 2 cycles + MEK inhibitor (trametinib)	6 mos	48 mos +	Back to baseline, functional
Cai et al., 2021[30]	51/F	Right temporal	IDH wild type	SR + RT + chemotherapy (TMZ)	NA	13 mos +	Headache and weakness improved, functional
Present case	27/M	Frontoparietal	IDH wild type 1p/19q codeletion	SR + RT + chemotherapy (TMZ) + bevacizumab + bevacizumab/ irinotecan	48 mos	121 mos +	Functional

NA = not available; PCDL-1 = programmed cell death 1 ligand; PVC = procarbazine, nimustine hydrochloride, and vincristine sulfate; RT = radiotherapy; SR = gross total resection; TERT = telomerase reverse transcriptase; TMZ = temozolomide; VEGF = vascular endothelial growth factor.

activity and other RAS effectors. This has led to the development of combination therapies targeting multiple steps of the RAS signaling pathway over the past 2 decades. Therapies such as mitogen-activated protein kinase kinase (MEK) inhibitors, BRAF inhibitors, and checkpoint inhibitors are under trial.[38,39] One report of a 19-year-old with a mesencephalic IDH-1 mutant glioblastoma did not undergo surgical resection because of the location of the tumor and received radiotherapy with 3 lines of chemotherapy with either recurrence or no improvement. The patient then received a MEK inhibitor (trametinib 2 mg once daily) with a subsequent BRAF inhibitor (dabrafenib 50 mg twice daily) and was alive with complete response at 4-year follow-up.[29] Our patient received CCRT twice, with multiple cycles of temozolomide, bevacizumab, and bevacizumab/irinotecan, all of which were well tolerated. He was also diagnosed with a malignant nerve sheath tumor shortly after diagnosis; the tumor was managed with surgical resection alone, and follow-up images showed a stable lesion throughout the decade.

Prognosis of Glioblastoma in Patients With NF1

Despite all advances in research technologies, glioblastomas remain incurable, with a median survival of only 15 months in sporadic cases.[15,40] Very few patients have long-term survival beyond 2.5 years.[31] Stupp et al.[41] reported 2-year survival figures for patients who underwent concurrent adjuvant temozolomide and radiotherapy. Only 5% of patients diagnosed with glioblastoma survive for >5 years, and this measure decreases to 2% among patients aged 65 years or older.[42]

Huttner et al.[6] reported that pediatric patients with NF1 are at higher risk of developing glioblastoma and have a better prognosis than children without NF1, with no reports on adult patients. The median survival rate of such cases with surgical resection, radiotherapy, and chemotherapy is 36 months, with maximum survival of 106 months.

Although it is challenging to conclude the survival rate from the few reported cases, available data (Table 1) show that the survival rate in adult patients with NF1 diagnosed with glioblastoma is approximately 34 months, with maximal survival of 104.4 months from the time of diagnosis, with conventional treatment for primary and recurrent tumor. In our case, our patient was alive at 121-month follow-up with radiological evidence of recurrence but overall good functional status and no neurological symptoms.

Lessons

This case report describes >10 years of overall survival of glioblastoma in a patient with NF1, which, to the best of our knowledge, has not been reported in the literature. Reports cases of patients with NF1 with longer survival rates may be attributed to the young age at diagnosis and relatively better tolerance of therapy. Larger molecular studies on patients with NF1 with glioblastoma are needed to better understand the molecular differences and how they may apply to future treatment plans and prognosis.

References

1. Rasmussen SA, Friedman JM. NF1 gene and neurofibromatosis 1. *Am J Epidemiol.* 2000;151(1):33–40.
2. Listernick R, Charrow J, Gutmann DH. Intracranial gliomas in neurofibromatosis type 1. *Am J Med Genet.* 1999;89(1):38–44.
3. Rasmussen SA, Yang Q, Friedman JM. Mortality in neurofibromatosis 1: an analysis using U.S. death certificates. *Am J Hum Genet.* 2001;68(5):1110–1118.
4. Guillamo JS, Créange A, Kalifa C, et al. Prognostic factors of CNS tumours in neurofibromatosis 1 (NF1): a retrospective study of 104 patients. *Brain.* 2003;126(Pt 1):152–160.
5. Theeler BJ, Ellezam B, Yust-Katz S, Slopis JM, Loghin ME, de Groot JF. Prolonged survival in adult neurofibromatosis type I patients with recurrent high-grade gliomas treated with bevacizumab. *J Neurol.* 2014;261(8):1559–1564.
6. Huttner AJ, Kieran MW, Yao X, et al. Clinicopathologic study of glioblastoma in children with neurofibromatosis type 1. *Pediatr Blood Cancer.* 2010;54(7):890–896.
7. Jeong TS, Yee GT. Glioblastoma in a patient with neurofibromatosis type 1: a case report and review of the literature. *Brain Tumor Res Treat.* 2014;2(1):36–38.
8. Ratner N, Miller SJ. A RASopathy gene commonly mutated in cancer: the neurofibromatosis type 1 tumour suppressor. *Nat Rev Cancer.* 2015;15(5):290–301.
9. Gutmann DH, Rasmussen SA, Wolkenstein P, et al. Gliomas presenting after age 10 in individuals with neurofibromatosis type 1 (NF1). *Neurology.* 2002;59(5):759–761.
10. Mahdi J, Shah AC, Sato A, et al. A multi-institutional study of brainstem gliomas in children with neurofibromatosis type 1. *Neurology.* 2017;88(16):1584–1589.
11. D'Angelo F, Ceccarelli M, Tala, et al. The molecular landscape of glioma in patients with neurofibromatosis 1. *Nat Med.* 2019;25(1): 176–187.
12. Rodriguez FJ, Perry A, Gutmann DH, et al. Gliomas in neurofibromatosis type 1: a clinicopathologic study of 100 patients. *J Neuropathol Exp Neurol.* 2008;67(3):240–249.
13. Wirsching HG, Galanis E, Weller M. Glioblastoma. *Handb Clin Neurol.* 2016;134:381–397.
14. Rock K, McArdle O, Forde P, et al. A clinical review of treatment outcomes in glioblastoma multiforme – the validation in a non-trial population of the results of a randomised phase III clinical trial: has a more radical approach improved survival? *Br J Radiol.* 2012; 85(1017):e729–e733.
15. Iacob G, Dinca EB. Current data and strategy in glioblastoma multiforme. *J Med Life.* 2009;2(4):386–393.
16. Narasimhaiah D, Sridutt BS, Thomas B, Vilanilam GC. Glioblastoma in adults with neurofibromatosis type I: a report of two cases. *Neuropathology.* 2019;39(5):368–373.
17. Miaux Y, Guermazi A, Cornu P, et al. High-intensity lesion on T1-weighted MR images in neurofibromatosis type 1: a case of premalignant lesion. *Acta Neurochir (Wien).* 1997;139(11): 1085–1087.
18. Miyata S, Sugimoto T, Kodama T, et al. Adenoid glioblastoma arising in a patient with neurofibromatosis type-1. *Pathol Int.* 2005; 55(6):348–352.
19. Mehta RS, Abraham M, Plesa C, Ennis P. Glioblastoma multiforme in an adult with von Recklinghausen disease. *Commun Oncol.* 2008;5(10):544–548.
20. Hakan T, Aker FV. Case report on a patient with neurofibromatosis type 1 and a frontal cystic glioblastoma. *Neurol Neurochir Pol.* 2008;42(4):362–365.
21. Broekman ML, Risselada R, Engelen-Lee J, Spliet WG, Verweij BH. Glioblastoma multiforme in the posterior cranial fossa in a patient with neurofibromatosis type I. *Case Rep Med.* 2009;2009: 757898.
22. Varghese P, Abdul Jalal MJ. A rare case of neurofibromatosis - type 1. *Asian J Neurosurg.* 2015;10(4):344–347.
23. Ameratunga M, McArthur G, Gan H, Cher L. Prolonged disease control with MEK inhibitor in neurofibromatosis type I-associated glioblastoma. *J Clin Pharm Ther.* 2016;41(3):357–359.
24. Shibahara I, Sonoda Y, Suzuki H, et al. Glioblastoma in neurofibromatosis 1 patients without IDH1, BRAF V600E, and TERT promoter mutations. *Brain Tumor Pathol.* 2018;35(1):10–18.
25. Singla N, Kapoor A, Radotra BD, Chatterjee D. Malignant conversion to glioblastoma in neurofibromatosis type I-associated pleomorphic xanthoastrocytoma: unknown predictors of favorable outcome. *Asian J Neurosurg.* 2018;13(3):826–829.
26. Fortunato JT, Reys B, Singh P, Pan E. Brainstem glioblastoma multiforme in a patient with NF1. *Anticancer Res.* 2018;38(8): 4897–4900.
27. Wong WH, Junck L, Druley TE, Gutmann DH. NF1 glioblastoma clonal profiling reveals *KMT2B* mutations as potential somatic oncogenic events. *Neurology.* 2019;93(24):1067–1069.
28. Flower H, Gallo P. Cerebellar glioblastoma in an NF1 patient. Is it surgical debulking really necessary? *Br J Neurosurg.* 2020;34(6): 669–671.
29. Awada G, Serruys D, Schwarze JK, Van De Voorde L, Duerinck J, Neyns B. Durable complete response of a recurrent mesencephalic glioblastoma treated with trametinib and low-dose dabrafenib in a patient with neurofibromatosis type 1. *Case Rep Oncol.* 2020;13(2):1031–1036.
30. Cai JW, Chen XY, Chen JY, et al. Glioblastoma in a female neurofibromatosis 1 patient without IDH1, BRAF V600E, and TERT promoter mutations: a case report. *Medicine (Baltimore).* 2021;100(13):e25346.
31. Ostrom QT, Gittleman H, Farah P, et al. CBTRUS statistical report: primary brain and central nervous system tumors diagnosed in the United States in 2006-2010. *Neuro Oncol.* 2013;15(2 Suppl): ii1–ii56.
32. Tykocki T, Eltayeb M. Ten-year survival in glioblastoma. A systematic review. *J Clin Neurosci.* 2018;54:7–13.

33. Louis DN, Perry A, Reifenberger G, et al. The 2016 World Health Organization classification of tumors of the central nervous system: a summary. *Acta Neuropathol.* 2016;131(6):803–820.
34. Yan H, Parsons DW, Jin G, et al. IDH1 and IDH2 mutations in gliomas. *N Engl J Med.* 2009;360(8):765–773.
35. Dubbink HJ, Taal W, van Marion R, et al. IDH1 mutations in low-grade astrocytomas predict survival but not response to temozolomide. *Neurology.* 2009;73(21):1792–1795.
36. Cheng HB, Yue W, Xie C, Zhang RY, Hu SS, Wang Z. IDH1 mutation is associated with improved overall survival in patients with glioblastoma: a meta-analysis. *Tumour Biol.* 2013;34(6):3555–3559.
37. Laycock-van Spyk S, Thomas N, Cooper DN, Upadhyaya M. Neurofibromatosis type 1-associated tumours: their somatic mutational spectrum and pathogenesis. *Hum Genomics.* 2011;5(6):623–690.
38. Gross AM, Wolters P, Baldwin A, et al. SPRINT: Phase II study of the MEK 1/2 inhibitor selumetinib (AZD6244, ARRY-142886) in children with neurofibromatosis type 1 (NF1) and inoperable plexiform neurofibromas (PN) [abstract]. *J Clin Oncol.* 2018;36(15 Suppl): 10503.
39. Rodriguez EF, Scheithauer BW, Giannini C, et al. PI3K/AKT pathway alterations are associated with clinically aggressive and histologically anaplastic subsets of pilocytic astrocytoma. *Acta Neuropathol.* 2011;121(3):407–420.
40. Koshy M, Villano JL, Dolecek TA, et al. Improved survival time trends for glioblastoma using the SEER 17 population-based registries. *J Neurooncol.* 2012;107(1):207–212.
41. Stupp R, Mason WP, van den Bent MJ, et al. Radiotherapy plus concomitant and adjuvant temozolomide for glioblastoma. *N Engl J Med.* 2005;352(10):987–996.
42. Ostrom QT, Gittleman H, Liao P, et al. CBTRUS statistical report: primary brain and central nervous system tumors diagnosed in the United States in 2007-2011. *Neuro Oncol.* 2014;16(4 Suppl): iv1–iv63.

Disclosures

The authors report no conflict of interest concerning the materials or methods used in this study or the findings specified in this paper.

Author Contributions

Conception and design: all authors. Acquisition of data: all authors. Analysis and interpretation of data: Basindwah, Alkhalidi, Elwatidy. Drafting the article: all authors. Critically revising the article: all authors. Reviewed submitted version of manuscript: Basindwah, Alkhalidi, Elwatidy. Approved the final version of the manuscript on behalf of all authors: Basindwah. Statistical analysis: Basindwah, Elwatidy. Administrative/technical/material support: Basindwah, Elwatidy. Study supervision: all authors.

Correspondence

Sarah Basindwah: College of Medicine, King Saud University, Riyadh, Saudi Arabia. sarah.basindwah@gmail.com.