

Spontaneous Disappearance of a Pericardial Cyst: Case Report and Literature Review

Angelo Pio Moffa, M.D.¹, Luca Pio Stoppino, M.D.¹,
Domenico Loizzi, M.D.², Paola Milillo, M.D.¹

Departments of ¹Radiology and ²Thoracic Surgery, University of Foggia

Pericardial cysts are rare benign anomalies generally discovered as incidental findings on radiographic images. Rarely, pericardial cysts cause symptoms and may lead to complications. A 56-year-old woman presented to the emergency department for mild chest pain. A cardiovascular and respiratory examination revealed no abnormalities, while a chest X-ray and subsequent thoracic computed tomography (CT) showed a pericardial cyst. The patient refused both percutaneous treatment and thoracic surgery. Three years later, a thoracic CT scan showed that the pericardial cyst had disappeared. Although the spontaneous resolution of these lesions is rare, this article highlights the possibility of conservative management in select cases.

Key words: 1. Pericardium
2. Cysts
3. Computed tomography
4. Imaging
5. Mediastinal disease

Case report

A 56-year-old Caucasian woman was admitted to the Emergency Department of University Hospital "Ospedali Riuniti" of Foggia for mild chest pain that lasted for about 3 hours. Her past medical history was significant for type 2 diabetes, hypertension, and hyperlipidemia. She had smoked 1 pack of cigarettes daily for 30 years. A physical examination revealed no abnormalities, with a blood pressure of 130/65 mm Hg, a heart rate of 77 beats/min, a respiratory rate of 17 breaths/min, and an SpO₂ of 99%. Electrocardiography (ECG) showed a sinus rhythm, a normal QT interval, and non-specific ST-T changes. Cardiac enzymes and other laboratory findings were also within the normal range. Lung and abdominal examinations were negative. The patient denied previous

thoracic trauma. She was further evaluated with a chest X-ray that showed an area of increased density on the right side of the heart (Fig. 1). Subsequently, a thoracic computed tomography (CT) scan (Toshiba Aquilion 64-TSX-101A/HC; Toshiba Medical Systems, Tokyo, Japan) demonstrated a mediastinal lesion (approximately 41×63 mm) with a cystic structure (attenuation of 0–10 Hounsfield units) adherent anteriorly to the chest wall and medially to the right pericardium (Fig. 1); this lesion was consistent with a pericardial cyst. No pleural effusion or mediastinal lymphadenopathy was evident on CT. The thoracic CT scan was performed without contrast medium administration in accordance with the patient's wishes. Therefore, the patient was referred to a cardiothoracic surgery consultation for the eventual treatment of the lesion, but she refused any further

Received: August 25, 2017, Revised: October 21, 2017, Accepted: October 23, 2017, Published online: February 5, 2018

Corresponding author: Angelo Pio Moffa, Department of Radiology, University of Foggia, Viale Luigi Pinto 1, 71122 Foggia, Italy (Tel) 39-333-6113398 (Fax) 39-0881-733866 (E-mail) angelomoffa@gmail.com

© The Korean Society for Thoracic and Cardiovascular Surgery. 2018. All right reserved.

© This is an open access article distributed under the terms of the Creative Commons Attribution Non-Commercial License (<http://creativecommons.org/licenses/by-nc/4.0>) which permits unrestricted non-commercial use, distribution, and reproduction in any medium, provided the original work is properly cited.

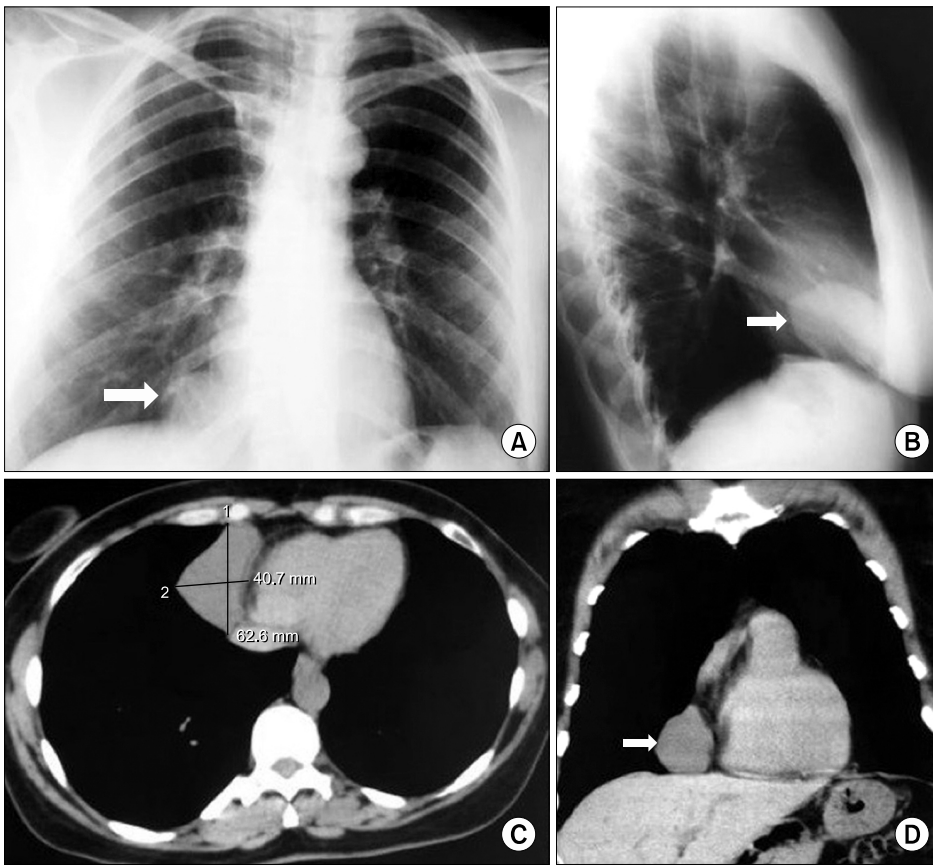


Fig. 1. (A) A posteroanterior chest X-ray revealed an opacity on the lower right border of the heart (arrow). (B) A right lateral-view chest X-ray localized the opacity in the middle mediastinum (arrow). (C) Axial and (D) coronal thoracic computed tomography scans showed a pericardial cystic lesion that measured 40.7×62.6 mm (arrow). This lesion abutted the chest wall and right pericardium. No pericardial effusion or mediastinal lymphadenopathy was evident.

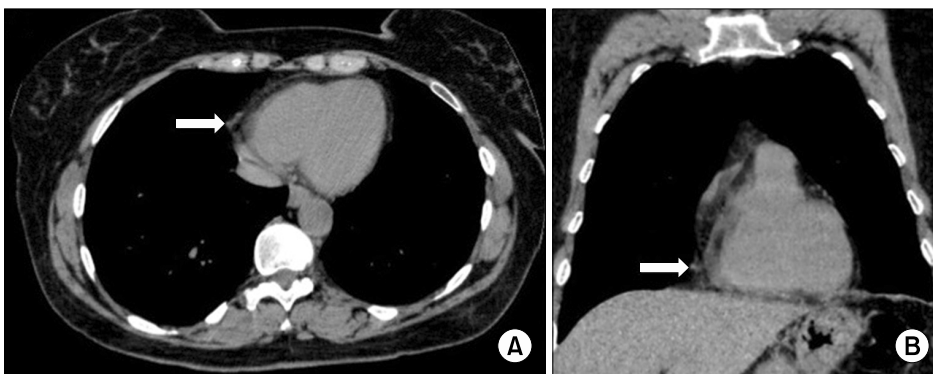


Fig. 2. Three years after the initial diagnosis, (A) axial and (B) coronal thoracic computed tomography scans revealed complete resolution of the pericardial cyst. An area of slight pericardial thickening can be observed on the right side of the heart (arrows).

clinical and diagnostic examinations. Three years later, during which interval the patient was completely symptom-free, she returned spontaneously to our attention to make sure that the mediastinal lesion had not increased, but a thoracic CT study revealed a complete resolution of the pericardial cyst (Fig. 2).

Discussion

Pericardial cysts are benign uncommon lesions located in the middle mediastinum, and occur in 1 person per 100,000 [1,2]. These lesions are unilocular and contain clear water-like fluid with the occasional addition of blood and necrotic cystic content; the cyst wall is formed of connective tissue lined by mesothelial cells [1,3]. They are more likely to be

found in middle-aged adults, most frequently in the third or fourth decade of life, and are equally common in men and women [4]. Classically, pericardial cysts are located at the right cardiophrenic angle (51%–70%) or the left cardiophrenic angle (28%–38%) and rarely in other mediastinal sites [5].

Pericardial cysts are usually detected incidentally during thoracic imaging studies, and most are asymptomatic (50%–75%) [1,6]. Only 25% to 30% of patients complain of chest discomfort, cough, dyspnea, or paroxysmal tachycardia [7]. Cardiac tamponade; mitral valve prolapse; atrial fibrillation; cystic rupture; erosion of the cyst into adjacent structures, such as the right ventricular wall or the superior vena cava; obstruction of the right main stem bronchus; and sudden death are life-threatening emergencies that have been reported in connection with pericardial cysts [5].

The treatment options for pericardial cysts include simple observation, excision by thoracotomy or thoracoscopic surgery, and minimally invasive procedures, such as percutaneous aspiration and ethanol sclerosis; no treatment is necessary in asymptomatic patients [4,6].

A literature review revealed that approximately 30% of patients with a pericardial cyst treated with percutaneous drainage experienced recurrence within 3 years, whereas sclerosis has been reported to decrease the recurrence rate after aspiration [1]. Instead, surgical excision (through thoracotomy, sternotomy, or video-assisted thoracoscopic surgery) has been demonstrated to be the only definitive curative treatment [1]. In particular, the indications for the resection of pericardial cysts include symptoms, large size, patient concern, uncertain malignant potential, and the prevention of complications [4], while asymptomatic patients can be treated conservatively [6].

In our case, we hypothesized that the patient's chest pain was caused by the presence of the pericardial cyst, so the patient was referred for a cardiothoracic surgery consultation. Nonetheless, the patient refused any further clinical and diagnostic examinations due to the benignity of the mediastinal lesion and the lack of symptoms in the following days. Surprisingly, after a period of 3 years in which the patient was completely asymptomatic, a thoracic CT scan revealed that the pericardial cyst had spon-

taneously disappeared, with only an area of residual pericardial thickening on the right side of the heart.

The spontaneous radiographic resolution of cystic lesions is a rare clinical entity [4,7]. To our knowledge, few cases have been reported in the literature of the spontaneous disappearance of these lesions without any invasive procedures performed in the area of the cysts. In particular, Shin and Ho [7] reported a case of a symptomatic 65-year-old man with a well-demarcated large right-side pericardial cyst that disappeared spontaneously during hospitalization with the concomitant relief of clinical symptoms. Abbey and Flores [3] described the spontaneous resolution of a left-side pericardial cyst after 17 months in a 55-year-old woman who experienced 1 symptomatic episode and who refused surgical treatment, as in our case. Finally, Martin et al. [8] presented a case of the complete resolution of a fluid-filled mass in the right cardiophrenic angle suggestive of a pericardial cyst in a 12-year-old patient.

Several mechanisms have been postulated regarding the spontaneous resolution of these cysts, but currently, the best supported hypothesis is cystic rupture into the pleural space [5]. In our case, we experienced the spontaneous and asymptomatic resolution of a right-side pericardial cyst, which we hypothesize to have occurred due to cystic rupture within the pleural space.

In conclusion, the spontaneous resolution of pericardial cysts is quite rare, and very few cases have been reported in the literature. In our case, the patient's wishes regarding therapeutic options were crucial. In patients followed conservatively, the possibility of resolution of the cyst should be contemplated, although it is rare.

Conflict of interest

No potential conflict of interest relevant to this article was reported.

References

1. Hekmat M, Ghaderi H, Tatari H, Arjmand Shabestari A, Mirjafari SA. *Giant pericardial cyst: a case report and review of literature*. Iran J Radiol 2016;13:e21921.
2. Kim JY, Koo HJ, Lee M, Kim GS, Jung SH. *Epicardial cyst originating from right ventricle*. Korean J Thorac Cardiovasc Surg 2013;46:138-41.

Disappearance of a Pericardial Cyst

3. Abbey AM, Flores RM. *Spontaneous resolution of a pericardial cyst*. Ann Thorac Cardiovasc Surg 2010;16:55-6.
4. Kaklikkaya I. *A giant pericardial cyst*. Cardiovasc J Afr 2011;22:e1-3.
5. Patel J, Park C, Michaels J, Rosen S, Kort S. *Pericardial cyst: case reports and a literature review*. Echocardiography 2004;21:269-72.
6. Borghouts VA, Stevenhagen YJ, Wagenaar LJ, Bouman DE, Verhorst PM. *'Elevated' hemidiaphragm due to a pericardial cyst*. Neth Heart J 2016;24:298-9.
7. Shin MS, Ho KJ. *Spontaneous radiographic resolution of malignant and benign cysts*. J Comput Tomogr 1986;10:99-106.
8. Martin KW, Siegel MJ, Chesna E. *Spontaneous resolution of mediastinal cysts*. AJR Am J Roentgenol 1988;150:1131-2.