

Case report

Open Access

Leiomyosarcoma presenting as a spontaneously ruptured renal tumor-case report

Mohammad Moazzam, M Hammad Ather* and Akber S Hussainy

Address: Department of Surgery and Pathology, The Aga Khan University, Karachi, 74800

E-mail: Mohammad Moazzam - drmoji@yahoo.com; M Ather* - hammad.ather@aku.edu; Akber S Hussainy - akber.hussainy@aku.edu

*Corresponding author

Published: 19 November 2002

Received: 11 September 2002

BMC Urology 2002, 2:13

Accepted: 19 November 2002

This article is available from: <http://www.biomedcentral.com/1471-2490/2/13>

© 2002 Moazzam et al; licensee BioMed Central Ltd. This is an Open Access article: verbatim copying and redistribution of this article are permitted in all media for any purpose, provided this notice is preserved along with the article's original URL.

Keywords: Non-traumatic, kidney rupture, kidney tumor, sarcoma

Abstract

Background: Ruptured renal neoplasms can be a catastrophic clinical presentation. Angiomyolipoma is the commonest renal tumor which presents in this fashion. Renal sarcomas are rare renal neoplasms. Renal leiomyosarcomas are the most common histological subtype of renal sarcomas, accounting for approximately 50–60% of the reported cases. These tumors are usually peripherally located and appear to arise from either the renal capsule or smooth muscle tissue in the renal pelvic wall.

Case presentation: A 70 years old male, with hypertension and ischemic disease, developed acute left flank pain. The general physician evaluated this using ultrasound, which showed a solid left renal mass. Two weeks later, he presented in the emergency room in a state of shock with a palpable flank mass. CT scan of the abdomen showed a large heterogeneous mass lesion in the left perinephric space with minimal post contrast enhancement. Per-operatively, large retroperitoneal hematoma was found within Gerota's fascia along with spleen plastered to the upper limit of hematoma. Nephrectomy and splenectomy were performed. Postoperative course was uneventful and patient was discharged on the 10th post-operative day. Histopathological evaluation of the specimen showed high-grade leiomyosarcoma

Conclusions: Spontaneous rupture of renal neoplasm is a rare clinical presentation. Angiomyolipoma is the commonest cause of spontaneous rupture of the kidney. Presentation of a leiomyosarcoma as a ruptured renal neoplasm has not been previously reported in the English literature.

Background

Leiomyosarcomas of the kidney make up to 0.5–1.5% of malignant renal tumors in adults [2]. There is no difference in the gender distribution with a mean age at diagnosis in the sixth decade. They typically presents with the classical triad of symptoms i.e. flank pain, hematuria, and abdominal mass mimicking renal cell carcinoma. Radio-

logical findings are nonspecific and diagnosis is usually made postoperatively.

Spontaneous rupture of renal neoplasm is commonly seen for large angiomyolipoma, occasional case report also describes cases of renal cell cancers and Wilm's tumor. Ruptured renal leiomyosarcoma is not previously re-

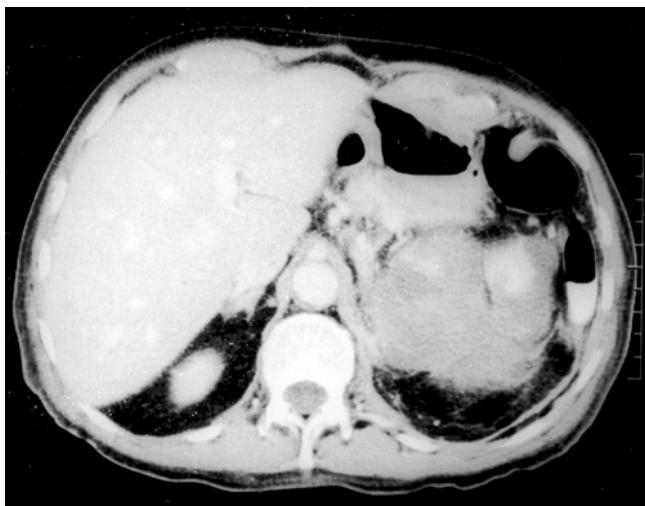


Figure 1
Post contrast spiral CT showing large retroperitoneal hematoma with minimal contrast uptake by the renal tissue confined to the upper pole of the left kidney.

ported in English literature. In non-English literature, there are two cases [2,3]. Yoshikawa et al reported a case of a spontaneously ruptured renal leiomyosarcoma, treated by nephrectomy followed by immuno-chemotherapy and radiotherapy [2]. At 18 months, follow up of patient was free of local recurrence and distant metastasis. Kyuno et al reported a case of spontaneous rupture of leiomyosarcoma, who died 2 months after nephrectomy of intestinal perforation.

Case presentation

A 70 years old male, known case of hypertension and ischemic disease, developed acute left flank pain, the general physician evaluated this by an ultrasound that showed a solid left renal mass. He was referred to this hospital for further evaluation, however, he presented in the emergency room with sudden onset of severe central abdominal pain, radiating to left flank increasing with movement and associated with two episodes of non-bilious vomiting. On clinical examination patient was haemodynamically stable, pale looking, with a bi-manually palpable left flank mass, extending to right hypochondrium. Initial laboratory work up showed a low Hemoglobin 6.1 g/dl (13.7–16.3), urinalysis showed microscopic haematuria, and serum creatinine 1.8 mg/dl.

CT scan of abdomen (Figure 1) showed a large heterogeneous mass lesion in the left perinephric space with minimal post contrast enhancement. After adequate resuscitation, nephrectomy was performed. Per-operatively, large retroperitoneal hematoma was found within Gerota's fascia along with spleen plastered to the upper

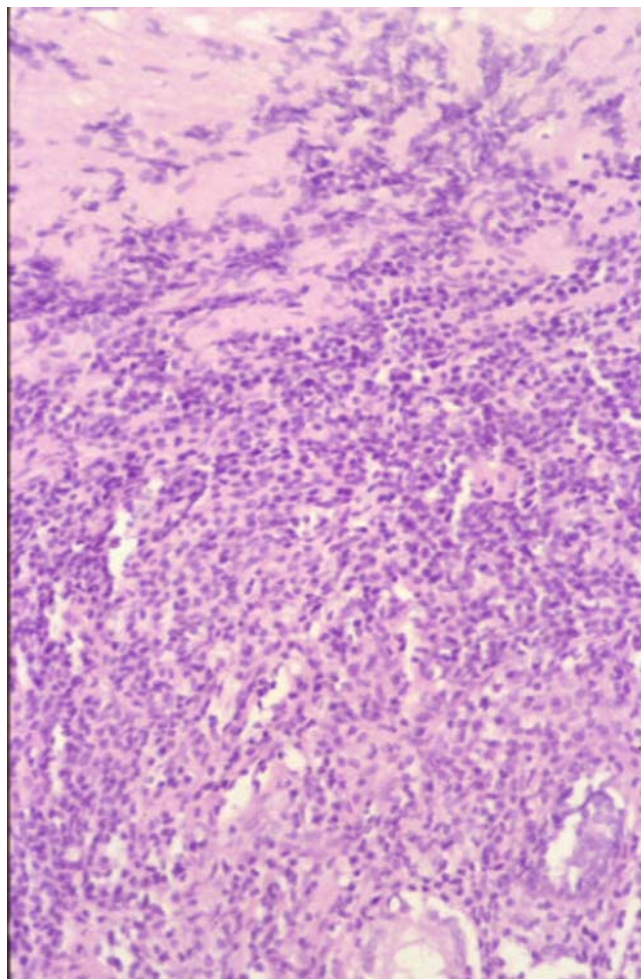


Figure 2
High power photomicrograph of Leiomyosarcoma exhibiting irregular bundles of spindle and polyhyal cells having pleomorphic vesicular nuclei. An abnormal mitotic figure is present in the center of the picture (H & E \times 200).

limit of hematoma. Nephrectomy and splenectomy were performed. Postoperative course was uneventful and patient was discharged on 10th post-operative day. Histopathological evaluation of the specimen showed high-grade leiomyosarcoma (figure 2). Sections were stained for a broad panel of immunohistochemical markers using monoclonal antibodies, which was positive for vimentin and α -smooth muscle actin (ASMA) and negative for desmin, S-100 and CD34. Patient refused radiotherapy and died 4 months after surgery.

Conclusions

Spontaneous rupture of renal neoplasm is a rare clinical presentation. Angiomyolipoma are the commonest cause of spontaneous rupture of kidney. Presentation of a le-

leiomyosarcoma as a ruptured renal neoplasm has not been previously reported in English literature.

Leiomyosarcomas even when confined to the kidney have a poor prognosis. Radical surgery offers the best chance of cure; role of adjuvant chemo-immunotherapy and/or radiotherapy remains debatable, due to paucity of data on the treatment of this rare renal neoplasm and divergent results from limited experience in literature.

Competing interests

None declared.

Authors' contributions

MM carried out the literature search and drafted the manuscript. MHA proposed that the manuscript be drafted, literature search and drafted the manuscripts. ASH conceived of the study, and participated in drafting the pathology aspect of the manuscript.

All authors read and approved the final manuscript.

Acknowledgements

Written consent was obtained from the patient's relative for publication of the patient's details.

References

1. Srinivas V, Sogani PC, Hadju SI, Whitmore WF Jr: **Sarcomas of the Kidney.** *J urol* 1984, **132**:13-16
2. Yoshikawa M, Hayashi Y, Sanma S, Maruyama Y, Hirao Y, Okajima E: **Spontaneous rupture of renal leiomyosarcoma: report of a case.** *Hinyokika-Kyo* 1986, **32(9)**:1282-7
3. Kyuno H, Iwamura M, Muramoto M, Kou H, Koshiha K: **A case of spontaneous rupture of renal leiomyosarcoma.** *Hinyokika-Kyo* 1996, **42(8)**:583-6

Pre-publication history

The pre-publication history for this paper can be accessed here:

<http://www.biomedcentral.com/1471-2490/2/13/prepub>

Publish with **BioMed Central** and every scientist can read your work free of charge

"BioMed Central will be the most significant development for disseminating the results of biomedical research in our lifetime."

Sir Paul Nurse, Cancer Research UK

Your research papers will be:

- available free of charge to the entire biomedical community
- peer reviewed and published immediately upon acceptance
- cited in PubMed and archived on PubMed Central
- yours — you keep the copyright

Submit your manuscript here:

http://www.biomedcentral.com/info/publishing_adv.asp

