



Modified Dynamic Anterior Stabilization (DAS) and Hill-Sachs Remplissage for the Treatment of Recurrent Anterior Shoulder Dislocation

Ion-Andrei Popescu, M.D., M.H.B.A., Diana Cosmina Neculau, M.S., Cosmin Simion, M.D., and Dragos Popescu, M.D., Ph.D.

Abstract: The optimal treatment for recurrent glenohumeral instability is a subject under debate. The recently described arthroscopic technique for dynamic anterior stabilization (DAS) fills the treatment indication gap between reconstructive bony procedures and soft tissue stabilization. However, indications for DAS are considered limited or not appropriate for patients with recurrent shoulder dislocations caused by severe bone defects. In this Technical Note, we present a modified all-arthroscopic DAS technique with added infraspinatus and posterior capsule remplissage to correct the extra-articular Hill-Sachs defect in a patient with recurrent dislocations and off-track bony lesions. The patient requested an alternative treatment option, other than the complication-prone Latarjet procedure.

Introduction

The management of recurrent anterior glenohumeral instability is still a matter of scientific debate.^{1–4} The recently described dynamic anterior stabilization (DAS) is a promising technique.⁵ A report of three cases,⁶ supported by a biomechanical study⁷ and three Technical Notes,^{5,8,9} have demonstrated the efficacy of transferring the long head of the biceps through a subscapularis split onto the anterior glenoid rim. The obtained anterior sling effect dynamically stabilizes the shoulder joint while preventing anterior dislocation. Indications for DAS were clearly stated, although previous authors advised not to use this technique in shoulders with severe bone defects.^{5,7,8} However, the consequences and complications after

glenoid augmentation procedures are concerning patients and surgeons.^{10–12} Therefore, we present the following alternative technique: modified all-arthroscopic dynamic anterior stabilization combined with Hill-Sachs remplissage (Video 1).

Surgical Technique (With Video Illustration)

Patient Installation and Arthroscopic Portals

The patient is installed in the beach chair position under total anesthesia with interscalene block. After surgical draping, a traction cable holding the forearm keeps the shoulder 30° of anterior elevation, 10° of abduction, and in a neutral rotation. Classic arthroscopic portals are used:

- **A portal**, known as the soft spot, 2 cm medial and 2 cm inferior from the posterolateral corner of the acromion,
- **B portal** at 2 cm inferior and lateral to the posterolateral corner of the acromion,
- **D portal** at 2 cm underneath the anterolateral corner of the acromion right above the long head of the biceps tendon (LHBT),
- **E portal** in front of the rotator interval so that any instrument enters tangent to the subscapularis upper margin.

First Step: Diagnostic Arthroscopy and Preparation

A 4-mm arthroscope is placed in the A portal, and a standard arthroscopic round diagnostic of the shoulder

Romanian Shoulder Institute, ORTOPEVICUM - Orthopaedic Surgery & Sports Clinic, Bucharest, Romania (I.-A.P., D.C.N., C.S., D.P.); SportsOrtho Department, Zetta Hospital, Bucharest, Romania (I.-A.P., D.C.N., C.S.); and University of Medicine and Pharmacy “Carol Davila” Bucharest, Romania (D.C.N., C.S.).

The authors report no conflicts of interest in the authorship and publication of this article. Full ICMJE author disclosure forms are available for this article online, as [supplementary material](#).

Received August 16, 2021; accepted October 8, 2021.

Address correspondence to Ion-Andrei Popescu, M.D., M.H.B.A., Romanian Shoulder Institute, ORTOPEVICUM - Orthopaedic Surgery & Sports Clinic, Bucharest 011663, Romania. E-mail: ionandrei.popescu@yahoo.com

© 2021 THE AUTHORS. Published by Elsevier Inc. on behalf of the Arthroscopy Association of North America. This is an open access article under the CC BY-NC-ND license (<http://creativecommons.org/licenses/by-nc-nd/4.0/>).

2212-6287/211186

<https://doi.org/10.1016/j.eats.2021.10.004>

is performed. The engaging bipolar bony lesion is documented: a deep and wide Hill-Sachs lesion that dislocates over the anterior margin of the glenoid in passive external rotation at more than 30° of abduction, a sclerotic anterior glenoid rim, as well as the absence of the anterior labral tissue. An arthroscopic rasp is placed through the D portal, and the anterior margin of the glenoid is released of scar tissue, and the bone is decorticated, from 4 to 5 o'clock position. The pre-subscapular bursa and the lateral part of the clavicular fascia are removed with the shaver through the E and D portals, until the anterior surface of the subscapularis is well observed.

Second Step: Suture Management

A free FiberWire suture (Arthrex, Naples, FL) is introduced through the E portal and placed underneath the LHBT. Through the D portal, a perforating suture grasper, e.g., a Clever Hook (DePuy Synthes, Raynham, MA), is passed into the LHBT, grabs the free suture in the middle, and retrieves only 1.5 cm of it, creating a simple loop above the tendon. Through the same D portal, a suture grasper is forwarded into the loop and pushed posterior to the LHBT to grab one free limb of the suture, which is then retrieved, through the loop, outside the shoulder. The same step is performed, but this time the instrument grabs the remaining suture limb anterior to the LHBT through the loop. A 360° double lasso, similar to a pretzel form, is performed into and around the biceps (Fig 1). Both suture ends are

then pulled outside the shoulder through the E portal, while the "pretzel loop" is tightened.

Third Step: Releasing the LHBT From the Intertubercular Groove and Proximal Tenotomy

The LHBT is released from its intertubercular tunnel by cutting the posterior pulley and the transverse ligament with the radiofrequency ablation probe (ArthroCare Corporation, Austin, TX) facing the lateral crista humeri through the D portal.

Fourth Step: Subscapularis Split

The arthroscope is placed into the D portal, and a Wirsinger rod (switching stick) is inserted into the A portal. The rod is advanced from posterior to anterior, parallel to the glenoid surface, until it pierces the subscapularis tendon, until its tip is visualized posterior to the conjoint tendon. The height of the subscapularis split is at one-third inferiorly and two-thirds superiorly, considering the height of the tendon. While performing gentle internal-external rotation, the subscapularis split is enlarged and prepared to receive the transtendinous transfer of the LHBT.

Fifth Step: Transferring the LHBT and Tenodesis

The switching stick is replaced by a suture grasper that pulls the LHBT sutures through the subscapularis split and then outside the A portal. Once the sutures are positioned for the coming transfer (Fig 2), a simple tenotomy is performed at the level of the LHBT root

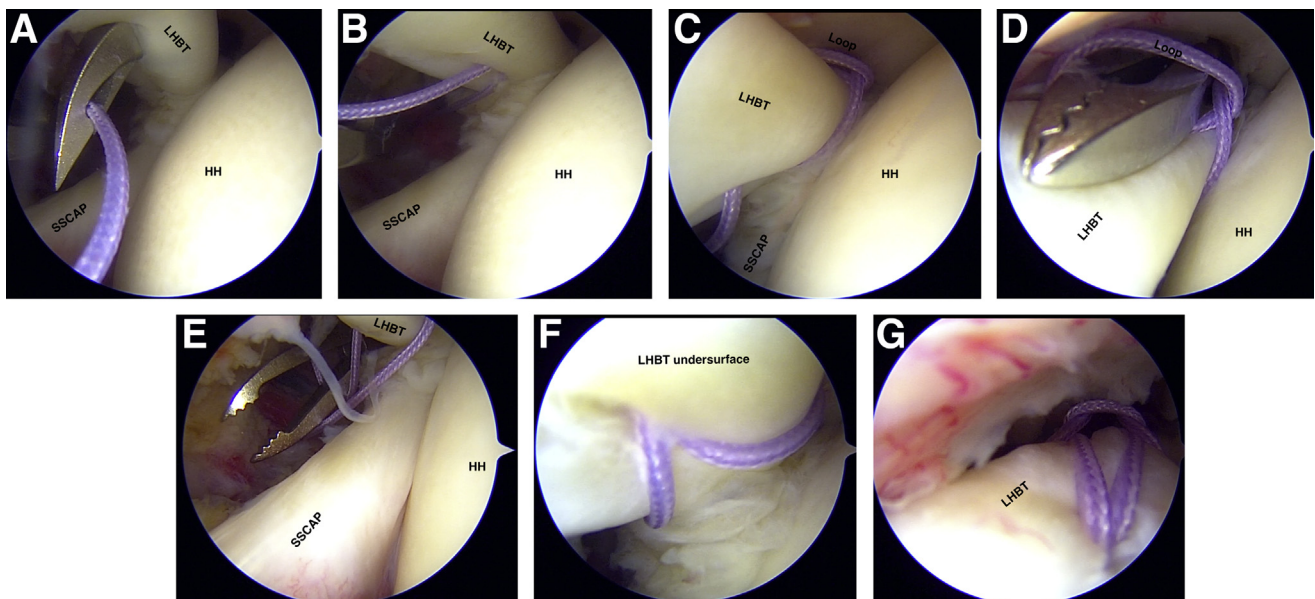


Fig 1. Initial suture management for the "pretzel loop". Right shoulder arthroscopic view with the camera in the posterior portal: (A) A free suture is introduced above the subscapularis tendon (SSCAP) and humeral head (HH) right underneath the long head of the biceps tendon (LHBT). (B) The suture is passed through the LHBT using a piercing instrument, creating a simple loop above the tendon. (C) One suture end is passed posterior to the tendon and then retrieved through the loop then outside the shoulder. (D and E) The remaining suture limb is passed anterior to the LHBT and retrieved through the loop. (F) View from underneath the LHBT. (G) View from above the LHBT.

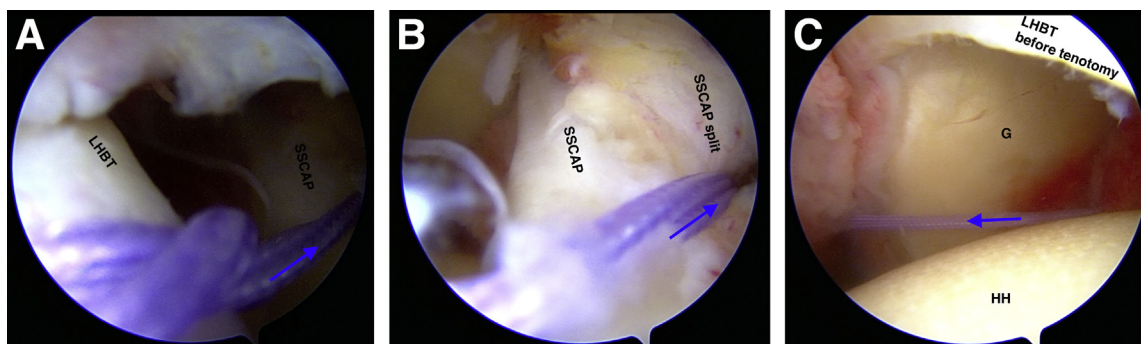


Fig 2. Suture management preceding the trans-subscapular transfer of the long head of the biceps tendon (LHBT). Arthroscopic view from the anterolateral portal in a right shoulder with ► demonstrating the direction of the transfer. (A) “Pretzel loop” seen above LHBT and suture limbs descending extraarticular towards anterior surface of the subscapularis (SSCAP). (B) view of the glenoid (G), the SSCAP, and the sutures passing through a SSCAP split. (C) Suture ends reentering the glenohumeral joint through the SSCAP split and retrieved outside the posterior portal. HH, humeral head.

without injuring the superior labrum. The trans-subscapular transfer of the LHBT is performed by gentle pulling of both suture limbs from the A portal, while simultaneously pushing the tendon with a tissue grasper from the E portal. Once the biceps is observed intraarticularly, its suture limbs are passed over the superior subscapularis margin and then retrieved outside the E portal.

The LHBT tenodesis is performed using a knotless 3.5-mm Pushlock anchor (Arthrex, Naples, FL) onto the anterior glenoid margin between 4 and 5 o’clock position, using the E portal. The sling effect is observed in the presubscapular space and intra-articularly (“outside and inside the box”) having the scope in the D portal. The suture ends are cut flush to the bone surface.

Sixth Step: Hill-Sachs Remplissage (Capsulotenodesis)

The surface of the Hill-Sachs defect is debrided with a burr through the A portal, while holding the shoulder in slight external rotation and increased anterior elevation. The arthroscope is brought back into the A

portal, now pointed toward the Hill-Sachs defect. Keeping the shoulder in a neutral rotation, a 4.5 Helicoil anchor (Smith & Nephew, Andover, MA) is placed in a transtendinous fashion right into the Hill-Sachs defect. Anchor suture limbs are picked one by one using a Clever Hook and passed through the infraspinatus tendon and capsule in a mattress suture construct. Finally, the scope is pushed subacromially, all 4 suture limbs are retrieved together through the same B portal and then knotted down and cut.

Seventh Step: Final Arthroscopic Evaluation

The LHBT transfer is visualized through the D portal, while bringing the scope in the front and on the back of the subscapularis, “outside and inside the box”. Pointing the scope downward visualizes the correct release from the intertubercular groove with no kinking of the LHBT at that level. The effectiveness of the remplissage is observed when pointing the scope posteriorly and pushing the humeral head anteriorly like in an anterior drawer movement. Finally, gentle glenohumeral external-internal rotation is performed to observe the

Table 1. Tips and Tricks

-
- No cannulas are needed: Debride each portal on its undersurface to avoid bursal tissue or fascia interposition.
 - Clean thoroughly the presubscapular bursa until a complete view of the posterior surface of the conjoint tendon is seen, and you have a good view over the transverse ligament.
 - Through the E portal, bring the FiberWire suture underneath the long head of the biceps tendon (LHBT), exactly where the Clever Hook will exit after piercing the tendon; it facilitates catching the suture.
 - Perform the LHBT release from its groove always with the probe facing laterally, so as not to injure the subscapularis insertion.
 - Double check the complete release of the LHBT from its groove by changing the scope position into the D portal and pointing it inferiorly. Dissect and release further inferiorly if needed.
 - Make sure to have a good view of the subscapularis, on its posterior and anterior surface (“inside and outside the box”), so that you can observe the correct position of the split and to avoid advancing the Wirsinger rod way too anteriorly, through the conjoint tendon, for example.
 - Depending on the patient’s anatomy, it might be necessary to locate and dissect the axillary nerve in order to protect it, while performing the subscapularis split.
 - Rather, push the LHBT into the split through the E portal rather than pulling it by the sutures from the A portal, or at least perform both simultaneously
 - Perform site preparation and suture management first, and LHBT tenotomy and tenodesis at the end.
-

Table 2. Advantages and Limitations

Advantages	Limitations
Simple and straightforward technique, safer than the arthroscopic Latarjet	No long-term follow-up
All arthroscopic procedure with excellent visualization and control	Revision options and complications management are still under research.
Implies standard arthroscopic equipment, instruments, and implants	Routine experience in shoulder arthroscopy is required.
The "pretzel loop" is a simple 360° suture fixation construct that does not slide even when longitudinal raisers of the tendon occur, and it contains less suture material than the Krakow stitches	The concomitant remplissage can limit the external rotation.
General advantages of the dynamic anterior stabilization (DAS) technique ⁵ strengthened by the added Hill-Sachs remplissage:	General disadvantages of the DAS technique: ⁵
- hammock effect in lower abduction, sling effect in high abduction and external rotation	- weaker sling and hammock effect than after the Latarjet procedure - no glenoid surface augmentation- can modify arm shape and create biceps pain

anterior sling effect and the coverage of the Hill-Sachs defect.

Postoperative Care

We recommend shoulder immobilization in a sling with abduction pillow and neutral rotation for the first 4 weeks, and then gradually passive mobilization and active assisted range-of-motion exercises. Active shoulder rehabilitation and physiotherapy can be initiated at 6 weeks but with active resistant elbow flexion limited to a maximum of 3 kg for another 2 months. Additional tips and tricks to this surgical technique (Video 1) are listed in Table 1.

Institutional Review Board Approval

All procedures performed in studies involving human participants were in accordance with the ethical standards of the institutional and national research committee and with the 1964 Helsinki declaration and its later amendments or comparable ethical standards. For this type of study, formal consent is not required. The patient signed a specific consent accepting that anonymized medical data, including video recording of the surgery, can be used for scientific and educational purposes as long the patient identity and personal data are protected.

Discussion

When confronted with recurrent anterior shoulder instability, treatment options depend on the defect size of the glenoid and of the humeral head.^{3,14,15} So far, soft tissue stabilization procedures (labral reinsertion,¹ remplissage techniques¹³) and bone augmentation techniques (Latarjet, Eden-Hybinette¹⁶) have been shown to be effective if their indication respects the demonstrated threshold related to off-track/on-track measurements of the bipolar lesion.^{2,4,14,17} However, each technique has specific limitations. Shoulder instability is a dynamic condition, and as previous research demonstrates, the recommendation to opt out

of soft tissue stabilization in favor of bone augmentation, or vice versa, is constantly changing.^{3,14}

The newly introduced DAS technique can fill the treatment indication gap, at least in selected cases, as in the case presented here, however, not alone, because of the large engaging Hill-Sachs defect.^{14,18}

Latarjet and Eden-Hybinette procedures are technically demanding, with a long learning curve, and have associated risks of neurovascular injuries, among other significant complications.¹² Graft complications are well known,¹² similar to the postinterventional risk of developing arthrosis due to the increased pressure created by the graft on the humeral cartilage.^{19,20} The Latarjet procedure contains an additional risk of consequent superior instability by damaging the coracoacromial ligament⁸ and may create scapular dyskinesia because of the mandatory pectoralis minor tenotomy.²¹ Furthermore, it may be insufficient in persistent off-track cases caused by big Hill-Sachs defects, in which case a combined procedure should be performed.²²

The DAS technique creates the desired stabilizing anterior "sling and hammock effect," and the remplissage renders the Hill-Sachs defect extra-articular. The combination of the two treatment options is an alternative to the more complicated trans-subscapular transfer of the coracoid process but without the neurovascular or graft risk. Moreover, it can be performed with minimal invasion, without the need of complex dissection or graft preparation, using only 4 standard arthroscopic portals.

Advantages and limitations of the presented combined technique of arthroscopic DAS and remplissage are listed in Table 2. Surgical risks are considered to be lower than in the arthroscopic Latarjet technique, but they are all related to the quality of the arthroscopic dissection and proper visualization:

- risk of damaging the axillary vessels and nerve or the nerve branches for subscapularis muscle,
- risk of insufficient liberation of the LHBT from its groove, causing recalcitrant postoperative pain or range of motion limitation,

BOX. Patient Selection, Evaluation and Indication

The presented arthroscopic technique was performed on a 42-year-old patient who suffered around 20 recurrent shoulder dislocations over the past 15 years. The first dislocation was traumatic, and the last 5 occurred while he was sleeping. He is otherwise healthy and pursues a mixed bureau and active job as salesman without excessive physical activities or manual labor. He does not practice contact sports, apart from playing soccer with friends once a week. Even though the glenoid bone loss was estimated being less than 20%, as seen in the [Video 1](#), the deep and wide Hill-Sachs defect was the biggest concern. After receiving the indication for Latarjet procedure from different surgeons, he was worried about the specific complications and risks, and specifically searched for a surgical alternative. The patient was actively involved in the documentation process of the informed consent, wished to avoid possible complications after arthroscopic coracoid process transfer, and opted for a combined soft tissue stabilization. The patient accepted that his anonymized data concerning a different, and until now unpublished, surgical strategy will be submitted for publication and provided his consent for the described procedure.

- risk of longitudinal tearing the LHBT during the suture management, and
- risk of improper tenodesis on the antero-inferior glenoid border if the tension in the transferred LHBT is too high.

One of the drawbacks of this procedure is that there are no known long-term follow-up results. Until these become available, it is recommended that the surgeon have revision options in mind, which will certainly inform future biomechanical studies in the evolving field of shoulder instability.

References

1. Hurley ET, Matache BA, Wong I, et al. Anterior shoulder instability: Part I. Diagnosis, non-operative management, and Bankart repair—An international consensus statement. *Arthroscopy* In press. <https://doi.org/10.1016/j.arthro.2021.07.022>.
2. Hurley ET, Matache BA, Wong I, et al. Anterior Shoulder Instability Part II - Latarjet, Remplissage, and Glenoid Bone-Grafting - An International Consensus Statement. *Arthroscopy* In press. <https://doi.org/10.1016/j.arthro.2021.07.023>.
3. DeFroda SF, Perry AK, Bodendorfer BM, Verma NN. Evolving concepts in the management of shoulder instability. *Indian J Orthop* 2021;55:285-298.
4. Friedman LGM, Lafosse L, Garrigues GE. Global perspectives on management of shoulder instability: Decision making and treatment. *Orthop Clin North Am* 2020;51:241-258.
5. Collin P, Lädermann A. Dynamic anterior stabilization using the long head of the biceps for anteroinferior glenohumeral instability. *Arthrosc Tech* 2018;7:e39-e44.
6. Azevedo CDC, Angelo AC. All-suture anchor dynamic anterior stabilization. *JBJS Case Connect* 2021;11:1-9.
7. Mehl J, Otto A, Imhoff FB, et al. Dynamic anterior shoulder stabilization with the long head of the biceps tendon: A biomechanical study. *Am J Sports Med* 2019;47:1441-1450.
8. Milenin O, Toussaint B. Labral repair augmentation by labroplasty and simultaneous trans-subscapular transposition of the long head of the biceps. *Arthrosc Tech* 2019;8:e507-e512.
9. Tang J, Zhao J. Arthroscopic transfer of the long head of the biceps brachii for anterior shoulder instability. *Arthrosc Tech* 2017;6:e1911-e1917.
10. Hurley ET, Jamal MS, Ali ZS, Montgomery C, Pauzenberger L, Mullett H. Long-term outcomes of the Latarjet procedure for anterior shoulder instability: A systematic review of studies at 10-year follow-up. *J Shoulder Elb Surg* 2019;28:e33-e39.
11. Cerciello S, Corona K, Morris BJ, Santagada DA, Maccauro G. Early outcomes and perioperative complications of the arthroscopic Latarjet procedure: Systematic review and meta-analysis. *Am J Sports Med* 2019;47:2232-2241.
12. Popescu I-A, Haeni D. Complications of bony procedures for shoulder instability. In: *Complications in arthroscopic shoulder surgery*. New York: Springer International Publishing, 2020;51-64. https://doi.org/10.1007/978-3-030-24574-0_6.
13. Rahu M, Kartus J-T, Pöldoja E, Kolts I, Kask K. Hill-Sachs remplissage procedure based on posterosuperior capsulomuscular anatomy. *Arthrosc Tech* 2019;8:e623-e627.
14. Lubowitz JH, Brand JC, Rossi MJ. Proper evaluation of bone loss determines shoulder instability indications and outcomes. *Arthroscopy* 2021;37:785-786.
15. Hurley ET, Lim Fat D, Farrington SK, Mullett H. Open versus arthroscopic Latarjet procedure for anterior shoulder instability: A systematic review and meta-analysis. *Am J Sports Med March* 2019;47:1248-1253.
16. Valenti P, Martinez-Catalan N, Werthel J-D, Kazum E. Full arthroscopic Eden-Hybinette procedure using 2 cortical suture buttons for the reconstruction of anteroinferior glenoid defects. *Tech Hand Up Extrem Surg* In press. <https://doi.org/10.1097/BTH.0000000000000348>.
17. Lau BC, Hutyra CA, Gonzalez JM, et al. Surgical treatment for recurrent shoulder instability: Factors influencing surgeon decision making. *J Shoulder Elbow Surg* 2021;30:e85-e102.
18. Eichinger JK. Editorial Commentary: If you want your arthroscopic Bankart repairs to be durable for 10 years

- consider treating the Hill-Sachs lesion with remplissage. *Arthroscopy* 2019;35:1368-1369.
19. Sano H, Komatsuda T, Abe H, Ozawa H, Yokobori TA. Proximal-medial part in the coracoid graft demonstrates the most evident stress shielding following the Latarjet procedure: A simulation study using the 3-dimensional finite element method. *J Shoulder Elbow Surg* 2020;29:2632-2639.
 20. Sano H, Komatsuda T, Abe H, Ozawa H, Kumagai J, Yokobori TA. Intra-articular biomechanical environment following modified Bristow and Latarjet procedures in shoulders with large glenoid defects: relationship with postoperative complications. *J Shoulder Elb Surg* 2021;30:2260-2269.
 21. Carbone S, Moroder P, Runer A, Resch H, Gumina S, Hertel R. Scapular dyskinesis after Latarjet procedure. *J Shoulder Elb Surg* 2016;25:422-427.
 22. Calvo C, Calvo J, Rojas D, Valencia M, Calvo E. Clinical relevance of persistent off-track Hill-Sachs lesion after arthroscopic Latarjet procedure. *Am J Sports Med* 2021;49:2006-2012.