

## Acute Right Coronary Ostial Stenosis during Aortic Valve Replacement

Sarwar Umran, Govind Chetty<sup>1</sup>, Pradip K Sarkar<sup>1</sup>

Department of Plastic Surgery, Salisbury District Hospital, Salisbury SP2 8BJ, <sup>1</sup>Department of Cardiothoracic Surgery, Northern General Hospital, Sheffield, England

### Correspondence to:

Sarwar Umran,  
ST2 Plastic Surgery,  
Department of Plastic Surgery, Salisbury  
District Hospital, Odstock Road,  
Salisbury SP2 8BJ England.  
E-mail: u.sarwar@doctors.org.uk

**Date of Submission:** Oct 04, 2011

**Date of Acceptance:** Oct 29, 2011

**How to cite this article:** Umran S, Chetty G, Sarkar PK. Acute right coronary ostial stenosis during aortic valve replacement. *Int J Prev Med* 2012;4:295-7.

### ABSTRACT

We report a rare case of acute right coronary artery stenosis developing in a patient undergoing aortic valve replacement. We present a case report with a brief overview of the literature relating to coronary artery occlusion associated with cardiac valve surgery – the theories and treatments are discussed. A 85 year-old female was admitted under the care of the cardiothoracic team with signs and symptoms of heart failure. Investigations, including cardiac echocardiography and coronary angiography, indicated a critical aortic valve stenosis. Intraoperative right ventricular failure ensued post aortic valve replacement. Subsequent investigations revealed an acute occlusion of the proximal right coronary artery with resultant absence of distal flow supplying the right ventricle. An immediate right coronary artery bypass procedure was performed with resolution of the right ventricular failure. Subsequent weaning off cardiopulmonary bypass was uneventful and the patient continued to make excellent recovery in the postoperative phase. To our knowledge this is one of the few documented cases of intraoperative acute coronary artery occlusion developing during valve surgery. However, surgeons should be aware of the potential for acute occlusion so that early recognition and rapid intervention can be instituted.

**Keywords:** Aortic valve surgery, cardiac surgery, coronary artery stenosis, coronary artery

### INTRODUCTION

Iatrogenic intraoperative acute coronary artery obstruction is a rare and potentially fatal complication of valve surgery. Initially described in 1967, following aortic valve surgery, it is now recognized that patients who develop myocardial ischemia-type chest pain or tachyarrhythmias, in the postoperative phase following valve surgery, should be investigated thoroughly to exclude this rare phenomenon as the cause of myocardial dysfunction.

Although most reports highlight the potential for coronary artery stenosis in the months following valve surgery there are few documented cases of intraoperative coronary embolism causing circulatory collapse and requiring prompt treatment.

We present such a case of acute intraoperative proximal right coronary artery obstruction during aortic valve replacement (AVR) and its immediate management.

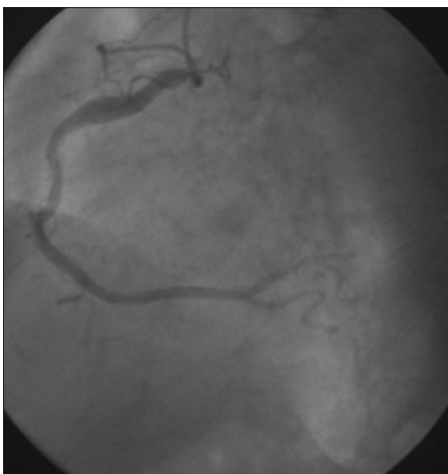
## CASE REPORT

An 85-year-old woman with critical aortic stenosis, awaiting elective admission for aortic valve replacement (AVR), was admitted to hospital with symptoms of heart failure. The transthoracic echocardiogram revealed a peak aortic gradient of 86 mmHg, an aortic valve area of 0.5 cm<sup>2</sup>, moderate left ventricular dysfunction, and a normal right ventricle with mild pulmonary hypertension.

Coronary angiography revealed a mild left anterior descending artery lesion, with a normal left main stem, and normal, dominant, right and circumflex arteries [Figure 1]. The resting electrocardiogram (ECG) showed normal sinus rhythm.

The intraoperative findings revealed a moderately calcified tri-leaflet aortic valve with moderate annular calcification and severe calcification in the aortic wall superior to the ostium of the right coronary artery (RCA). A transverse aortotomy was performed; the valve was excised and the annulus decalcified, followed by multiple saline washouts and a 19-mm Perimount (Edwards Life Sciences) bioprosthesis was implanted.

On discontinuation of the cardiopulmonary bypass (CPB), there was prominent right ventricular dilatation, with poor contractility. A full bypass was reinstated, with increase in perfusion pressure and



**Figure 1:** Preoperative angiogram demonstrating normal coronary arteries

the heart rested. On a second attempt at weaning from bypass, although initially appearing fine, the right ventricle (RV) gradually dilated with poor contractility. An intra-aortic balloon pump was placed with no significant improvement of the cardiac index. In light of the heavy aortic annular calcification and poor contractility of the RV, the distal RCA was opened on bypass with a beating heart to reveal no flow from the proximal RCA. Therefore, coronary artery bypass to the distal right coronary sinus was performed. On revascularization, excellent flow was observed through the RCA and on discontinuation of cardiopulmonary bypass a normal contracting RV was immediately apparent. The fact that there was no flow from the proximal RCA raised the possibility of an acute RCA obstruction due to calcium embolus.

Postoperatively the patient continued to make good progress and on day four a cardiac echocardiogram revealed good RV function. At the six-week follow-up the patient remains well.

## DISCUSSION

Coronary artery stenosis post valve surgery is a rare entity in cardiothoracic surgery, with reports putting the incidence anywhere between 0.3 and 5%.<sup>[1]</sup> Initially described by Roberts and Morrow in 1967, during the postmortem histological analysis of coronary arteries in patients who had undergone AVR,<sup>[2]</sup> it is now a recognized phenomenon as a cause of postoperative angina and ventricular impairment developing in individuals post valve-surgery with preoperative normal coronary arteries.

Thus far, the exact cause of coronary stenosis is unknown, although various theories have been postulated: The insertion of coronary cannulae for cardioplegia, causing immediate traumatic insults on the coronary vessels; intimal thickening, and fibrous proliferation, secondary to turbulent blood flow around the prosthetic valves; immunological reaction to the graft utilized in valve surgery; and genetic predisposition, have all been postulated as potential causes.<sup>[3-5]</sup>

Presentation consisting of angina and ventricular arrhythmias, usually occurring some months after initial valve surgery is common,<sup>[1,3,4,6,7]</sup> although cases of electromechanical dissociation as early as 12 days post the operation have been documented<sup>[8]</sup> The diagnosis is often made by

angiography with revascularization, either by percutaneous intervention<sup>[1,4,7]</sup> or a coronary artery bypass graft.<sup>[3,6]</sup>

Our patient developed acute obstruction of the proximal RCA intraoperatively. The acuteness would imply that the aforementioned theories for coronary stenosis are not applicable in this instance. The clinical sequelae in this patient strongly points to calcium emboli mobilized during the initial aortotomy, causing occlusion of the proximal RCA. Albeit occurring in the left coronary artery, Pifarre *et al.* document a similar occurrence, in their patient undergoing AVR.<sup>[9]</sup> Sanchez-Recalde *et al.* describe a patient who developed total ostial occlusion of the RCA and died twelve days post AVR for aortic stenosis. The post mortem results showed accumulation of calcium-like material occluding the RCA ostium.<sup>[8]</sup>

Kinoshita *et al.*,<sup>[10]</sup> describe an interesting case of coronary artery spasm occurring in cardiac procedures for both revascularisation and valve surgery. In their series of five patients, all exhibited features of hemodynamic collapse and ventricular tachyarrhythmia during the period of reperfusion following discontinuation of CPB. In addition, similar to our patient, the free wall of the RV exhibited poor contractility and dilatation. As in our patient, an intra-aortic balloon pump was initially utilised to improve the cardiac index. However, they rule out mechanical obstruction as the cause of the circulatory failure although, in one patient undergoing re-fixation of an aortic valve, a probe was inserted into the RCA ostium. Treatment consisted of trinitroglycerine and diltiazem to unmask the effects of the vasospasm, with success in four of the five patients strongly pointing to spasm as the cause.

In conclusion, we have demonstrated a rare phenomenon of calcium emboli causing acute occlusion of the coronary ostium and thereby leading to hemodynamic instability. Rapid revascularisation was successful in returning the patients hemodynamic status and providing a

favourable outcome. Surgeons should be aware of the potential for acute occlusion so that early recognition and rapid intervention can be instituted.

## REFERENCES

1. Thomopoulou S, Sfirakis P, Spargias K. Angioplasty, stenting and thrombectomy to correct left main coronary stem obstruction by a bioprosthetic aortic valve. *J Invasive Cardiol* 2008;20:124-5.
2. Roberts WC, Morrow AG. Late postoperative pathological findings after cardiac valve replacement. *Circulation* 1967; Apr;35(4 Suppl):148-62.
3. Sethi GK, Scott SM, Takaro T. Iatrogenic coronary artery stenosis following aortic valve replacement. *J Thorac Cardiovasc Surg* 1979;77:760-7.
4. Funada A, Mizuno S, Ohsato K, Murakami T, Moriuchi I, Misawa K, *et al.* Three cases of iatrogenic coronary ostial stenosis after aortic valve replacement. *Circ J* 2006;70:1312-7.
5. Winkelmann BR, Ihnken K, Beyersdorf F. Left main coronary artery stenosis after aortic valve replacement: Genetic disposition for accelerated arteriosclerosis after injury of the intact human coronary artery? *Coron Artery Dis* 1993;4:659-67.
6. Pande AK, Gosselin G. Iatrogenic left main coronary artery stenosis. *J Invasive Cardiol* 1995;7:183-7.
7. Cola C, Yuste VM, Sabaté M. Left main coronary artery stenosis following surgical valve replacement: Changing valvular into ischemic heart disease. *J Invasive Cardiol* 2009;21:E9-11.
8. Sanchez-Recalde A, Gonzaléz-Obeso E, Oliver JM. Bilateral coronary artery occlusion after aortic valve replacement in a patient with porcelain ascending aorta. *Eur Heart J* 2007;28:1553.
9. Pifarre R, Grieco J, Sullivan HJ, Scanlon PJ, Johnson SA, Gunnar RM. Coronary embolism: Surgical management. *Ann Thorac Surg* 1980;30:564-8.
10. Kinoshita K, Matsuzaki K, Mayumi H, Asou T, Masuda M, Kawachi Y, *et al.* A new aspect of coronary artery spasm induced by cardiac surgery. *Jpn J Surg* 1991;21:395-401.

**Source of Support:** Nil, **Conflict of Interest:** None declared.