

Restoration of Proximal Contacts in Decayed Primary Molars Using Three Different Matrix Systems in Children Aged 5–9 Years: An *In Vivo* Study

Murali K Dindukurthi¹, Jyothsna V Setty², Ila Srinivasan³, Anjana M Melwani⁴, Kuthpady Manasa Hegde⁵, Sreeraksha Radhakrishna⁶

ABSTRACT

Aims and objectives: Proximal contacts and their interdigitation through occlusal contact with opposing teeth play a major role in children, for the eruption of permanent teeth into normal position. Determining the ideal matrix band system for proximal restorations helps in the construction of contacts and contours. This study is designed to determine the most suitable matrix band system for proximal restorations.

Materials and methods: A total of 96 proximal cavities were selected among patients aged 5–9 years and were equally divided into three groups. Group I: T-band, group II: ProMatrix, and group III: FenderMate. Pre- and postoperative radiographs were taken to evaluate carious lesions and restorations. Class II cavity was prepared and glass ionomer restorations were done using matrix systems. The efficacy of matrix bands was evaluated through the operator's questionnaire and postoperative radiographs.

Results: No statistical significance was found between the three matrix bands but FenderMate showed few clinical drawbacks that were statistically significant ($p < 0.005$).

Interpretation and conclusion: Matrix systems used in this study showed good results in restoring proximal contacts and contours. FenderMate showed few drawbacks when compared with the other two matrix systems. None of the matrix systems used in the present study were able to create 100% accurate proximal contacts and contours.

Keywords: FenderMate, Pro-Matrix, Proximal contacts and contours, T-band.

International Journal of Clinical Pediatric Dentistry (2021): 10.5005/jp-journals-10005-1929

INTRODUCTION

Optimizing tooth form has always been a difficult task of restorative dentistry. Recreating decayed tooth structure is important not only to replace lost tooth structure but also to re-establish form and function.¹ Restoring the proper anatomy of the tooth and maintaining the health of soft tissue should be the main aim during the restorative procedure, this includes maintaining proper proximal contacts and contours.²

Ideal proximal contact prevents food impaction and thus contributes to underlying periodontal health,³ by providing food spillway and facilitating hygienic cleaning.

They also serve by maintaining dental arch stability, by distributing the force along the long axis of the teeth. Improperly restored contact area will cause displacement, lifting forces and causing rotation of teeth, deflecting occlusal contact, and food impaction.⁴

A matrix system is required for establishing proper contacts and contours.

Unfortunately, dentistry does not have a true satisfactorily manufactured matrix for restorations placed directly. Most matrices available have some good qualities but do not meet all the requisites.

T-band is one of the most commonly used matrix systems in pediatric dentistry for class II restorations. FenderMate is a pre-curved sectional matrix with an attached wedge that provides quick, safe, and predictable proximal restorations, with a tight contact and proper cervical sealing. Pro-Matrix is the new generation matrix band designed to withstand the evolving needs of dentistry.

^{1,2,4-6}Department of Pediatric and Preventive Dentistry, MR Ambedkar Dental College and Hospital, Bengaluru, Karnataka, India

³Department of Pediatric Dentistry, MR Ambedkar Dental College, Bengaluru, Karnataka, India

Corresponding Author: Murali K Dindukurthi, Department of Pediatric and Preventive Dentistry, MR Ambedkar Dental College and Hospital, Bengaluru, Karnataka, India, Phone: +91 7337809805, e-mail: mkdindukurthi@gmail.com

How to cite this article: Dindukurthi MK, Setty JV, Srinivasan I, *et al.* Restoration of Proximal Contacts in Decayed Primary Molars Using Three Different Matrix Systems in Children Aged 5–9 Years: An *In Vivo* Study. *Int J Clin Pediatr Dent* 2021;14(1):70–74.

Source of support: Nil

Conflict of interest: None

Concepts in restorative dentistry are changing. Adhesive dentistry has gradually gained importance. At present, the focus of modern operative dentistry is on the removal of minimal teeth and the application of adhesive restorative materials that mostly perform therapeutic action on demineralized dentin. Glass ionomer cements (GICs) satisfy these requirements perfectly. They are clinically attractive esthetic restorative materials and have certain unique properties that make them useful.⁵

When dealing with pediatric patients, age and behavior are factors to be considered. Collaborative behavior is needed to restore in a short period. Composite resin restorations are substituted by GICs as they are less technique-sensitive and can be placed in

only one increment when compared with composites that help in effective clinical management.⁶

Determining the ideal matrix band system for proximal restorations helps in the construction of good contacts and contours, which in turn act as natural space maintainers in children. This study was aimed to determine the most suitable matrix band system among three (T-band, Pro-Matrix, FenderMate), for constructing contacts and contours in class II restorations in mandibular primary molars restored using GIC.

MATERIALS AND METHODS (FIG. 1)

This double-blinded interventional, clinical study was conducted in the Department of Pediatric and Preventive Dentistry, MR Ambedkar Dental College and Hospital, after obtaining approval from the institutional review board and ethics committee (MRADC&H/ECIRB/0827/2016-17). Written and informed consent from the parents/guardian of the children was taken, with a video recording of the same.

A total of 96 samples were selected among patients aged 5–9 years who had class II cavities on mesial occlusal (MO) surface of second and distal occlusal (DO) surface of lower first primary molars indicated for restoration, which were carried out using T-band (Custom made), FenderMate® (FenderMate®, USA), and Pro-Matrix (Astek Innovations Ltd., UK) based on following criteria.

Inclusion Criteria

- Supragingival lesions involving marginal ridge, not extending beyond the proximal line angles and with the intact adjacent tooth.
- Patients whose parents gave written consent to be part of the study.

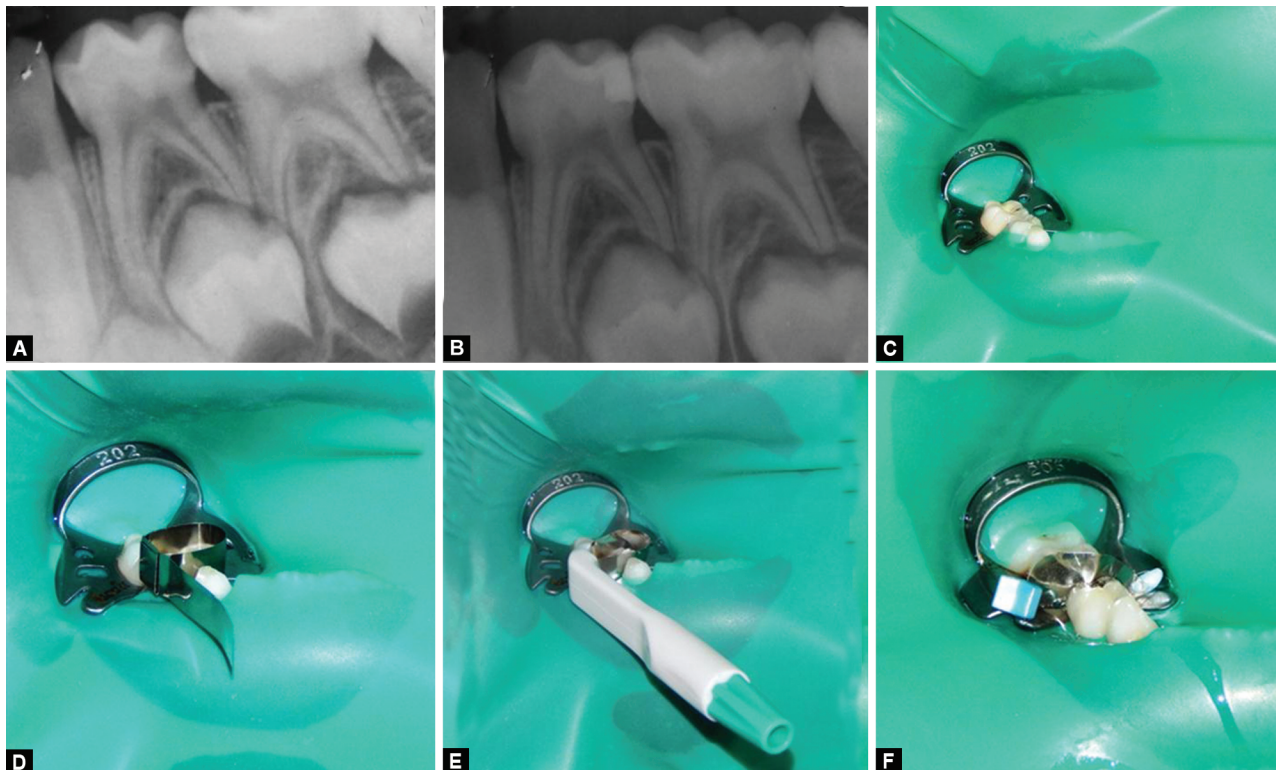
Exclusion Criteria

- Extensively damaged teeth.
- Lesions extending below gingiva, involving pulp and without an adjacent tooth.
- Teeth with pre-shedding mobility.
- Medically compromised patient.
- Patients whose parents refused to give consent.

All the procedures were done by a single operator, samples were randomly divided into three groups with 32 in each group. In group I, T-band was used for restoring proximal cavities, in group II, Pro-Matrix was used, whereas FenderMate was used in group III. Preoperative radiographs were taken to evaluate the extension of the carious lesion. Class II cavity was prepared and GIC restorations were done using different matrix systems according to the groups under rubber dam isolation. Postoperative Radiovisiography (RVG) (RVG5100CARE STREAM, KODAK) was taken to evaluate the restorations. Thyroid collar, lead apron, and all the other radiographic precautions were taken to reduce radiation exposure of children while taking radiographs.

Questionnaire (Table 1) was handed over to the operator who performed restorations, evaluated clinical aspects like ease of application and removal of matrix band, trauma to gingival tissue while application and removal of the band, and dislodgment/displacement of restoration while removing the matrix band after restoring cavities. The questionnaire used was validated by a panel of experienced pediatric dentists who were aware of the parameters used in the study. Radiographs were analyzed by two observers who were blinded with regards to bands used in the study. Radiographic evaluation was carried out according to criteria by Wilson et al.,⁷ Gomes et al.,⁸ and Khan et al.³

The data obtained were collected and tabulated, Statistical Package for Social Sciences (SPSS) for Windows, Version 22.0.



Figs 1A to F: Methodology

Table 1: Questions answered by an operator after restoring each proximal cavity in all the three groups

Q1.	Ease of application of matrix band for the prepared cavity	(A) Easy	(B) Manageable	(C) Difficult
Q2.	Ease of removal of matrix band after restoration	(A) Easy	(B) Manageable	(C) Difficult
Q3.	Trauma to gingival tissue while applying and removing matrix band for restoration	(A) Present	(B) Absent	
Q4.	Dislodgment/displacement of restoration while removing matrix band	(A) Yes	(B) No	

Table 2: Comparison of the criteria for radiographic assessment of the restorations between three study groups

Variables	Category	Group I		Group II		Group III		χ^2 value	p value
		N	%	N	%	N	%		
Shape of proximal contour	Proximal contour is correct + adequate convexity	20	62.5	21	65.6	19	59.4	5.691	0.46
	Convexity lightly compromised	7	21.9	8	25.0	7	21.9		
	Convexity moderately compromised	3	9.4	3	9.4	6	18.8		
	Contour and convexity compromised	2	6.3	0	0.0	0	0.0		
Marginal fit	Marginal fit is correct	22	68.8	22	68.8	17	53.1	2.450	0.65
	Marginal fit is likely overfilled	7	21.9	6	18.8	10	31.3		
	Marginal fit is likely underfilled	3	9.4	4	12.5	5	15.6		
Contour	Correct	24	75.0	24	75.0	20	62.5	1.613	0.81
	Undercontour	2	6.3	2	6.3	3	9.4		
	Overcontour	6	18.8	6	18.8	9	28.1		
Radiographic acceptability (contact)	Good	19	59.4	21	65.6	16	50.0	3.755	0.44
	Acceptable	12	37.5	11	34.4	16	50.0		
	Not acceptable	1	3.1	0	0.0	0	0.0		
Proximal contact	Established/contact present	31	96.9	32	100	32	100	2.021	0.36
	Open/no contact	1	3.1	0	0.0	0	0.0		
Overhanging	Absent	25	78.1	28	87.5	24	75.0	1.706	0.43
	Present	7	21.9	4	12.5	8	25.0		

Released 2013. Armonk, NY, USA: IBM Corp., was used to perform statistical analyses. The Chi-square test was used to compare the different criteria for radiographic assessment of the restoration and responses for maneuverability of matrix bands between the three groups in the study. Cohen's κ values were used for comparing interobserver variability for evaluating restorations in each group. The level of significance (p value) was set at $p < 0.05$.

RESULTS

Radiographic assessment of restorations done using different matrix bands in the study was demonstrated in Table 2 showed no statistical difference between restorations.

Operator response on the maneuverability of the matrix bands through a questionnaire related to their ease of application and removal, trauma to gingival tissue while applying to the prepared cavity, and dislodgment/displacement of restorations while removing the matrix band, showed statistical significance in all aspects (Fig. 2).

On comparison of interobserver variability between examiners, a perfect agreement was present with an evaluation of proximal contact of restorations in group I. A substantial agreement was present on evaluating proximal contours shape, marginal fit, radiographic acceptability, and overhanging of proximal restorations. Similarly, when contours were evaluated as correct/undercontour/overcontour, it showed moderate agreement.

In group II, a moderate agreement was noticed in the evaluation of proximal contours shape and radiographic acceptability.

Substantial agreement was seen in evaluating marginal fit, contours, and overhanging of restorations. A perfect agreement was seen in evaluating restored proximal contacts.

In group III, a moderate agreement was noticed in the evaluation of the shape of proximal contours and radiographic acceptability of restorations. Substantial agreement was noticed in the evaluation of marginal fit and overhanging of restorations. A perfect agreement was noticed while evaluating proximal contacts of restored teeth.

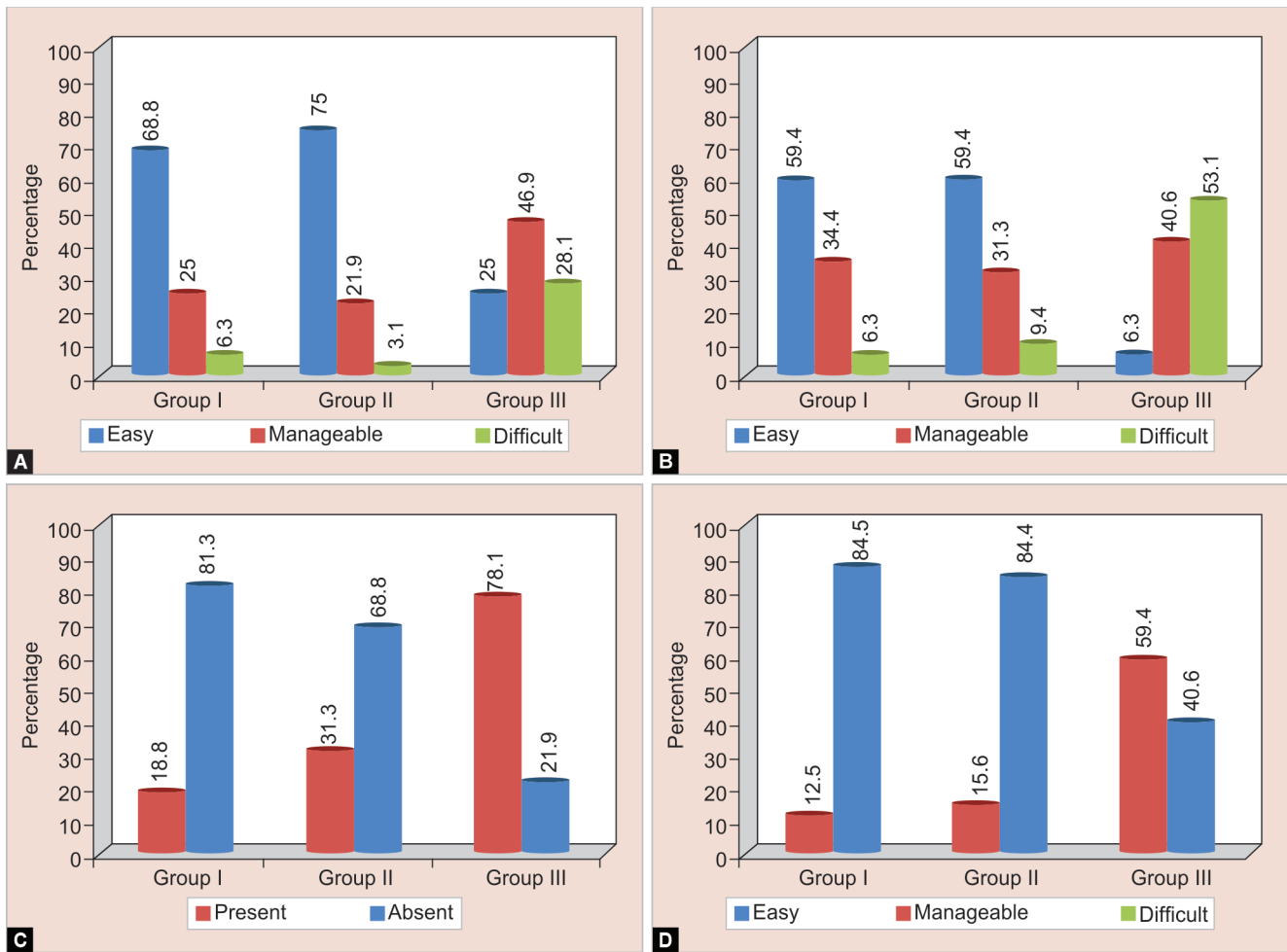
A statistically significant overall agreement was seen between both the examiners in all three groups.

DISCUSSION

A dental restoration should restore the form, function, and esthetics of a tooth and prevent the occurrence of recurrent caries and periodontal diseases.⁹ Properly constructed, firm proximal contact may protect the gingival tissues and helps in cleaning the adjoining surfaces, thereby preventing the occurrence of caries.

Improperly constructed proximal contacts may lead to gingival disease and caries. Tight proximal contact and contours with proper marginal adaptation play an important role in maintaining the integrity of the dental arch and periodontal health.⁸ Lack of tight contact and inadequately constructed contours might cause food impaction, and results in the formation of periodontal pockets.⁹

After verifying the radiographic images of restored teeth in the three groups in the present study, the majority of restorations showed properly established proximal contacts and contours



Figs 2A to D: Maneuverability of bands

with the adequate marginal fit. Though all the restored teeth did not show the same values with parameters assessed, there was no statistical difference in quality and marginal adaptation of all restorations, between the matrix systems (Table 2).

Undercontoured and overcontoured restorations may affect dental elements and surrounding structures, overcontoured restorations damage periodontium.¹⁰ On radiographically evaluating the contours of restorations, the majority of restorations were categorized as correct in all the groups. Although undercontours and overcontours were observed but did not show any statistical significance.

Open contacts are might contribute to periodontal pocket formation. The role of proximal contact in the maintenance of periodontal health and the cause of the periodontal disease has not been definitely established.² In this study, few restorations in group I showed open contacts, whereas in other groups irrespective of the shape of restored contact no open or defective contacts were seen.

Overhanging restorations are local factors which initiate, enhance, or supplement periodontal disease.¹¹ The present study showed no significant difference in overhang formation among matrix bands used. The technique of matrix band and wedge placement may affect overhanging formation than any other variable.² None of the bands used in this study were able to prevent the occurrence of incorrect proximal contours, corroborating studies found in the literature.^{2,12}

When the ease of application of matrix was investigated for performing restorations T-band and Pro-Matrix showed superior results over FenderMate. This can be attributed to the thickness of the band material and the additional application of wedge for stabilizing the band. Regarding the thickness of band material, there was no difference among the three bands used. A unique feature of FenderMate is advantageous as it minimizes time and effort for separate wedge applications. It has the drawback of making the matrix application more difficult when compared with other bands. This can also be attributed to the presence of tight contacts between primary molars,¹³⁻¹⁶ which made it difficult for placing band and wedge together.

T-band and Pro-Matrix were easy to remove when compared with FenderMate. This may be due to the same reason which made the application of FenderMate difficult.

FenderMate was traumatic to gingival tissue during application and removal of matrix band compared with the other two bands. This may be due to short cervico-occlusal crown length in primary teeth which play role in placing matrix band. In the case of T-band and Pro-Matrix, the depth of placement of matrix band and wedge can be adjusted according to crown height. However, while applying FenderMate, this was not possible as both matrix band and wedge are together. In this case, band and wedge might be impinging into gingival tissue which leads to more trauma. Shape, position, and degree of keratinization of interdental gingiva also

might be the reason for trauma while placing the matrix band when compared with adult gingiva which is more keratinized.

Use of FenderMate showed more displacement/dislodgment of restorations while removing the band compared with others. This may be due to a notch in the matrix system which helps in creating contour while restoring proximal cavities. Both T-band and Pro-Matrix were plain without a notch, which may be the reason for less displacement/dislodgment of restorations while using them.

The interobserver evaluation showed substantial agreement in the majority of the observations among the groups. According to Loomans et al., the restoration of class II cavities tends to alter the original proximal contact due to tooth extractions, mesiodistal tooth movements under forces produced by the progressive eruption of molars, or unbalanced occlusal forces.¹⁷

Thus, it is extremely important to establish proper proximal contact and contour in preventing this untoward effect.

CONCLUSION

All the three bands used in our study established proximal contact with adjacent teeth. T-band and Pro-Matrix showed slightly superior results in creating proper proximal contacts and contours, establishing proper marginal fit over FenderMate. Pro-matrix showed superior results than the other two bands in creating radiographically acceptable proximal contacts with fewer overhangings. T-band and Pro-Matrix were easy to apply and remove with minimal trauma to gingival tissue. More dislodgment/displacement of restorations was noticed with the use of FenderMate during band removal.

Matrix systems used in the study showed good results in restoring proximal contacts and contours. However, FenderMate showed few drawbacks when compared with other systems. Though the majority of proximal restorations done using matrix bands in this study were evaluated as correct by both the examiners, none of the matrix systems used were able to create 100% accurate contacts and contours.

REFERENCES

- Ramya R, Raghu S. Optimizing tooth form with direct posterior composite restorations. *J Conserv Dent* 2011;14(4):330–336. DOI: 10.4103/0972-0707.87192.
- Chuang SF, Su KC, Wang CH, et al. Morphological analysis of proximal contacts in class II direct restorations with 3D image reconstruction. *J Dent* 2011;39(6):448–456. DOI: 10.1016/j.jdent.2011.04.001.
- Khan FR, Umer F, Rahman M. Comparison of proximal contact and contours of premolars restored with composite restoration using circumferential matrix band with and without separation ring: a randomized clinical trial. *Int J Prosthodont Restor Dent* 2013;3(1):7–13. DOI: 10.5005/jp-journals-10019-1068.
- Shivakumar AT, Kalgeri SH, Dhir S. Clinical considerations in restorative dentistry - a narrative review. *J Int Clin Dent Res Organ* 2015;7(2):122–129. DOI: 10.4103/2231-0754.164377.
- Gurgan S, Kutuk ZB, Ergin E, et al. Four-year randomized clinical trial to evaluate the clinical performance of a glass ionomer restorative system. *Oper Dent* 2015;40(2):134–143. DOI: 10.2341/13-239-C.
- Casagrande L, Dalpian DM, Ardenghi TM, et al. Randomized clinical trial of adhesive restorations in primary molars 18-month results. *Am J Dent* 2013;26(6):351–355.
- Wilson MA, Cowan AJ, Randall RC, et al. A practice-based, randomized, controlled clinical trial of a new resin composite restorative: one-year results. *Oper Dent* 2002;27(5):423–429.
- Gomes IA, Mariz DC, Borges AH, et al. In vivo evaluation of proximal resin composite restorations performed using three different matrix systems. *J Contemp Dent Pract* 2015;16(8):643–647. DOI: 10.5005/jp-journals-10024-1735.
- Hancock EB, Mayo CV, Schwab RR, et al. Influence of interdental contacts on periodontal status. *J Periodontol* 1980;51(8):445–449. DOI: 10.1902/jop.1980.51.8.445.
- Jansson L, Ehnevid H, Lindskog S, et al. Proximal restorations and periodontal status. *J Clin Periodontol* 1994;21(9):577–582. DOI: 10.1111/j.1600-051x.1994.tb00746.x.
- Gilmore N, Sheiham A. Overhanging dental restorations and periodontal disease. *J Periodontol* 1971;42(1):8–12. DOI: 10.1902/jop.1971.42.1.8.
- Kampouropoulos D, Paximada C, Loukidis M, et al. The influence of matrix type on the proximal contact in Class II resin composite restorations. *Oper Dent* 2010;35(4):454–462. DOI: 10.2341/09-272-L.
- Allison PJ, Schwartz S. Interproximal contact points and proximal caries in posterior primary teeth. *Pediatr Dent* 2003;25(4):334–340.
- Marquezan M, Marquezan M, Faraco-Junior IM, et al. Association between occlusal anomalies and dental caries in 3 to 5-year-old Brazilian children. *J Orthod* 2011;38(1):8–14. DOI: 10.1179/146531211141191.
- Novaes TF, Matos R, Braga MM, et al. Performance of a pen-type laser fluorescence device and conventional methods in detecting approximal caries lesions in primary teeth—in vivo study. *Caries Res* 2009;43(1):36–42. DOI: 10.1159/000189705.
- Novaes TF, Matos R, Celiberti P, et al. The influence of interdental spacing on the detection of proximal caries lesions in primary teeth. *Braz Oral Res* 2012;26(4):293–299. DOI: 10.1590/s1806-83242012000400002.
- Loomans BA, Opdam NJ, Roeters FJ, et al. A randomized clinical trial on proximal contacts of posterior composites. *J Dent* 2006;34(4):292–297. DOI: 10.1016/j.jdent.2005.07.008.