

## Case Report

### Adenoid cystic carcinoma of the mobile tongue: A rare case

Pavitra Baskaran<sup>1</sup>, R Mithra<sup>1</sup>, M Sathyakumar<sup>2</sup>, Satyaranjan Misra<sup>3</sup>

<sup>1</sup>Department of Oral Medicine and Radiology, <sup>2</sup>Department of Oral and Maxillofacial Pathology, SRM Kattankulathur Dental College, Potheri, Kanchipuram District, Tamil Nadu, <sup>3</sup>Department of Oral Medicine and Radiology, SCB Dental College and Hospital, Cuttack, Odisha, India

#### ABSTRACT

Adenoid cystic carcinoma (ACC) occurs more commonly in the minor salivary glands of the palate than the tongue. ACC is a malignant neoplasm that accounts for 1-2% of all head and neck malignancies and 10-15% of all salivary gland malignancies. ACC affects the exocrine glands at any site, but the parotid gland is the most common site in the head and neck region. Many factors should be taken into account in the prognosis of ACC, including the histological and clinical stages of the disease. The most striking feature of ACC is that it is locally aggressive, with a high recurrence level, perineural invasion and distant metastases, especially to the lungs and bones. The most common presentation histologically is the presence of cribriform appearance (Swiss cheese pattern). The present case is a rare one present on the tongue.

**Key Words:** Adenoid cystic carcinoma, cribriform pattern, perineural invasion

Received: January 2012  
Accepted: June 2012

Address for correspondence:  
Dr. Pavitra Baskaran,  
Department of Oral  
Medicine and Radiology,  
SRM Kattankulathur  
Dental College, Potheri,  
Kanchipuram District, Tamil  
Nadu, India.  
E-mail: pavitra\_omed@  
yahoo.in

#### INTRODUCTION

Adenoid cystic carcinoma (ACC) was first described by Robin, Lorian and Laboulbene in two of their articles published in 1853 and 1854, in which the cylindrical appearance of the tumor was discussed. Billroth in 1859 has described the tumor as cylindroma and has also explained its great recurrent tendency. Spies in 1930 gave the name "adenoid cystic carcinoma" in his discussion of cutaneous and non-cutaneous tumors of the basal cell type.<sup>[1]</sup>

ACC originates in both the minor and the major salivary glands. It is an infrequent lesion and represents approximately 1-2% of all malignant neoplasms of the head and neck, and up to 10-15% of all malignant salivary gland neoplasms. The most common intraoral site for minor salivary gland tumors is the hard palate, followed by the base of the tongue,

where up to 96% of all tumors are malignant, and ACC represents 30% of them.<sup>[2]</sup>

ACC progresses slowly with wide perineural invasion into the adjacent nerves, suggesting the presence of strong neurotropism for the tumor.<sup>[2,3]</sup> Perineural invasion occurs through the perineural spaces, or within the nerve itself.<sup>[2]</sup> Lymphatic spread is rare; however, there may be incidents of hematogenous dissemination of the tumor. Distant metastases can occur to the lungs and bones.<sup>[1]</sup>

The presentation rate of ACC in the base of the tongue is 8.8% and that of the mobile tongue is only 2.9% of the cases.<sup>[2]</sup> Hereby, we present a case of ACC of mobile tongue in a middle-aged female patient.

#### CASE REPORT

A 36-year-old female patient had complained of a swelling in the right side of the tongue since 1 month, which had started spontaneously and then showed a rapid increase in size. The patient developed a dull and intermittent pain 2 days after the swelling had started. She had difficulty with speech and swallowing. Extra-orally, a single submandibular lymph node on the right side was palpable, tender, soft in consistency and freely movable. Intra-oral examination revealed a

Access this article online



Website: [www.drj.ir](http://www.drj.ir)

diffuse swelling on the right side involving the dorsum, right lateral border [Figure 1] and ventral surface of the tongue [Figure 2]. It extended from the tip of the tongue to 1 cm beyond the anterior two-thirds. Medially, it crossed the midline by 2 cm. The overlying mucosa was normal and the surface of the swelling was smooth; margins were ill-defined. There were no ulcerations or sinus openings. On palpation, the swelling was tender and firm in consistency and moved along with the tongue movements.

A provisional diagnosis of malignant soft tissue neoplasm from the muscles of the tongue or minor salivary glands was made.

Magnetic resonance imaging (MRI) neck plain revealed a well-defined T1 hypo-STIR [Figure 3] hyperintense lesion involving the anterior half of the tongue with displacement of the intrinsic muscles superiorly and to the left side. The lesion showed small GRE/T2 [Figure 4] hypointense foci within the lesion.

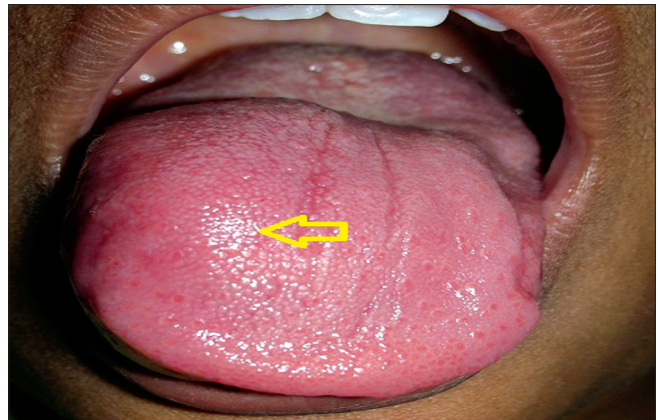Excision biopsy was done under general anesthesia and the histopathological findings revealed isomorphic basaloid tumor cells with a cribriform pattern and numerous cystic spaces [Figure 5]. There was compressed dense connective tissue in the periphery that was infiltrated by tumor islands. Few areas showed perineural invasion. Correlating the clinical, MRI and histopathological findings, a final diagnosis of adenoid cystic carcinoma of mobile tongue was made.

## DISCUSSION

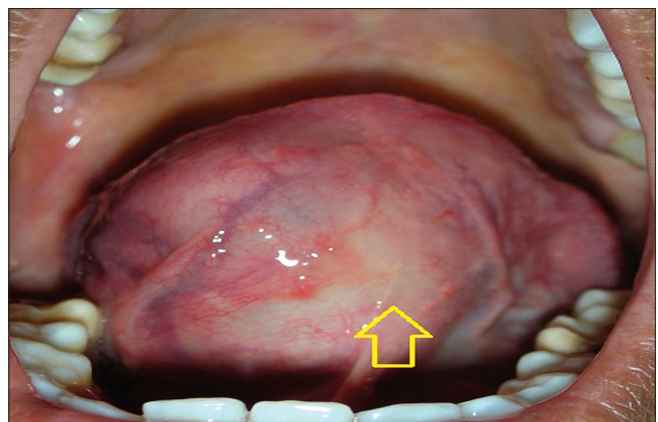
The WHO definition of ACC is, “A basaloid tumor consisting of epithelial and myoepithelial cells in various morphological configurations including tubular, cribriform and solid patterns. It has a relentless clinical course and, usually, a fatal outcome.”<sup>[3]</sup>

ACC predominantly occurs in women and has a peak incidence in the fifth and sixth decades of life.<sup>[3]</sup> Our case agrees with one of the above observations that it is seen in the women population, but it occurred in a 36-year-old female.

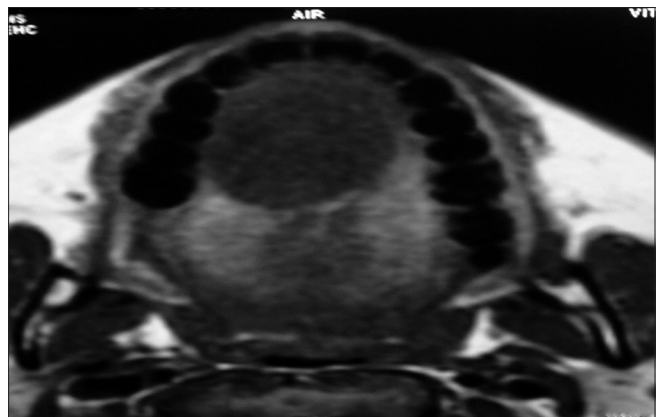
The clinical course for an ACC of the tongue is painless, slow submucosal growth of the tumor, which hinders its early diagnosis. According to the previous studies, the time elapsed from the first clinical appearance until the presence of symptoms ranges from 2.5 to 7 years,<sup>[4]</sup> with one case reported by Luna Ortiz *et al.* that had a duration of 10 months.<sup>[5]</sup> In our



**Figure 1:** Intraoral view revealing a diffuse swelling in the dorsal aspect of the anterior region of the tongue



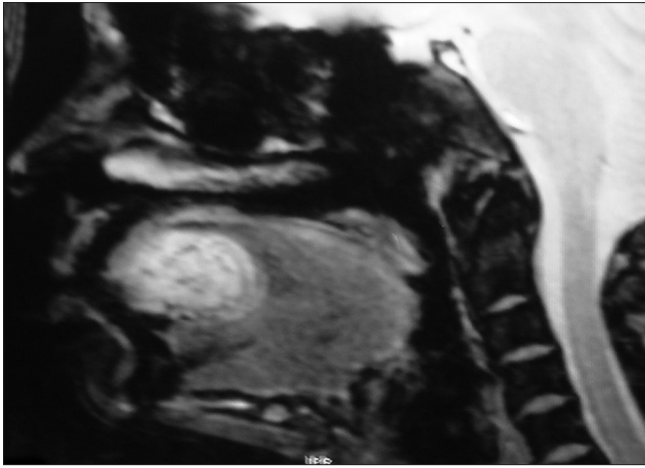
**Figure 2:** Intraoral view revealing a diffuse swelling in the ventral aspect of the anterior region of the tongue



**Figure 3:** Magnetic resonance imaging of the axial section shows a hypointense STIR-weighted image

case, the patient had developed a rapid increase in the size of the swelling within the duration of 1 month, and it was symptomatic.

Imaging modalities were performed in order to elicit the deep-seated lesions. MRI has higher accuracy in



**Figure 4:** Magnetic resonance imaging sagittal section shows T2-weighted image

identifying the soft tissue lesion. In our case, the MRI finding was that of hyperintense STIR-weighted image with T2 hypointense foci suggesting the presence of the tumor.

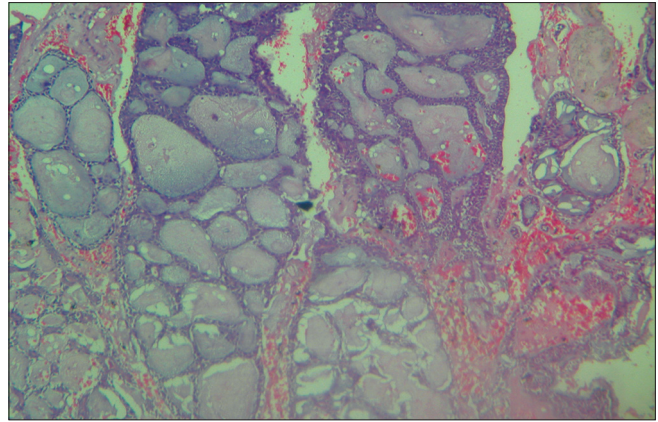
Previous studies by Arijji *et al.*<sup>[6]</sup> and Ginsberg *et al.*<sup>[7]</sup> have shown the perineural spread by MRI. Konyuncyu *et al.*<sup>[8]</sup> had revealed that MRI provides information for pre-surgical planning and diagnosis. However, in our case, the hyperintense T1-weighted image and GRE T2 hypointense foci suggested the presence of tumor with involvement of the adjacent nerve bundle. This allowed a pre-surgical planning, which was further confirmed as ACC by microscopy.

Histologically, ACC has three different variables - cribriform, tubular and solid, which have the worst prognosis due to the presence of increased mitotic figures. It also has a strong neurotrophism involving the nerves adjacent to the lesion.<sup>[3]</sup> Our case showed cribriform pattern and perineural invasion based on which the management of the tumor was planned.

The relationship between the histological pattern and the prognosis was suggested by Soares *et al.*<sup>[3]</sup> The Batsakis<sup>[9]</sup> survival rate was less in the solid pattern when compared with the cribriform and tubular patterns.

The treatment is usually surgical excision of the tumor with adjuvant radiotherapy in patients with advanced T stage and/or positive surgical margins.<sup>[10]</sup>

Only 2.9% of the cases have been reported in the minor salivary glands of mobile tongue. ACC from the minor salivary glands is usually at the advanced stage at the time of diagnosis. Hence, it is essential to record the lesion from the minor salivary glands from



**Figure 5:** Histopathological picture reveals a cribriform pattern with ductal structures

the tongue as the incidence of their occurrence is very less when compared with other sites.<sup>[1]</sup>

Patients with a lingual ACC have defective function. Hence, the treatment should aim at procedures to improve the speech and swallowing, which will improve the quality of life for the patient.

## CONCLUSION

Tongue lesions remain challenging for diagnosis and surgical treatment because of their anatomical location and their association with blood vessels and nerves. Only few cases of ACC of mobile tongue have been reported in the literature thus making this case a rare one. The histopathological pattern and the presence or absence of distant metastases helps dictate the prognosis and survival of the patient.

## REFERENCES

1. Shankar NV, Prakash SM, Sumalatha MN, Shankar A. Adenoid cystic carcinoma of the tongue. *Int J Acad Res* 2011;3:580-3.
2. Luna-Ortiz K, Carmona-Luna T, Cano-Valdez AM, Mosqueda-Taylor A, Herrera-Gómez A, Villavicencio-Valencia VV. Adenoid cystic carcinoma of the tongue: clinicopathologic study and survival analysis. *Head Neck Oncol* 2009;1:15.
3. Soares EC, Carriro Filho FP, Costa FW, Viera AC, Alves AP. Adenoid cystic carcinoma of the tongue: Case report and literature review. *Med Oral Patol Oral Cir Bucal* 2008;13:E475-8.
4. Carrasco Ortiz D, Aldape Barrios B. Adenoid cystic carcinoma of the dorsum of the tongue: Presentation of a case. *Med Oral Patol Oral Cir Bucal* 2006;11:E417-20.
5. Luna Ortiz K, Carmona Luna T, Herrera Gómez A, Cano Valdez AM. Macroglossia caused by adenoid cystic carcinoma. Case report. *Med Oral Patol Oral Cir Bucal* 2008;13:E395-7.
6. Arijji Y, Fuwa M, Toyoma N, Katoh M, Gotoh M, Arijji E. MR features of masticatory muscles in adenoid cystic carcinoma

- involving the masticator space. *Dentomaxillofac Radiol* 2004;33:345-50.
- Ginsberg LE, DeMonte F. Imaging of perineural tumor spread from palatal carcinoma. *AJNR Am J Neuroradiol* 1998;19:1417-22.
  - Koyuncu M, Seşen T, Akan H, Ismailoglu AA, Tanyeri Y, Tekat A, *et al.* Comparison of computed tomography and magnetic resonance imaging in the diagnosis of parotid tumors. *Otolaryngol Head Neck Surg* 2003;129:726-32.
  - Batsakis JG, Luna MA, el-Naggar A. Histopathologic grading of salivary gland neoplasms: III. Adenoid cystic carcinomas. *Ann Otol Rhinol Laryngol* 1990;99:1007-9.
  - Silverman DA, Carlson TP, Khuntia D, Bergstrom RT, Saxton J, Esclamado RM. Role for postoperative radiation therapy in adenoid cystic carcinoma of head and neck. *Laryngoscope* 2004;114:1194-9.

**How to cite this article:** Baskaran P, Mithra R, Sathyakumar M, Misra S. Adenoid cystic carcinoma of the mobile tongue: A rare case. *Dent Res J* 2012;9:115-8.

**Source of Support:** Nil. **Conflict of Interest:** None declared.

#### Announcement

##### iPhone App



Download  
iPhone, iPad  
application

FREE

A free application to browse and search the journal's content is now available for iPhone/iPad. The application provides "Table of Contents" of the latest issues, which are stored on the device for future offline browsing. Internet connection is required to access the back issues and search facility. The application is Compatible with iPhone, iPod touch, and iPad and Requires iOS 3.1 or later. The application can be downloaded from <http://itunes.apple.com/us/app/medknow-journals/id458064375?ls=1&mt=8>. For suggestions and comments do write back to us.