

Simultaneous Discovery of Cranial and Spinal Intradural Chordomas: Case Report

Yoshifumi KAWANABE,¹ Shigeo UEDA,¹ Nobuhiro SASAKI,¹
and Minoru HOSHIMARU¹

¹Department of Neurosurgery, Otsu Municipal Hospital, Otsu, Shiga

Abstract

The present case illustrates the unexpected occurrence of intradural chordomas that were simultaneously discovered in cranial and spinal locations. A 63-year-old female presented with weakness in the left upper extremity. The patient visited a local doctor and underwent brain computerized tomography (CT). CT revealed a brain tumor, and she was referred to our hospital. Brain magnetic resonance imaging (MRI) demonstrated a midline intradural retroclival tumor in addition to an intradural extramedullary mass lesion at the level of C1–C2. The patient developed a spastic gait disturbance that forced her to use a cane. She underwent laminectomy at C1–C2 along with total removal of the tumor and showed no remarkable symptoms after surgery. Histopathological examination confirmed the diagnosis of chordoma. One month after the cervical surgery, the intracranial tumor was subtotally removed in intracranial surgery via the right subtemporal approach. Histopathological data were identical to that of the cervical tumor. The patient consulted another hospital and underwent gamma-knife surgery. Her neurological examination is relatively unchanged 20 months after the cervical surgery. This case suggests that neuroradiological evaluation should also be performed for an intradural spinal chordoma when an intracranial chordoma is detected. Careful determination of the tumor responsible for the symptoms is necessary if an intradural spinal chordoma is simultaneously detected with an intracranial chordoma.

Key words: intracranial chordoma, intradural spinal chordoma, spinal seeding

Introduction

Chordoma is rare and generally characterized as a slow-growing malignant neoplasm of presumed notochordal origin.¹⁾ Approximately 50% chordomas originate in the sacrococcygeal area, 35% in the spheno-occipital region, and the remaining 15% in other parts of the vertebral column.²⁾ Chordomas are considered locally aggressive, with high recurrence rate and relatively low metastasis rate.³⁾ However, the metastasis rate is greater than that was previously believed, and this may be related to the long clinical history of chordomas.^{2,4–8)} The lungs and lymph nodes are the most common sites of metastasis, followed by the liver and the bone. However, spinal seeding from a skull base chordoma is very rare. Only nine cases of drop metastases have been reported to date (Table 1).^{2,6,9–15)} In addition, in these cases, spinal seeding occurred during the follow-up period after surgical and irradiation therapies of intracranial chordoma. Intradural chordoma is extremely rare and associated with a better

prognosis compared with that of typical chordoma.¹⁶⁾ To the best of our knowledge, only 27 intracranial chordoma cases and 4 spinal chordoma cases have been reported to date.¹⁷⁾ Here we report an unusual case of the simultaneous discovery of intradural cranial and spinal chordomas.

Case Report

A 63-year-old female visited a local doctor complaining of left upper limb weakness for two weeks. Because brain computerized tomography (CT) revealed brain tumor, she was referred to our hospital. Neurological examinations revealed the following: (1) weakness of manual muscle testing (MMT) with Grade 4/5 on both upper extremities, (2) numbness of both upper extremities, and (3) hyper-reflexia of the lower extremities. However, the patient displayed no remarkable cranial nerve disturbances. Brain magnetic resonance imaging (MRI) revealed a midline clival tumor, appearing as hypointense on T₁-weighted images and hyperintense on T₂-weighted images. T₁-weighted MRI with gadolinium revealed homogenous enhancement of the lesion that displaced the brain stem posteriorly (Fig. 1A, B).

No remarkable perifocal edema was detected on T₂-weighted images (Fig. 1C). In addition, brain MRI detected a mass lesion at the level of C1–C2. Cervical MRI demonstrated an intradural extramedullary mass lesion at the level of C1–C2, appearing as isointense on T₁-weighted images and hyperintense on T₂-weighted images (Fig. 2A, B). T₁-weighted MRI with gadolinium revealed homogenous enhancement of the lesion (Fig. 2C, D). Further, thoracic and lumbar MRI revealed small asymptomatic multiple mass lesions (Fig. 2E–G). No metastasis was detected in other organs. The patient developed increased weakness of MMT with Grades 2/5 and 3/5 on the upper and lower extremities, respectively, in addition to the spastic gait disturbance that forced her to use a cane one week after the admission. The patient underwent laminectomy at C1–C2 along with total removal of the tumor (Fig. 3). During surgery, the mass was entirely

intradural: it invaded the subarachnoid membrane and touched the dura mater. There was no evidence indicating that the mass originated from the dura mater: the tumor was clearly distinguished from the spinal cord and was easily removed. A postoperative MRI demonstrated a total removal of the tumor (Fig. 4). Histopathological examination confirmed the diagnosis of a chordoma, and the Ki-67 labeling index was 3.5% (Fig. 5). Immunohistochemistry indicated the tumor to be positive for epithelial membrane antigen (EMA), cytokeratin AE1/AE3, vimentin, and S-100, and negative for GFAP. The patient revealed no remarkable symptoms after surgery and was self-sufficient. One month after the cervical surgery, the intracranial tumor was subtotally removed in a surgery via the right subtemporal approach (Fig. 6). The soft, friable, grayish mass was intradullary and was compressing the brain stem. There was no evidence demonstrating that the mass originated

Table 1 Cases of the spinal dissemination during the treatment of the intracranial chordoma: a literature review

Author/Year	Age (years)	Gender	Primary lesion	Spinal lesion	Period until spinal dissemination was recognized
Stough et al. (1971) ¹³	41	M	Petrous ridge	Th12-L1	5 years
Raffel et al. (1985) ⁶	40	M	Clivus	C4-Th2	7 months
Krol et al. (1989) ¹²	41	M	Clivus	Cervical, L2-4	1 year
Forsyth et al. (1993) ¹⁰	Unknown	Unknown	Clivus	C7-Th1	Unknown
Korinth et al. (1999) ¹¹	48	F	Cerebellopontine angle	Thoracolumbar	10 months
Uggowitz et al. (1999) ¹⁵	22	M	Clivus	C5-7	3 years
Asano et al. (2003) ⁹	53	M	Clivus	Th4,8,9, and lumbosacral	11 years
Tsuboi et al. (2007) ¹⁴	54	F	Clivus	Multiple	5 years
Martin et al. (2009) ²	69	M	Clivus	L4/5	12 years

F: female, M: male.

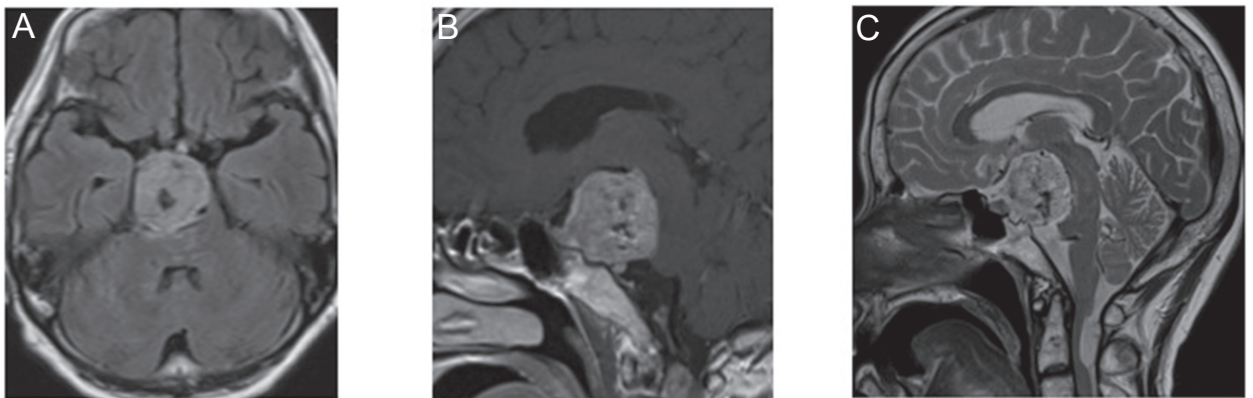


Fig. 1 A: Preoperative T₁-weighted axial magnetic resonance imaging (MRI) with gadolinium reveals homogenous enhancement of the midline clival lesion. B: Preoperative T₁-weighted sagittal MRI with gadolinium shows the lesion bending the brain stem. C: Preoperative T₂-weighted axial MRI demonstrates no remarkable perifocal edema.

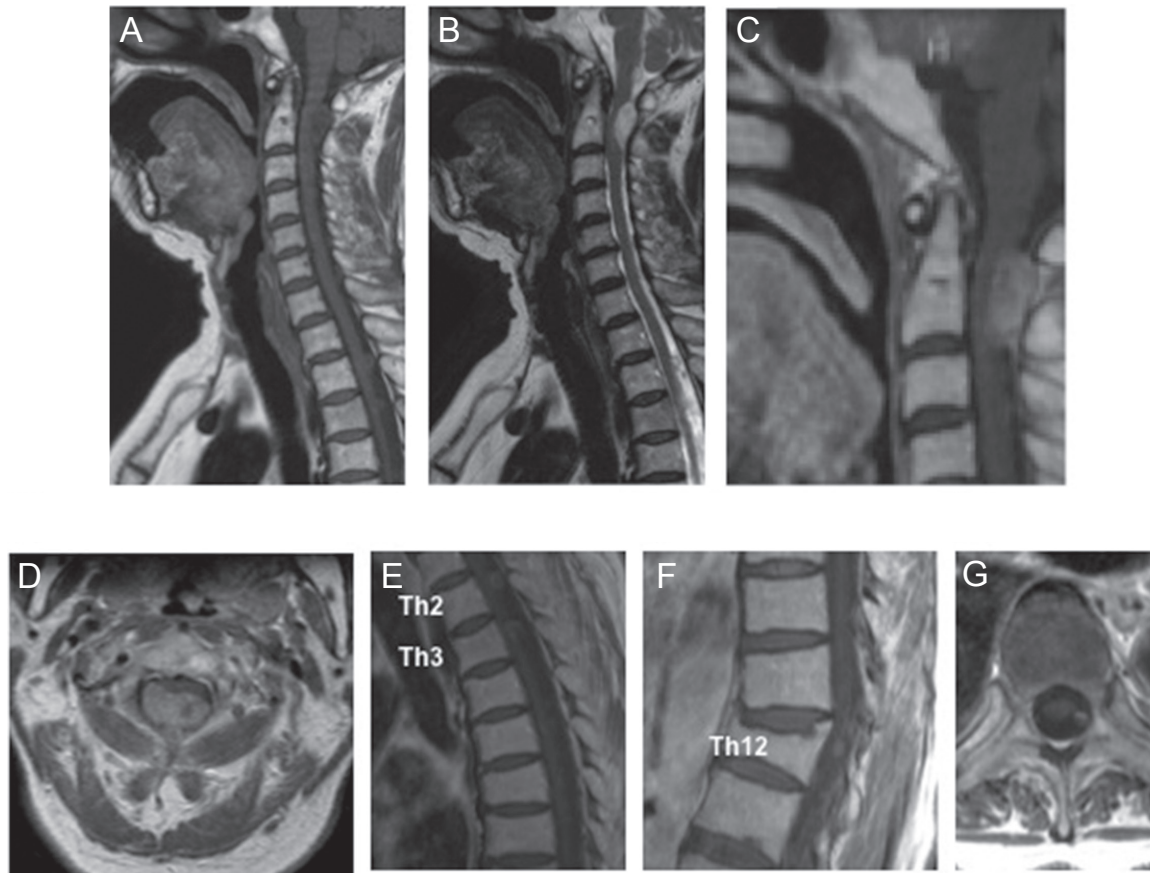


Fig. 2 A: Preoperative T₁-weighted sagittal magnetic resonance imaging (MRI) shows an isointense lesion at C1/C2 level. B: Preoperative T₂-weighted sagittal MRI shows a hyperintense lesion at C1/C2 level. C: Preoperative T₁-weighted sagittal MRI with gadolinium reveals homogenous enhancement of the lesion. D: Preoperative T₁-weighted axial MRI with gadolinium demonstrates an intradural extramedullary lesion that displaced the spinal cord anteriorly. E: T₁-weighted sagittal MRI shows isointense lesions at Th2 and Th3 levels. F: T₁-weighted sagittal MRI shows an isointense lesion at Th12 level. G: T₁-weighted axial MRI demonstrates an intradural extramedullary lesion at Th2 level.

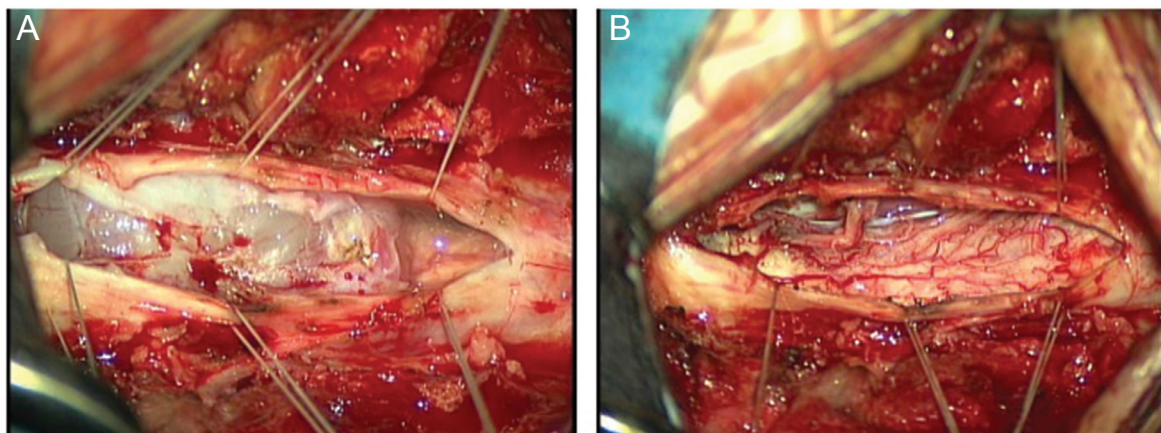


Fig. 3 A: Intraoperative photograph demonstrates an intradural extramedullary tumor. C1-2 laminectomy is performed. The mass lesion compresses spinal cord. The mass was totally intradural and not to arise from the dura matter. B: The tumor is totally extirpated.

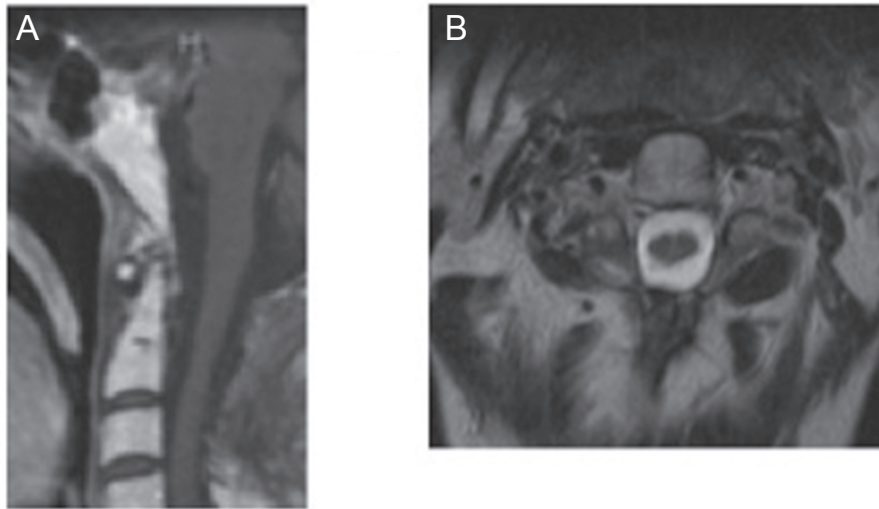


Fig. 4 A, B: Postoperative T₁-weighted sagittal (A) and axial (B) magnetic resonance imaging (MRI) with gadolinium reveal no enhanced mass lesion. Axial MRI also shows no spinal cord compression.

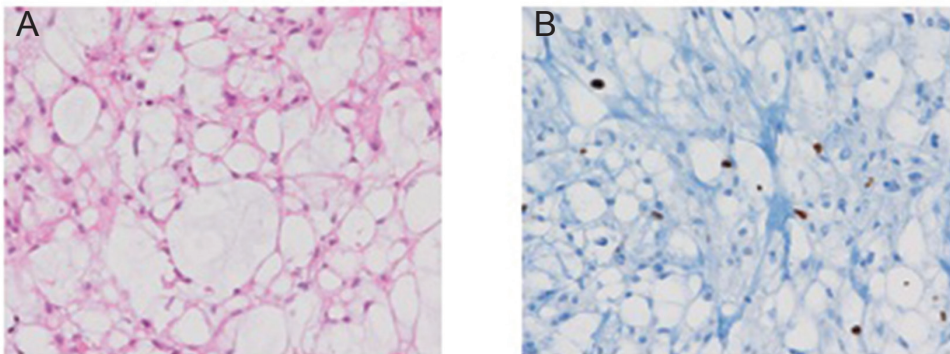


Fig. 5 A, B: Photomicrograph of the spinal tumor consists of sheets of physaliphorous cells (A, $\times 20$, hematoxylin eosin stain) and the Ki-67 labelling index was 3.5%. B: The histological diagnosis is chordoma.

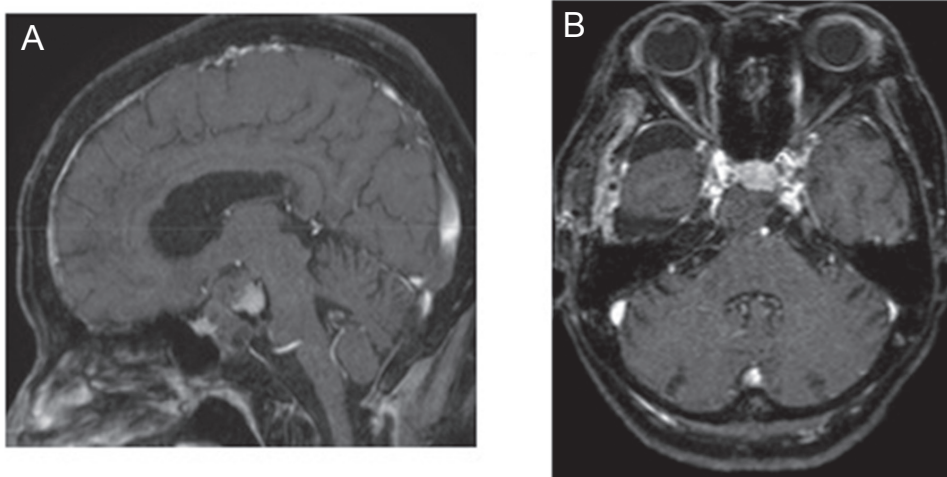


Fig. 6 A, B: Postoperative T₁-weighted sagittal (A) and axial (B) magnetic resonance imaging (MRI) with gadolinium reveal no enhanced mass lesion. The intracranial tumor was subtotally removed.

from the clival bone marrow and clival dura mater. A small area of the tumor surface was attached to the dura mater, but the dura was not destroyed. The mass invaded from outside of the arachnoid membrane and enlarged the subarachnoid space. The mass was attached to the right VI nerve: after surgery, the patient suffered right VI nerve palsy. However, postoperative motor and sensory

conditions of the upper and lower extremities were the same as those before surgery. Histopathological data were identical to the cervical tumor. The patient consulted another hospital and underwent gamma knife surgery including the clival region. The maximum core dose was 26 Gy, and the peripheral dose was 13 Gy. However, heavy iron radiotherapy was not performed because of spinal

dissemination. The patient's neurological examination is relatively unchanged 20 months after the cervical surgery.

Discussion

Because the long-term local control of skull base chordomas appear to be improving by the introduction of skull base surgical techniques and adjuvant radiotherapy, spinal intradural seeding may emerge as a potential complication. Careful and close observation and timely imaging studies focusing on spinal seeding of skull base chordoma would be required in long-term postoperative follow-up. Both cranial and cervical chordomas were intradural in this case: this could be confirmed on the basis of the intraoperative observation that both the tumors were completely located within the intradural space. Intradural chordomas are very rare tumors and less aggressive compared with those of an osseous origin.¹⁶⁾ In another study, ectopic notochord tissue was detected in an intradural location anterior to the pons in 2% of all autopsies¹⁸⁾: this phenomenon has been termed "ecchordosis physaliphora" and may be the precursor to intradural prepontine chordoma. Our case may be judged as an intradural cranial chordoma with intradural spinal seeding for the following reasons: (1) an intracranial chordoma is larger than a cervical one, (2) a cervical chordoma is completely intradural and does not originate from the dura mater, and (3) in our case, thoracic and lumbar MRIs revealed small asymptomatic multiple mass lesions. An explanation for the mechanism of spinal seeding is detachment of tumor cells and their seeding to the lower parts of the spinal leptomeninges (drop metastases) such as the case in medulloblastomas. Judging from the intracranial MRI images of previous^{2,9,11,14)} and our cases, extension into the cerebellopontine region and encroachment into the brain stem of the chordoma may be important causes of the occurrence of spinal metastasis. Few reports indicate that the faster growth rate of chordoma is associated with a Ki-67 labeling index of more than 6%.^{9,19)} However, in this case, the Ki-67 labeling index was 3.5%. Therefore, MRI screening for spinal metastasis should be performed even in a clival chordoma with a Ki-67 labeling index lower than 6%.

Drop metastasis from intracranial origin to spinal regions usually occurs late in the course of a cranial chordoma and after multiple surgical and radiation therapies.^{2,6,9-15)} Tumor seeding during surgery is one of the predisposing factors to spinal seeding.^{2,5,6,9,11)} However, none of the previous cases could confirm that the spinal seedings occurred for intracranial lesions after surgery due to the lack of spinal MRI at that time. Nevertheless, on the basis of the fact that intracranial and spinal chordomas are simultaneously recognized, this is the first case indicating the possibility of spinal seeding without being affected by the surgical procedure. It may be difficult to determine the tumor

responsible for the symptoms if intradural spinal seeding is simultaneously detected with the intracranial chordoma, particularly in cases where the intradural spinal seeding and intracranial chordoma compress the spinal cord and brain stem, respectively. This case involved the initial removal of a cervical tumor because of the following reasons: (1) no remarkable perifocal edema was detected around the brain stem on T₂-weighted MRI images, (2) cervical MRI detected severe spinal cord compression caused by an intradural extramedullary mass lesion at the level of C1–C2, (3) neurological symptoms markedly increased in a short period, and (4) no cranial nerve disturbances were observed. The decision was confirmed with the result that all the neurological disturbances disappeared after removal of the cervical tumor. Therefore, this case may be the first case of an intracranial chordoma, which was detected because of the symptoms caused by cervical intradural spinal seeding. In this case, there was a possibility that removal of the intracranial tumor would have been performed without cervical MRI if we had failed to notice a cervical mass lesion at the bottom of the brain MRI. Conversely, removal of the cervical tumor may have been performed without checking for brain lesions if initial cervical MRI had been performed. This case suggests that neuroradiological evaluation of spinal seeding should be performed when an intracranial chordoma is detected. In addition, careful determination of the tumor responsible for the symptoms is necessary if intradural spinal seeding is simultaneously detected with a clival chordoma.

Conflicts of Interest Disclosure

The authors have no conflicts of interest to report.

References

- 1) Peña CE, Horvat BL, Fisher ER: The ultrastructure of chordoma. *Am J Clin Pathol* 53: 544–551, 1970
- 2) Martin MP, Olson S: Intradural drop metastasis of a clival chordoma. *J Clin Neurosci* 16: 1105–1107, 2009
- 3) Wang CC, James AE: Chordoma: brief review of the literature and report of a case with widespread metastases. *Cancer* 22: 162–167, 1968
- 4) Chambers PW, Schwinn CP: Chordoma. A clinicopathologic study of metastasis. *Am J Clin Pathol* 72: 765–776, 1979
- 5) Higinbotham NL, Phillips RF, Farr HW, Hustu HO: Chordoma. Thirty-five-year study at Memorial Hospital. *Cancer* 20: 1841–1850, 1967
- 6) Raffel C, Wright DC, Gutin PH, Wilson CB: Cranial chordomas: clinical presentation and results of operative and radiation therapy in twenty-six patients. *Neurosurgery* 17: 703–710, 1985
- 7) Tomlinson FH, Scheithauer BW, Forysthe PA, Unni KK, Meyer FB: Sacromatous transformation in cranial chordoma. *Neurosurgery* 31: 13–18, 1982
- 8) Volpe R, Mazabraud A: A clinicopathologic review of 25 cases of chordoma (a pleomorphic and metastasizing neoplasm).

Am J Surg Pathol 7: 161–170, 1983

- 9) Asano S, Kawahara N, Kirino T: Intradural spinal seeding of a clival chordoma. *Acta Neurochir (Wien)* 145: 599–603; discussion 603, 2003
- 10) Forsyth PA, Cascino TL, Shaw EG, Scheithauer BW, O'Fallon JR, Dozier JC, Piepgras DG: Intracranial chordomas: a clinicopathological and prognostic study of 51 cases. *J Neurosurg* 78, 741–747, 1993
- 11) Korinth M, Schönrock L, Mayfrank L, Gilsbach JM: Primary intradural pontocerebellar chordoma metastasizing in the subarachnoid spinal canal. *Zentralbl Neurochir* 60: 146–150, 1999
- 12) Krol G, Sze G, Arbit E, Marcove R, Sundaresan N: Intradural metastases of chordoma. *AJNR Am J Neuroradiol* 10: 193–195, 1989
- 13) Stough DR, Hartzog JT, Fisher RG: Unusual intradural spinal metastasis of a cranial chordoma. Case report. *J Neurosurg* 34: 560–562, 1971
- 14) Tsuboi Y, Hayashi N, Kurimoto M, Nagai S, Sasahara M, Endo S: Malignant transformation of clival chordoma after gamma knife surgery—case report. *Neurol Med Chir (Tokyo)* 47: 479–482, 2007
- 15) Uggowitz MM, Kugler C, Groell R, Lindbichler F, Radner H, Sutter B, Ranner G: Drop metastases in a patient with a chondroid chordoma of the clivus. *Neuroradiology* 41: 504–507, 1999
- 16) Steenberghs J, Kiekens C, Menten J, Monstrey J: Intradural chordoma without bone involvement. Case report and review of the literature. *J Neurosurg* 97: 94–97, 2002
- 17) Ito E, Saito K, Nagatani T, Ishiyama J, Terada K, Yoshida M, Wakabayashi T: Intradural cranial chordoma. *World Neurosurg* 73: 194–197; discussion e31, 2010
- 18) Wolfe JT, Scheithauer BW: “Intradural chordoma” or “giant ecchordosis physaliphora”? Report of two cases. *Clin Neuropathol* 6: 98–103, 1987
- 19) Holton JL, Steel T, Luxsuwong M, Crockard HA, Revesz T: Skull base chordomas: correlation of tumour doubling time with age, mitosis and Ki67 proliferation index. *Neuropathol Appl Neurobiol* 26: 497–503, 2000

Address reprint requests to: Yoshifumi Kawanabe, MD, PhD, Department of Neurosurgery, Shizuoka General Hospital, 4-27-1, Kita-Antou, Aoi-ku, Shizuoka, Shizuoka 420-8527, Japan.
e-mail: bwh5255725@yahoo.co.jp