

Effect of Pulpotomy Procedures With Mineral Trioxide Aggregate and Dexamethasone on Post-endodontic Pain in Patients with Irreversible Pulpitis: A Randomized Clinical Trial

 Mona BAGHERI,  Hussein KHIMANI,  Lida PISHBIN,  Hassan SHAHABINEJAD

ABSTRACT

Objective: Endodontic post-treatment pain continues to be one of the main problems encountered by dental professionals. Therefore, pain control during and after endodontic treatment is one of the most important issues in endodontics. The purpose of this clinical trial was to compare postoperative pain relief achieved with dexamethasone (DEX) and mineral trioxide aggregate (MTA) used as pulp coverage after pulpotomy in human molars with irreversible pulpitis.

Methods: This prospective double-blind study was conducted on 54 patients complaining of dental pain due to irreversible pulpitis. The standard pulpotomy procedure was performed by the same dentist in all patients. At the time of the cotton pellet placement, patients were randomly divided into three groups: those in whom a sterile dry cotton (DC) pellet was used, patients treated with a cotton pellet soaked in MTA, and those who were treated with a cotton pellet soaked in DEX. After completion of the treatment, patients received rescue medication every 6 hours for the first day. Postoperative pain was assessed at 6-hour intervals for 24 hours, and then every day until day 7 using a visual analog scale.

Results: In general, patients treated with MTA suffered the lowest levels of pain at all time intervals. Post-pulpotomy pain was significantly reduced at 18 and 24 hours and from days 2 to 7 post-treatment in the MTA group. DEX lowered the pain level more than the DC pellet. However, the differences observed in the mean pain scores of the DEX and DC pellet groups at all-time intervals were not statistically significant.

Conclusion: Pulpotomy procedures can reduce pain related irreversible pulpitis. Pulpotomy with MTA-soaked cotton pellet significantly reduces pain intensity in patients with irreversible pulpitis.

Keywords: Dexamethasone, irreversible pulpitis, mineral trioxide aggregate, pulpotomy, postoperative endodontic pain, visual analog scale

Please cite this article as:
Bagheri M, Khimani H, Pishbin L, Shahabinejad H. Effect of Pulpotomy Procedures With Mineral Trioxide Aggregate and Dexamethasone on Post-endodontic Pain in Patients with Irreversible Pulpitis: A Randomized Clinical Trial. *Eur Endod J* 2019; 4: 69-74

From the Department of Endodontics (M.B.) Kerman Dental School, Kerman, Iran; Department of Endodontics (H.K.), Boston University, Henry M Goldman School of Dental Medicine, Boston, USA; Department of Pediatric Dentistry (L.P.), Boston University, Henry M Goldman School of Dental Medicine, Boston, USA; Department of Endodontics (H.S. ✉shahabi@bu.edu), Boston University, Henry M Goldman School of Dental Medicine, Boston, USA

Received 25 March 2019,
Accepted 03 April 2019

Published online: 20 June 2019
DOI 10.14744/ej.2019.91885

HIGHLIGHTS

- The goal of this prospective study was to compare postoperative pain after the clinical application of MTA, DEX, and DC in emergency pulpotomy procedures.
- Results of this study showed that the MTA-treated group reported less postoperative pain compared to both DEX and DC-treated groups at each time interval.
- The pain-relieving property of DEX was higher than DC and lower than that of MTA.
- Pulpotomy with a MTA-soaked cotton pellet significantly reduces pain intensity in patients with irreversible pulpitis.

INTRODUCTION

Pain of odontogenic origin has long been a source of fear and anxiety among the general population (1). It has also been a common source of frustration among dentists who have difficulties to alleviate their patient's pain (2). Endodontic post-treatment pain continues to be a significant problem facing the dental profession (3). Therefore, pain control during and after endodontic treatment is one of the most important issues in endodontics. Consequently, inhibiting the post-treatment pain that affects both the patients and dentists is an important factor to consider when performing dental treatment.

Endodontic pain is often an emergency situation that necessitates immediate treatment. It has been indicated that emergency pulpotomy is very effective in relieving acute dental pain caused by acute pulpitis. Irreversible pulpitis is the most common reason for performing endodontic treatment, characterized by prolonged sensitivity to cold or heat (4).

Immediate postoperative pain is most likely to occur in patients with irreversible pulpitis following treatment. It has a high occurrence of 25%–40% (5). This pain is influenced by several factors, such as patient anxiety, pulpal status, existence of pre-treatment pain, and manipulation of periapical tissues (6).

Many medications have been prescribed to relieve pain in irreversible pulpitis. Opioid and non-opioid analgesics, benzodiazepines, non-steroidal anti-inflammatory drugs, corticosteroids, or antibiotics, and even usage of mineral trioxide aggregate (MTA), have been prescribed in dentistry (7-10). Among the several treatment options, an emergency pulpotomy is the most reliable way to obtain pain relief in vital pulp cases (4).

Mineral trioxide aggregate has attracted attention in the field of endodontics as a potential medicament for pulpotomy procedures, pulp capping, apexification, repair of root perforation, and repair of resorptive defects (11, 12). It also has favourable sealing ability, biocompatibility, and the ability to induce dentine bridge formation, along with cementum and periodontal ligament regeneration (13).

The pain following endodontic therapy is often linked to the inflammatory process (14). Glucocorticoids inhibit the production by multiple cells or factors that are important in producing the inflammatory response (15). The post-pulpotomy pain-relieving effect of dexamethasone (DEX) as sedative dressing has not been evaluated previously. In addition, most of the studies involving MTA have only investigated its effect on dentine bridge formation rather than its analgesic effects. Therefore, the purpose of this clinical trial was to compare the postoperative pain relief of DEX and MTA after pulpotomy in human permanent molars with irreversible pulpitis. Furthermore, the relationship between pre- and postoperative pain levels was also investigated. The null hypothesis was that there is no significant difference among the three pulp capping agents in terms of post-operative pain.

MATERIALS AND METHODS

Ethical statement

The research proposal was reviewed and confirmed by the ethics committee of Kerman University of Medical Sciences, Kerman, Iran. Patients involved in the study were formally informed, and each patient signed a consent form prior to enrollment. Consent form provided patient comprehensive information about the purposes and background of the study, clinical procedure, risks and discomfort, potential benefits, costs and payment, confidentiality, use and disclosure of health information, and subjects' rights and freedom to quit from the study at any time.

This prospective double-blind study was conducted on 54 patients who experienced dental pain due to irreversible pulpitis, which was determined based on clinical examination. Therapeutic interventions were performed by two different clinicians.

All patients with a single painful and restorable molar indicating symptomatic irreversible pulpitis (i.e., a history of sponta-

neous pain for a few seconds to several hours, pain exacerbating with hot and cold fluids, radiating pain, or reproducible pain with cold testing) were included in the study.

Exclusion criteria were the following: patients who used analgesics for more than 1 day, patients taking antibiotics, patients with prior history of root canal therapy, tenderness to percussion, pulpal necrosis as diagnosed by thermal and electrical tests, evidence of periapical radiolucency, active systemic disease, moderate or severe marginal periodontitis, internal/external root resorption in periapical radiograph, patients whose tooth mobility was greater than Grade 1 and diffuse pulp chamber calcification. In this study, those teeth with no bleeding as an indicator of pulp vitality after access cavity preparation were also excluded.

Pulpal diagnosis was determined by cold test and electric pulp test. Periapical diagnosis was based on percussion and palpation examination along with radiographic evaluation. A comprehensive clinical examination was also performed to rule out intra/extraoral swelling, the presence of a sinus tract, or other major pathology.

The standard pulpotomy procedure was performed by the first dental practitioner for all the patients. Inferior alveolar nerve block (for mandibular teeth-2% Lidocaine 1:100,000 epinephrine carpules (Daroupakhsh, Tehran, Iran) and buccal infiltration (for maxillary teeth) were administered, the teeth were isolated with a rubber dam, caries were removed, and then the access cavities were prepared. After the removal of the coronal pulp tissue, the pulp chamber was irrigated with sterile saline solution and dried with sterile cotton pellets. Pulp covering and temporary restoration were performed by a second dental practitioner. At each treatment step and follow-up visit, clinical assessment of the treated tooth, which was only identified by a specified code, was carried out by two experienced dental practitioners who were blinded to the treatment groups.

The patients were randomly divided into three groups. Group 1: sterile dry cotton (DC) pellet; Group 2: a cotton pellet soaked in white MTA (Proroot, USA). Group 3: 8 mg/2 ml DEX (Osveh, Iran). In the MTA group, the cotton pellet was prepared by soaking the pellet in diluted white MTA (3:1 liquid to powder ratio). After placing the cotton pellet in the pulp chamber, the access cavity was properly sealed with Coltisol (Ariadent, Iran).

Patients were given postoperative forms that included instructions on rescue medication guidelines (400 mg Ibuprofen every 6 hours for the first 24 hours and then as needed. In case the patient was unable to take Ibuprofen, 500 mg acetaminophen), and recording of the pain level score. Pain was recorded using a visual analog scale (VAS) for pain from 0 (no pain) to 10 (worst pain) at 6, 12, 18, and 24 hours and 2 to 7 days after treatment.

An emergency telephone number was provided to patients to be able to report any possible problems. Treatment was rendered for patients who required any additional treatment, such as a pulpectomy; however, they were excluded from the study.

Patients were contacted by phone daily and appointments for RCT were scheduled at the end of 7 days. Patients were asked to record their pain severity in the provided charts. After the 7th day, the patients handed in the completed charts, and an appointment was scheduled to complete the treatment procedure.

Statistical analysis

Data analysis was done using the SPSS 20.0 software package. All data were expressed as ±1 standard deviation (SD). After testing for normality of pairwise differences with the Shapiro–Wilk normality test, the mean values of data were calculated, and statistical significance was determined with the analysis of variance to compare the effect of both sedative dressings on the severity of postoperative pain between the different groups. A P<0.05 was considered to be statistically significant.

RESULTS

A total of 54 patients were enrolled for this clinical trial. Forty-five patients (27 women and 18 men) completed the 7-day follow-up of the study. Nine patients left or were excluded from this study (Diagram 1). The demographic data of three groups of patients with irreversible pulpitis are presented in Table 1.

All patients reported their pain levels at 6-hour intervals for a period of 24 hours and then every 24 hours until day 7 after treatment.

To compare the three therapeutic methods, the average VAS score was calculated for each patient at different time points. Pre-treatment VAS was as follows: 25% ≤5.5, 50% ≤7, 75% ≤8, and 25% ≥8 (Table 2). No significant differences in pre- and

postoperative pain scores were seen among the three groups with respect to age, gender, and tooth location (P>0.05) (Tables 1 and 2). However, 24 hours after treatment and on days 6 and 7, female patients complained more of severe pain compared to male patients.

Regardless of the pulpotomy procedure, the mean VAS for pain showed that pulpotomy was efficacious in reducing post-treatment pain in all patients with irreversible pulpitis (P<0.001) (Table 2). It was observed that the differences between the VAS scores of the three treatment methods were significant (P=0.014).

In the group treated with MTA, the patients had no post-treatment severe pain at any time interval except at 6 (20% cases) and 12 (5% cases) hours postoperatively (Fig. 1). Severe pain was reported at all-time intervals by dry cotton- and DEX-treated patients (except 3 and 4 days post-treatment) (Figs. 2 and 3). The percentage of subjects reporting no or mild pain after the treatment period was 20%–100% for MTA-treated, 5%–95% for DEX-treated, and 16%–80% for DC-treated groups (Figs. 1–3).

TABLE 1. Demographic data of three groups

Group/No	Gender		Age	
	Male	Female	Mean	Range
DC/15 cases	4 (26.7%)	11 (73.3%)	30.47±10.13	18-44
MTA/15 cases	9 (60.0%)	6 (40.0%)	28.87±11.03	19-52
DEX/15 cases	5 (33.3%)	10 (66.7%)	26.07±5.65	21-36
Total	18 (40.0%)	27 (60.0%)	28.47±9.21	19-52

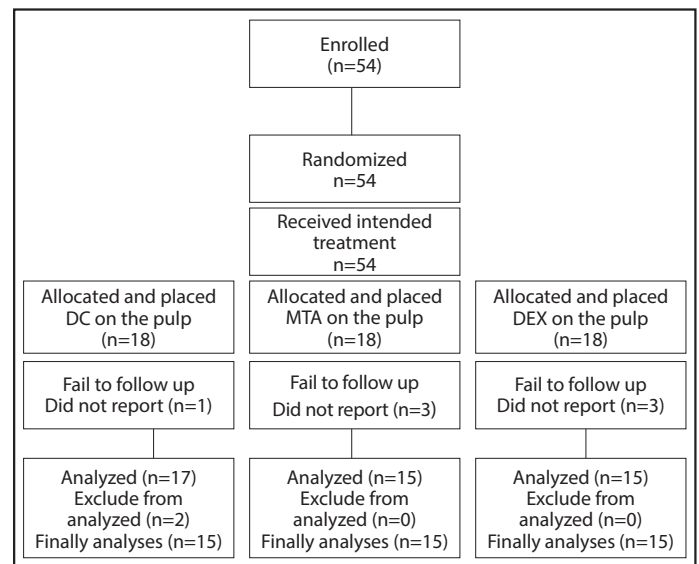


Diagram 1. CONSORT flow chart: Flow of patients through each stage. CONSORT=Consolidated Standards of Reporting Trials

TABLE 2. Pre- and postoperative VAS for pain of all patients regardless of treatment

Time point	n	Mean±SD	Minimum	Maximum	Percentiles		
					25 th	50 th	75 th
Pre-operative VAS	45	6.51±1.39	3.00	9.00	5.50	7.00	8.00
VAS 6 hour	45	4.02±2.80	0.00	9.00	2.00	4.00	6.00
VAS 12 hour	45	3.02±2.58	0.00	7.00	0.00	3.00	5.00
VAS 18 hour	45	2.31±2.38	0.00	7.00	0.00	2.00	4.00
VAS 24 hour	45	1.93±2.24	0.00	8.00	0.00	2.00	3.00
VAS 2 day	45	1.48±2.19	0.00	9.00	0.00	0.00	2.50
VAS 3 day	45	1.48±1.98	0.00	9.00	0.00	0.00	3.00
VAS 4 day	45	1.60±2.31	0.00	9.00	0.00	0.00	3.00
VAS day	45	1.62±2.53	0.00	9.00	0.00	0.00	3.00
VAS 6 day	45	1.46±2.37	0.00	9.00	0.00	0.00	2.00
VAS 7 day	45	1.46±2.44	0.00	9.00	0.00	0.00	2.00

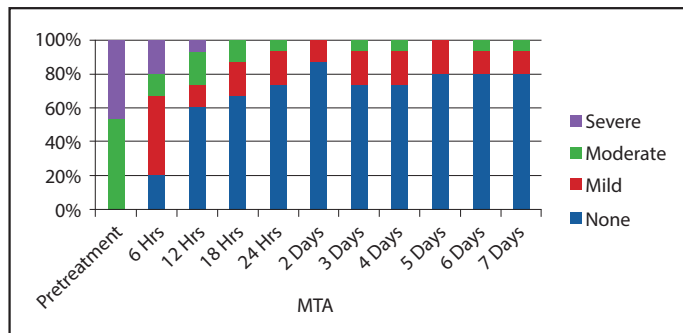


Figure 1. Percentage of subjects in MTA group who reported no, mild, moderate, or severe pre- and post-treatment pain at each time interval

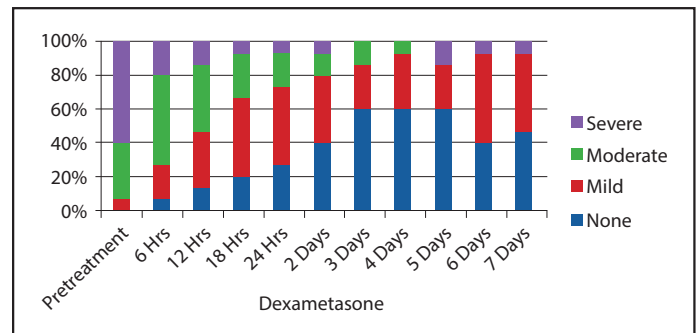


Figure 3. Percentage of subjects in DEX group who reported no, mild, moderate, or severe pre- and post-treatment pain at each time interval

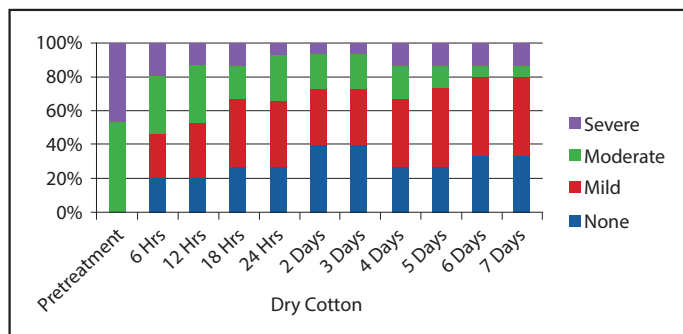


Figure 2. Percentage of subjects in DC group who reported no, mild, moderate, or severe pre- and post-treatment pain at each time interval

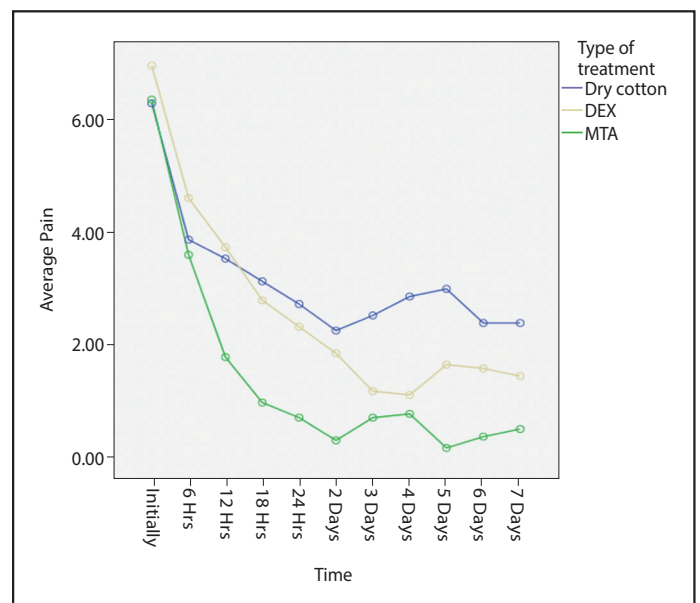


Figure 4. Visual analog scale for post-treatment pain in three groups at each time point

TABLE 3. Mean and standard deviation of pain intensity values or visual analog scale for treatment groups at each time point

POP/Treatment	DC Mean±D	MTA Mean±SD	DEX Mean±SD	P
6 hour	3.87±2.77	3.6±3.2	4.6±2.5	0.52
Range	0-9	0-9	0-9	
12 hour	3.53±2.61	1.8±2.54	3.73±2.28	0.06
Range	0-7	0-7	0-7	
18 hour	3.13±2.66	1.0±1.81	2.8±2.14	0.02
Range	0-7	0-6	0-7	
24 hour	2.73±2.49	0.73±1.62	2.33±2.12	0.01
Range	0-8	0-6	0-7	
2 Day	2.26±2.65	0.33±0.9	1.86±2.23	0.016
Range	0-9	0-3	0-7	
3 Day	2.53±2.41	0.73±1.43	1.2±1.61	0.03
Range	0-9	0-5	0-4	
4 Day	2.86±3.04	0.8±1.65	1.13±1.50	0.03
Range	0-9	0-6	0-4	
5 Day	3.0±2.97	0.2±0.41	1.66±2.63	0.003
Range	0-9	0-1	0-8	
6 Day	2.4±2.99	0.4±1.05	1.60±2.32	0.02
Range	0-9	0-3	0-9	
7 Day	2.40±2.99	0.53±1.55	1.46±2.35	0.026
Range	0-9	0-6	0-9	

DC: Dry cotton, MTA: Mineral trioxide aggregate, DEX: Dexamethasone, SD: Standard deviation, POP: Post-operative

Table 3 shows the mean and SDs values of the VAS scores for DC, DEX, and MTA at different time intervals. In general, the MTA treatment was associated with the lowest levels of endodontic pain or VAS for pain at all-time points. In the treatment groups, the differences of VAS was not statistically

significant at 6 and 12 hours post-treatment ($P>0.05$) (Table 3). However, a statistically significant difference at 18 and 24 hours and 2–7 days post-treatment was found in the groups (Fig. 4). The DEX treatment was also associated with lower VAS levels compared with the DC-treated group (Table 3). However, no significant differences were observed in the mean pain scores of the two groups.

DISCUSSION

The primarily aim of this study was to determine and compare the post-pulpotomy pain-relieving the effect of administration of DEX and MTA as sedative dressings in patients with irreversible pulpitis. Furthermore, this study was designed to investigate the relationship between pre- and post-treatment pain levels in these patients. The control of postoperative endodontic pain continues to pose a significant challenge for dentists. Among various dental procedures, endodontic treatment is associated with more frequent and severe postoperative pain (16, 17).

New strategies of pain management with optimal analgesic efficacy and minimum incidence of side effects are always needed to prevent and control the occurrence of postop-

erative endodontic pain. Pre-operative administration of some analgesics, such as ibuprofen and acetaminophen plus codeine has shown to reduce the onset of the postoperative pain (18). There are few studies evaluating oral administration of DEX to prevent and control postoperative endodontic pain (19, 20, 21). Furthermore, no studies have evaluated DEX pulp coverage to determine if an analgesic protocol to prevent and control the occurrence of postoperative endodontic pain can be established.

This is the first study to evaluate the post-pulpotomy pain-relieving the effect of DEX, MTA, and DC (control group) as sedative dressings. The patients treated with these three protocols were followed to evaluate the level of postoperative pain and discomfort over a 7-day period of observation. Results of this study showed no significant differences in pre- and postoperative pain scores with respect to age, gender, and tooth location. These findings are similar to other studies (18, 22).

Regardless of the type of material used for pulp coverage, results showed that performing a pulpotomy is not only effective in alleviating pain, but also is an appropriate method for the endodontic emergency treatment in the patients with irreversible pulpitis (Table 1) ($P < 0.001$). It has been demonstrated that the pulpotomy procedure is the most reliable way to obtain pain relief among all treatment procedure for patients with painful irreversible pulpitis (4).

The goal of this prospective study was to compare postoperative pain after the clinical application of MTA, DEX, and DC for pain relief. Despite a number of factors influencing the patient's reaction to pain, the use of the VAS in evaluating the severity of pain after endodontic treatment has been well established (23). Results of this study showed that MTA-treated group reported less postoperative pain and VAS in comparison to both DEX- and DC-treated groups at each time interval, thus rejecting the null hypothesis. The differences in VAS between the MTA-treated and DEX-treated groups were significant at all-time points except 6 and 12 hours after treatment.

It has been shown that MTA stimulates cytokine release from bone cells, induces hard-tissue formation, has a dentinogenic effect on the pulp, exhibits antimicrobial properties, and has the ability to maintain pulp integrity after pulp capping and pulpotomy without cytotoxic effects when it is placed in contact with pulpal or periradicular tissue (24). It also promotes regeneration of pulp tissues that fulfills the purpose of pulpotomy treatment to maintain the treated tooth in a functional state (25). Microbial flora of infected root canals, host factors, and operative factors are the main contributing factors for postoperative pain and discomfort (26). The antibacterial properties of MTA and its ability to stimulate cytokine release may explain why the VAS for pain was lowest in the MTA-treated group compared to the DC- and DEX-treated group.

The postoperative pain may also develop when the integrity of the periapical tissues is compromised. Irritation of periradicular tissues caused by local trauma, caustic irrigating solutions, or contamination during endodontic treatment may cause an acute inflammatory reaction, potentially leading to pain and/or swelling (27). Many chemical mediators (prostaglandins,

leukotrienes, bradykinin, etc.) have been associated with the inflammatory process. The concentration of bradykinin, a potent pain mediator, was 13 times greater in teeth with irreversible pulpitis compared to the normal pulps (28). These chemical mediators cause pain at the site of inflammation (29). Pain can be induced indirectly by an increase in edema and tissue pressure, or directly through lowering the excitability threshold of the A-delta and C-fibers (18).

DEX is a steroidal anti-inflammatory drug that inhibits phospholipase A2 and consequently reduces the amount of chemical mediators, decreasing the polymorphonuclear leukocyte chemotaxis (30). However, it has been shown that the administration of DEX leads to a partial inhibition of development of inflammatory periapical lesion. In comparison with the DC-treated group, DEX was not able to significantly reduce pain intensity at any time interval. It has been suggested in previous oral pain studies that the absorption and distribution of the medication occur before the initiation of surgical tissue damage and consequent production of inflammatory mediators to provide analgesia to patients before endodontic treatment is started (18).

CONCLUSION

Pulpotomy procedures can reduce pain related irreversible pulpitis. Pulpotomy with MTA-soaked cotton pellet significantly reduces pain intensity in patients with irreversible pulpitis undergo pulpotomy.

Disclosures

Conflict of interest: The authors deny any conflicts of interest related to this study.

Ethics Committee Approval: The research proposal was reviewed and confirmed by the ethics committee of Kerman University of Medical Sciences, Kerman, Iran.

Peer-review: Externally peer-reviewed.

Financial Disclosure: The research costs were funded by Kerman University of Medical Sciences.

Authorship contributions: Concept – H.S.; Design – H.S., L.P.; Supervision – H.S.; Funding – H.S.; Materials – H.S., M.B.; Data collection &/or processing – H.S., L.P., M.B.; Analysis and/or interpretation – H.K., H.S., L.P.; Literature search – H.S., H.K., L.P.; Writing – H.K., H.S.; Critical Review – H.K., H.S.

REFERENCES

1. Sohn W, Ismail W. Regular Dental Visits and Dental Anxiety in an Adult Dentate Population. *J Am Dent Assoc* 2005; 136: 58-66.
2. Nobuhara WK, Carnes DL, Gilles JA. Anti-Inflammatory Effects of Dexamethasone on Periapical Tissues following Endodontic Overinstrumentation. *J of Endod* 1993; 19:501-7.
3. Walton RE, Fouad A. Endodontic flare-ups. A prospective study of incidence and related factors *J Endod* 1992; 18: 172-7.
4. Asgari S, Eghbal MJ. The effect of pulpotomy using a Calcium-Enriched Mixture cement versus one-visit root canal therapy on postoperative pain relief in irreversible pulpitis: a randomized clinical trial. *Odontology* 2010; 98:126-33
5. Polycarpou N, Ng YL, Canavan D, et al. Prevalence of persistent pain after endodontic treatment and factors affecting its occurrence in cases with complete radiographic healing. *Int Endod J* 2005;38:169-78.
6. Oleson M, Drum M, Reader A, et al. Effect of pre-operative ibuprofen on the success of the inferior alveolar nerve block in patients with irreversible pulpitis. *J Endod* 2010;36:379-82.

7. Gallatin E, Reader A, Nist R, et al. Pain reduction in untreated irreversible pulpitis using an intraosseous injection of DepoMedrol. *J Endod* 2000;26:633-8.
8. Nusstein JM, Beck M. Comparison of pre-operative pain and medication use in emergency patients presenting with irreversible pulpitis or teeth with necrotic pulps. *Oral Surg Oral Med Oral Pathol Oral Radiol Endod* 2003;96:207-14.
9. Keenan JV, Farman AG, Fedorowicz Z, et al. Antibiotic use for irreversible pulpitis. *Cochrane Database Syst Rev* 2005;18: CD004969.
10. Mardani S, Eghbal MJ, Baharvand M. Prevalence of referred pain with pulpal origin in the head, face and neck region. *Iran Endod J* 2008;3:8-10.
11. Torabinejad M, Chivian N. Clinical applications of mineral trioxide aggregate. *J Endod* 1999;25:197-205.
12. Castellucci A. The use of mineral trioxide aggregate in clinical and surgical endodontics. *Dent Today*.2003;22:74-80.
13. Holah G, Eidelman E, Fuks AB. Long-term evaluation of pulpotomy in primary molars using mineral trioxide aggregate or formocresol. *Pediatr Dent* 2005;27:129-36.
14. Parirokh M, Rekabi AR, Ashouri R, et al. Effect of occlusal reduction on post-operative pain in teeth with irreversible pulpitis and mild tenderness to percussion. *J Endod* 2013;39:1-5.
15. Marshall JG. Consideration of steroids for endodontic pain. *Endod Topics* 2002; 3: 41-51
16. Torabinejad M, Shabahang S, Bahjri K. Effect of MTAD on postoperative discomfort: a randomized clinical trial. *J Endod*. 2005;31:171-6.
17. Levin L, Amit A, Ashkenazi M. Post-operative pain and use of analgesic agents following various dental procedures. *Am J Dent* 2006;19:245-7.
18. Attar S, Bowles WR, Baisden MK, et al. Evaluation of pre-treatment analgesia and endodontic treatment for post-operative endodontic pain. *J Endod* 2008;34:652-5
19. Glassman G, Krasner P, Morse DR, et al. A prospective randomized double-blind trial on efficacy of dexamethasone for endodontic interap-
pointment pain in teeth with asymptomatic inflamed pulps. *Oral Surg Oral Med Oral Pathol Oral Radiol Endod* 1989;67:96-100.
20. Liesinger A, Marshall FJ, Marshall JG. Effect of variable doses of dexamethasone on posttreatment endodontic pain. *J Endod* 1993;19:35-9.
21. Pochapski MT, Santos FA, de Andrade ED, et al. Effect of pre-treatment dexamethasone on post-endodontic pain. *Oral Surg Oral Med Oral Pathol Oral Radiol Endod* 2009;108:790-5.
22. Jalalzadeh SM, Mamavi A, Shahriari S, et al. Effect of pre-treatment prednisolone on post-endodontic pain: A double-blind parallel-randomized clinical trial. *J Endod* 2010; 36(6):978-81.
23. Habib S, Mathews RW, Scully S, et al. A study of the comparative efficacy of four common analgesics in the control of post-surgical dental pain. *Oral Surg Oral Med Oral Pathol Oral Radiol Endo* 1990;70:559-63.
24. Torabinejad M, Hong CU, McDonald F, et al. Physical and chemical properties of a new root end filling material. *J Endod* 1995;21:349-53.
25. Ansari G, Ranjpour M. Mineral trioxide aggregate and formocresol pulpotomy of primary teeth: A 2 year follow up. *Int Endod J* 2010;43:413-8.
26. Torabinejad M, Cymerman J, Frankson M, et al. Effectiveness of various medications on post-operative pain following complete instrumentation. *J Endod* 1994;20:345-54.
27. Mehrvarzfar P, Shababi B, Sayyad R, et al. Effect of supraperiosteal injection of dexamethasone on post-operative pain. *Aust Endod J* 2008;34:25-9.
28. Bowles W, Withrow J, Lepinski A, et al. Tissue Levels of Immunoreactive Substance P Are Increased in Patients with Irreversible Pulpitis. *J Endod* 2003; 29: 265-67.
29. Lin S, Levin L, Emodi O, et al. Etodolac versus dexamethasone effect in reduction of post-operative symptoms following surgical endodontic treatment: a double-blind study. *Oral Surg Oral Med Oral Pathol Oral Radiol Endod* 2006;101:814-7.
30. Czock D, Keller F, Rasche FM, et al. Pharmacokinetics and pharmacodynamics of systemically administered glucocorticoids. *Clin Pharmacokinet* 2005;44:61-98.