



Surgical Technique

A Surgical Technique to Avoid Mediolateral Overhang during Total Knee Arthroplasty

Samuel W. Carlson, MD ^{a,*}, Elizabeth B. Gausden, MD, MPH ^b, Robert T. Trousdale, MD ^a^a Department of Orthopedic Surgery, Mayo Clinic, Rochester, MN, USA^b Department of Orthopedic Surgery, Hospital for Special Surgery, New York, NY, USA

ARTICLE INFO

Article history:

Received 11 September 2020

Received in revised form

5 December 2020

Accepted 18 December 2020

Available online xxx

Keywords:

Primary total knee arthroplasty

Surgical technique

Component malposition

ABSTRACT

Femoral component sizing and positioning is an essential component of performing a successful total knee arthroplasty. Failure to size or position the femoral component correctly can result in reduced range of motion, instability, soft-tissue impingement, and irritation. The following is a description of a novel technique that allows the surgeon to use an intercondylar autograft to translate the femoral component in the mediolateral direction and avoid the consequences of mediolateral femoral component overhang. © 2021 Published by Elsevier Inc. on behalf of The American Association of Hip and Knee Surgeons. This is an open access article under the CC BY-NC-ND license (<http://creativecommons.org/licenses/by-nc-nd/4.0/>).

Introduction

Selecting the components of the appropriate size in total knee arthroplasty (TKA) is essential to providing patients with the best possible outcome. Inappropriate component positioning and sizing affects range of motion, soft-tissue balancing, stability, soft-tissue irritation, and impingement [1–3]. Previous studies have demonstrated that accurate component sizing can be difficult, particularly in women. Women tend to have more narrow femurs, and as a result, components may fit appropriately in the anteroposterior dimension while overhanging in the mediolateral dimension [4,5]. Overhang of more than 3 mm in the mediolateral plane has been reported in up to 68% of femoral TKA components in women and is associated with an increased likelihood of postoperative knee pain and decreased patient satisfaction [5–7]. In addition to the risk of anterior knee pain associated with femoral component overhang, appropriate positioning of the femoral component along the lateral border of the distal femur optimizes patellofemoral tracking [7–9]. Therefore, it is essential for a surgeon to develop multiple strategies to avoid the problems associated with malpositioned femoral components.

The following is the operative technique used by the senior author (RTT) for incorporating an intercondylar autograft to avoid

mediolateral overhang when using a posterior stabilized TKA system. Using this technique, the surgeon can correct the mediolateral positioning of the femoral component after the initial box cut is performed. This technique provides the surgeon with intraoperative flexibility and the ability to efficiently correct a problem that is oftentimes difficult to anticipate preoperatively.

Surgical technique

The senior author performs his standard TKA exposure and begins preparing the femur. A distal femoral cut is made using an intramedullary guide set to resect the appropriate amount of distal femur at an angle between 4° and 5° of valgus depending on the preoperative deformity. The femur is sized using anterior femoral referencing, and the appropriate 4-in-1 guide is applied with 3° of external rotation. After the anterior, chamfer, and posterior condylar cuts, the box-cutting guide is placed on the femur. This is applied so that the guide is flush with the lateral femur, while avoiding any significant overhang medially. The guide is secured with a pin, and then a reciprocating saw is used to make the box cut. The tibial cut is then made before trialing. During trialing, the position of the femoral component is assessed. If it is determined that there is too much mediolateral femoral component overhang, the trial femoral component is removed, and the box-cutting guide is placed again (Fig. 1). The senior author prefers no more than 1 mm of overhang. The box-cutting guide is then repositioned in the direction of the desired final position. This results in exposed

* Corresponding author. 200 1st St. SW, Rochester, MN 55905, USA. Tel.: +1-507-284-2884.

E-mail address: Carlson.samuel@mayo.edu

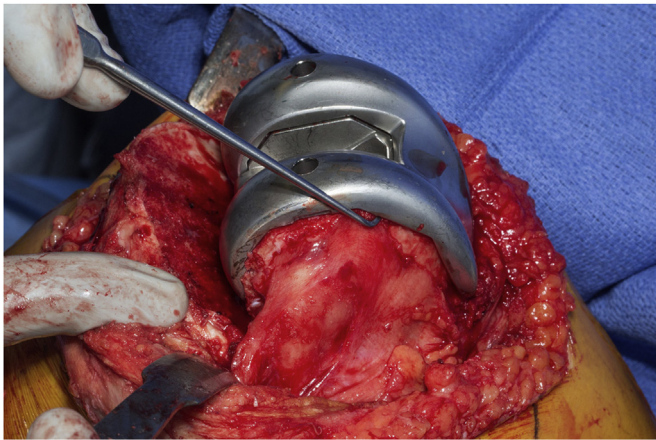


Figure 1. Femoral component lateral overhang.

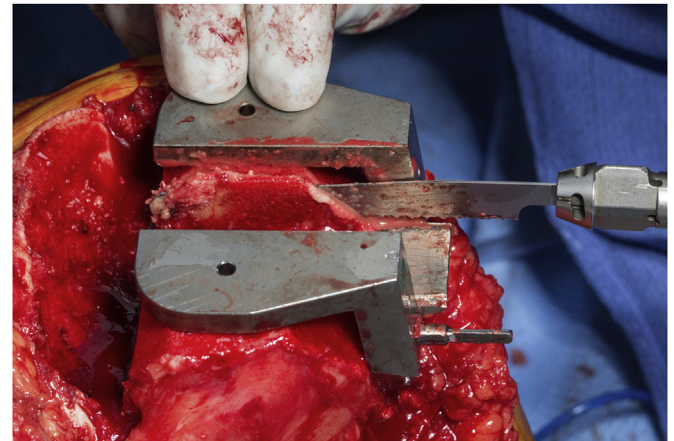


Figure 3. Completion of the anteroposterior cut of the lateral aspect of the medial femoral condyle.

intercondylar bone on the side to which the femoral component will be translated. For example, if the femoral component is overhanging on the lateral side, this will result in exposed bone on the medial femoral condyle (Fig. 2). The anteroposterior cut of the exposed femoral condyle is then performed with the reciprocating saw (Figs. 2 and 3). The cut is then completed with a perpendicular cut using the reciprocating saw and the central portion of the box-cutting guide (Fig. 4). Care must be taken to ensure the femur is not undercut, potentially increasing the risk of intraoperative fracture. The resulting autograft wafer of bone is then transplanted to the contralateral femoral condyle to provide additional bone to translate the femoral component (Fig. 5). The trial femoral component is then placed in the new translated position, and the previous mediolateral overhang is corrected (Fig. 6).

Discussion

Lateral or medial overhang of the femoral component is a common problem in TKA that is associated with worse outcomes [5-7]. We present the senior author's technique to correct and prevent mediolateral overhang with the use of an intercondylar autograft that allows shifting of the femoral component in the desired direction after the box is prepared.

Varying morphology of the distal femur frequently leads to challenges with sizing and positioning of the femoral component of

a TKA. For posterior stabilized knees, despite careful positioning before the box preparation in the coronal plane, overhang of more than 1 mm is a relatively common occurrence [5-7]. There are a limited number of strategies for addressing this overhang once the box is prepared. Various modern TKA systems offer a narrow femoral component option at multiple sizes to help minimize overhang, but this option is not available in all systems. Similarly, there are multiple gender-specific components currently in use [10]. However, narrow femoral components may alter the soft-tissue balancing and should be taken into account [10]. Another strategy may be to downsize the femoral component, which is suboptimal as it commonly will lead to flexion instability in an otherwise balanced knee. Therefore, it is important for surgeons to develop alternative strategies to recognize and to correct component malposition and size mismatches intraoperatively. The technique proposed here allows for precise correction of overhang intraoperatively after box preparation with an autograft wafer of bone from the femoral condyle. Multiple studies throughout the sports medicine literature detail the high rate of autograft incorporation within the knee [11,12].

Multiple studies have demonstrated the consequences that result from excessive mediolateral overhang. Mahoney and Kinsey measured the fit of femoral components relative to the bone cut edge in 437 consecutive TKAs performed in 391 patients [6]. The authors found that overhang ≥ 3 mm occurred in 40% of men and

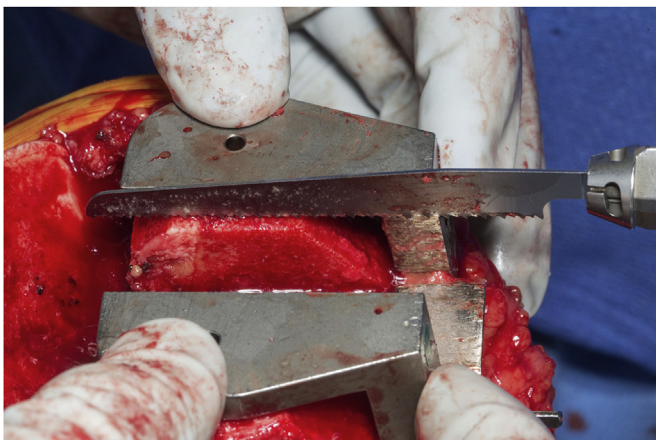


Figure 2. Anteroposterior cut of the lateral aspect of the medial femoral condyle.

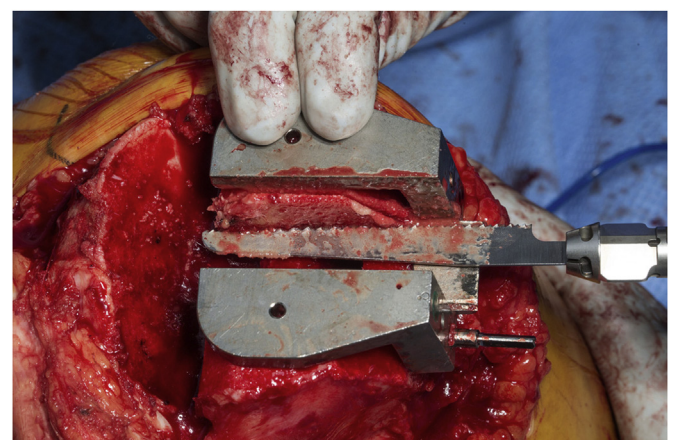


Figure 4. Lateral-medial cut of the lateral aspect of the medial femoral condyle.

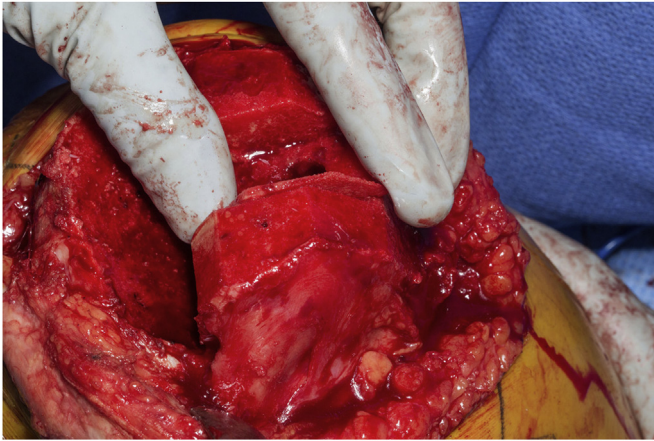


Figure 5. Transplanting the medial femoral condyle wafer to the lateral femoral condyle.

68% of women, and overhang was most common laterally. Women were found to have increased overhang both in terms of frequency and severity, and female sex served as a significant predictor of overhang. Furthermore, increased femoral component overhang was associated with an increased likelihood of clinically significant persistent knee pain, and overhang ≥ 3 mm in at least one zone resulted in a 90% increased risk of having clinically significant pain 2 years postoperatively. Bonnin et al. [7] investigated postoperative component overhang by comparing preoperative CT scans to postoperative implant size in 114 patients who underwent TKA. The authors found that mediolateral overhang occurred frequently but was more common and more severe in women. The authors also demonstrated that femoral component overhang resulted in an increased rate of residual pain postoperatively, decreased knee flexion, and decreased overall patient-reported clinical outcome measures. In addition to avoiding issues of pain and soft-tissue imbalance associated with overhang, the mediolateral femoral component positioning is important for proper patellar tracking, with a lateralized femoral component improving patellar tracking [1]. Rhoads et al. [13] performed a biomechanical study using cadaveric knees and demonstrated internal rotation and medial displacement of the femoral component increased the incidence of

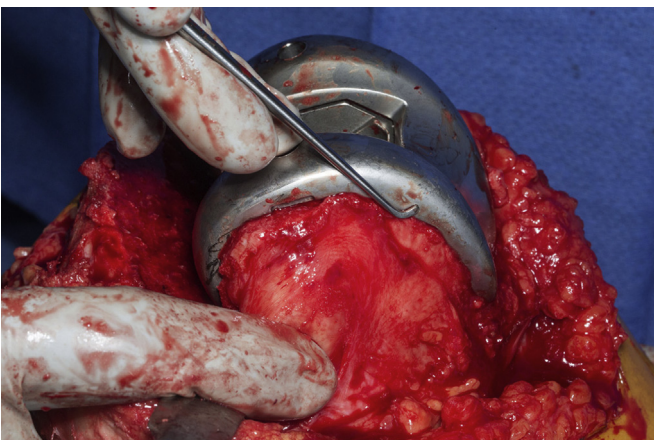


Figure 6. Correction of the femoral component lateral overhanging after transplant of the medial femoral condyle to the lateral femoral condyle.

patellar loosening, eccentric wear, and patellar fracture. In contrast, a lateralized femoral component allowed more lateral tracking of the patella, decreasing the risk of subluxation or dislocation [13]. Armstrong et al. [14] used cadaveric models to illustrate how the patella shifts with the femoral component—if the femoral component is medialized or internally rotated, the patella will shift medially, leading to patellar maltracking.

Mediolateral femoral component overhang increases the risk of persistent knee pain and worse clinical outcomes. This strategy provides surgeons with an efficient and effective technique to avoid the consequences associated with mediolateral overhang in TKA.

Summary

This surgical technique provides a novel approach that allows surgeons to use an intercondylar autograft to translate the femoral component in the mediolateral direction and avoid the consequences of mediolateral femoral component overhang.

Conflict of Interest

R. T. Trousdale received royalties from DePuy.

References

- [1] Steinbrück A, Schröder C, Woiczinski M, et al. Mediolateral femoral component position in TKA significantly alters patella shift and femoral roll-back. *Knee Surg Sports Traumatol Arthrosc* 2017;25(11):3561.
- [2] Lee BS, Cho HI, Bin SI, Kim JM, Jo BK. Femoral component varus malposition is associated with tibial aseptic loosening after TKA. *Clin Orthop Relat Res* 2018;476(2):400.
- [3] Scott CEH, Clement ND, Yapp LZ, Macdonald DJ, Patton JT, Burnett R. Association between femoral component sagittal positioning and anterior knee pain in total knee arthroplasty: a 10-year case-control follow-up study of a cruciate-retaining single-radius design. *J Bone Joint Surg Am* 2019;101(17):1575.
- [4] Asseln M, Hänisch C, Schick F, Radermacher K. Gender differences in knee morphology and the prospects for implant design in total knee replacement. *Knee* 2018;25(4):545.
- [5] Yan M, Wang J, Wang Y, Zhang J, Yue B, Zeng Y. Gender-based differences in the dimensions of the femoral trochlea and condyles in the Chinese population: correlation to the risk of femoral component overhang. *Knee* 2014;21(1):252.
- [6] Mahoney OM, Kinsey T. Overhang of the femoral component in total knee arthroplasty: risk factors and clinical consequences. *J Bone Joint Surg Am* 2010;92(5):1115.
- [7] Bonnin MP, Schmidt A, Basiglioni L, Bossard N, Dantony E. Mediolateral oversizing influences pain, function, and flexion after TKA. *Knee Surg Sports Traumatol Arthrosc* 2013;21(10):2314.
- [8] Rhoads DD, Noble PC, Reuben JD, Tullos HS. The effect of femoral component position on the kinematics of total knee arthroplasty. *Clin Orthop Relat Res* 1993;286:122.
- [9] Kawahara S, Matsuda S, Fukagawa S, et al. Upsizing the femoral component increases patellofemoral contact force in total knee replacement. *J Bone Joint Surg Br* 2012;94(1):56.
- [10] Ishida K, Shibamura N, Sasaki H, Takayama K, Kuroda R, Matsumoto T. Influence of narrow femoral implants on intraoperative soft tissue balance in posterior-stabilized total knee arthroplasty. *J Arthroplasty* 2020;35(2):388.
- [11] McCarty EC, Fader RR, Mitchell JJ, Glenn RE, Potter HG, Spindler KP. Fresh osteochondral allograft versus autograft: twelve-month results in isolated canine knee defects. *Am J Sports Med* 2016;44(9):2354.
- [12] Ishibashi Y, Toh S, Okamura Y, Sasaki T, Kusumi T. Graft incorporation within the tibial bone tunnel after anterior cruciate ligament reconstruction with bone-patellar tendon-bone autograft. *Am J Sports Med* 2001;29(4):473.
- [13] Rhoads DD, Noble PC, Reuben JD, Mahoney OM, Tullos HS. The effect of femoral component position on patellar tracking after total knee arthroplasty. *Clin Orthop Relat Res* 1990;260:43.
- [14] Armstrong AD, Brien HJ, Dunning CE, King GJ, Johnson JA, Chess DG. Patellar position after total knee arthroplasty: influence of femoral component malposition. *J Arthroplasty* 2003;18(4):458.