

CASE REPORT

Preoperative botulinum toxin type A: A case report of a proposed new strategy for giant hiatal hernia management

Francisco Tustumi  | Edno Tales Bianchi  | Sérgio Szachnowicz  |
 Rider May Cedro | Antonio Afonso de Miranda Neto  | André Luiz Gioia Morrell  |
 Ricardo Zugaib Abdalla  | Rubens Antonio Aissar Sallum  | Ivan Ceconello 

Department of Gastroenterology, Digestive Surgery Division, University of São Paulo, São Paulo, Brazil

Correspondence

Francisco Tustumi, Department of Gastroenterology, Digestive Surgery Division, University of São Paulo, Av. Dr. Enéas de Carvalho Aguiar 255, São Paulo, SP, CEP, Brazil.
 Email: franciscotustumi@gmail.com

Abstract

The use of preoperative ventral botulinum toxin for giant hiatal hernia management.

KEYWORDS

botulinum toxins, fundoplication, hiatal hernia, type A

1 | INTRODUCTION

Giant hiatal hernias present high risk of recurrence. The injection of botulinum toxin causes paralysis in abdominal wall muscles and decreases the pressure. Once the intra-abdominal pressure may affect the risk for hiatal hernia recurrence, we proposed a new strategy for giant hernias: the use of preoperative botulinum toxin.

A giant hiatal hernia is a type of hernia in which a considerable amount of the stomach is into the thoracic cavity, although there is no consensus about its definition. Sometimes, in severe cases, there is a massive herniation through the hiatus, with stomach and other abdominal organs in the chest.¹

Giant hiatal hernias are often complex conditions with a high risk of recurrence, which may lead to recurrence of the symptoms or even to dramatic conditions, such as the postoperative giant herniation.² Several strategies have been reported to reduce recurrence after hiatoplasty, such as pledgeted interrupted nonabsorbable sutures,³ mesh crural reinforcement, or wedge gastroplasty.⁴

In a pilot animal experimental study, Cakmak et al⁵ showed that local injection of BTX causes paralysis in abdominal wall muscles, increases the intra-abdominal

volume, and decreases the pressure. Considering that the risk for hiatal hernia recurrence may be affected by the intra-abdominal pressure,^{2,6,7} our team proposed a preoperative BTX injection strategy for the giant hiatal hernia management.

Here, we report case report with a proposed a new strategy for giant and complex hernias management: the use of preoperative botulinum toxin type A (BTX). The CARE Checklist⁸ was followed.

2 | CASE PRESENTATION

A 38-year-old female patient was admitted with severe malnutrition related to recurrent postfood nausea and vomiting. She also complained of chest pain and an aspiration pneumonia episode. Her history evidenced cognitive impairment and severe kyphosis. She denied alcohol consumption.

On admission, physical examination revealed normal sinus rhythm, normal pulse, and blood pressure. BMI: 17 kg/m².

Computed tomography (CT) and barium swallow test showed a large type IV hiatal hernia, containing the entire stomach, small bowel loops, colon, and spleen (Figures 1 and 2).

After obtaining informed consent and ensuring no contraindications exist, a preoperative botulinum toxin type A was used in the abdominal wall, as per the previously described technique for ventral hernias.⁸

Three hundred units of BTX are reconstituted in 150 cc of normal injectable saline. Six separate injection sites are identified on the patient's abdominal wall: right/left subcostal; right/left anterior axillary; right/left lower quadrants. Injection of 8.3 cc (16.6 units) of the BTX solution was performed with US guidance into the external oblique, internal oblique, and transverse abdominal muscles at each of the six sites (25 cc/50 units per injection site) (Figure 3).

A new CT was performed four weeks after performing the BTX. Abdominal wall muscle thickness decreased and lengthened before surgery, thus increasing the peritoneal cavity (Figures 4 and 5). Lateral abdominal wall muscle thickness and rectus muscle were assessed following the previously reported technique for ventral hernias.⁹ The measure was obtained from the superficial surface of the external oblique and rectus muscle to the deep surface of *transversus abdominis*. The anterior wall thickness changed from 8 to 6 mm. The right lateral wall thickness changed from 17 to 13 mm, and the left lateral wall changed from 16.7 to 14 mm.

After six weeks of the BTX injection, a laparoscopic hiatoplasty with anterior partial fundoplication and gastropexy was performed (Video S1). There were no complications. The patient was discharged two days after the elective surgery.

At seven months' follow-up, the patient had a significant improvement in symptoms. There was no evidence of recurrence in endoscopy (Figure 6).

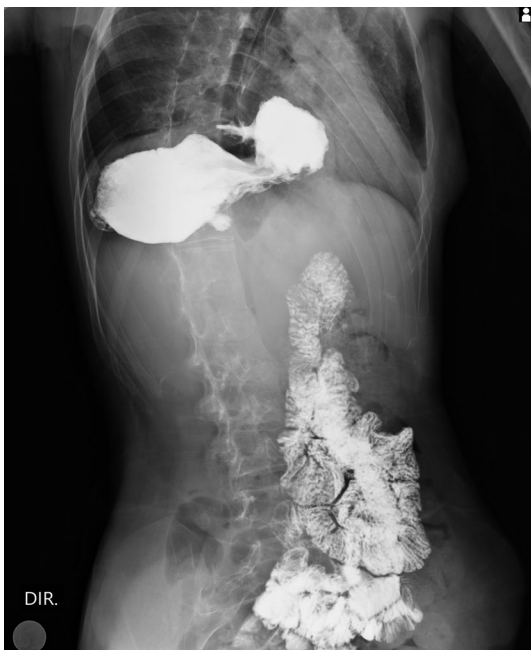

FIGURE 1 Barium swallow test. Giant type 4 hiatal hernia

3 | DISCUSSION

Giant complicated hiatal repair remains a challenge for surgeons. This study showed a successful treatment of a giant complicated hiatal hernia with preoperative botulinum toxin type A injection, which was not reported previously. The first described BTX administration into abdominal wall surgery was in 2009, by Ibarra-Hurtado et al,¹⁰ for the treatment of open abdomen management. Other authors have also reported successful management of giant complicated ventral hernias repair with preoperative botulinum toxin type A injection.^{5,6,8,11,12}

The BTX is a neurotoxin that blocks the release of acetylcholine on cholinergic nerve terminal.¹³ This leads to temporary loss of muscle tone, muscle elongation, and thinning.^{9,10} Thus, the BTX may lead to decrease intra-abdominal pressure, avoiding ventral or hiatal hernia recurrence.^{6,8,9}

The muscle paralysis achieves the maximum effect at four weeks and lasts 6-9 months.^{5,10} Thus, the BTX injection should be at least four weeks before the planned surgery. Considering that the risk of recurrence for hiatal hernia is higher in the first three months after the surgery,³ the length of action of BTX will cover this period, decreasing intra-abdominal pressure and allowing the occurrence of fibrosis, and ultimately, avoiding acute migration of the valve. However, hiatal hernia recurrence may occur after years of operation, and so, future studies with long-term follow-up are needed.¹⁴

The use of preoperative ventral BTX injection may be a useful new strategy to reduce the risk for hiatal hernia recurrence in dramatic giant hernias. One of the limitations of this report is that is a case report, and so no analytic outcomes could be assessed. However, this case presents a preoperative botulinum toxin type A strategy as a new option for the management of giant and complex hiatal hernias. Future controlled trials are warranted to determine the best strategy for avoiding recurrence.

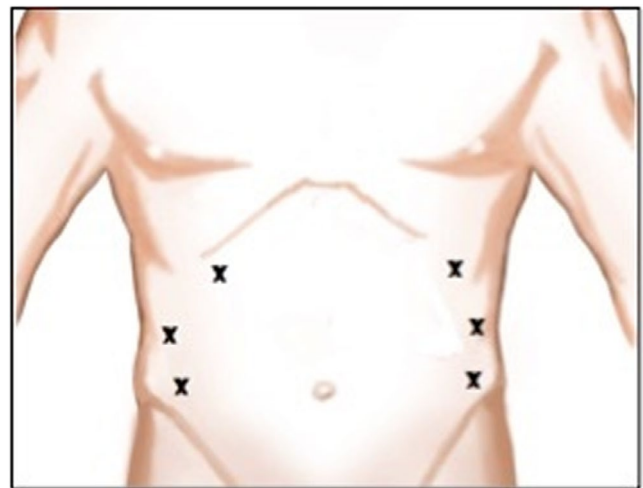


FIGURE 2 Tomography. Giant type 4 hiatal hernia

FIGURE 3 Botulinum toxin injection technique

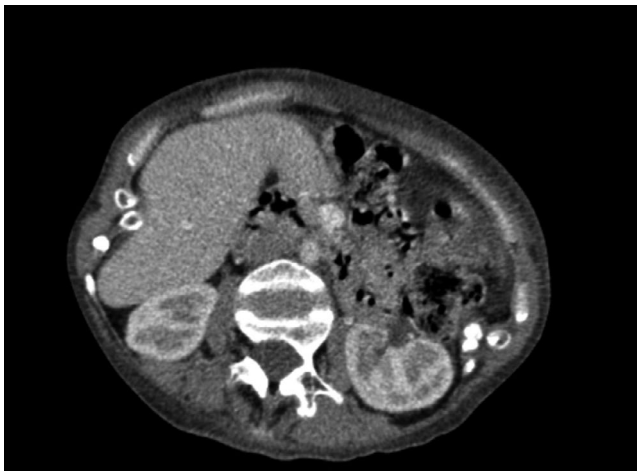
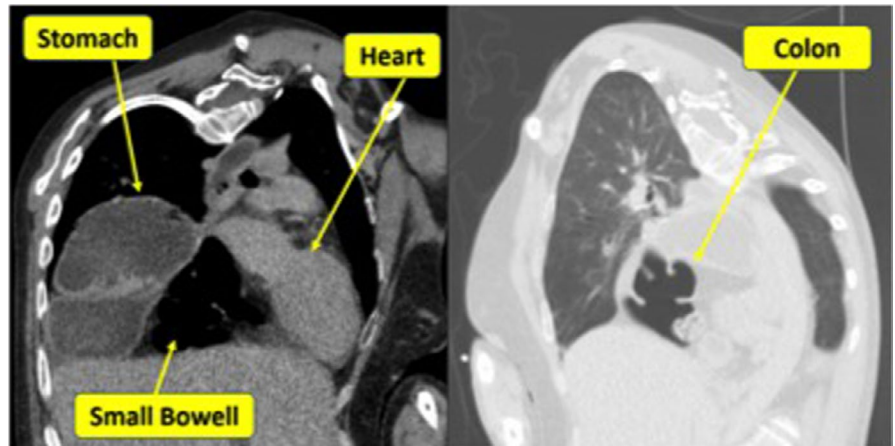
FIGURE 4 Abdominal wall musculature before the BTX injection

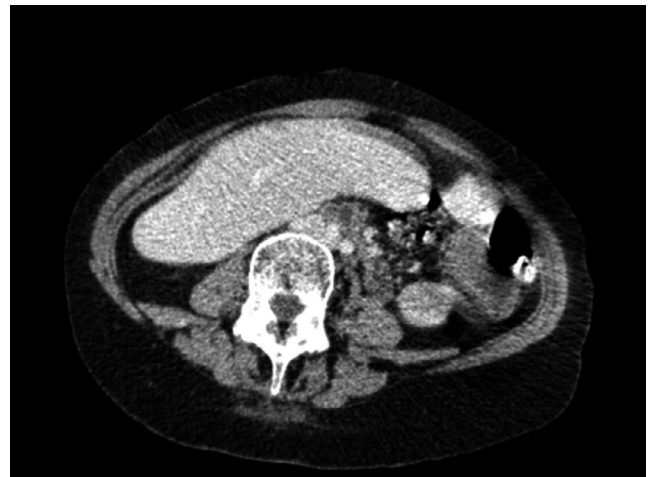

FIGURE 5 Abdominal wall musculature before the BTX injection

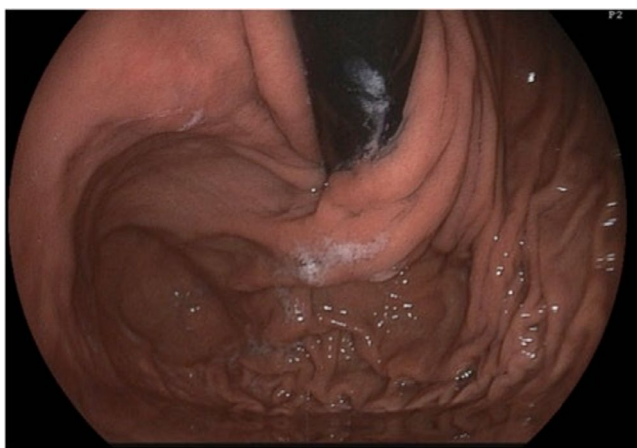


FIGURE 6 Endoscopy exam after six months of follow-up

ACKNOWLEDGMENT

Written informed consent has been obtained from patient's parents.

CONFLICT OF INTEREST

Authors have no conflict of interest.

AUTHORS' CONTRIBUTION

FT: analyzed and interpreted the data. ETB: acquired the data and drafted the article. SS and RC: drafted the paper. AAMN and ALGM: revised the paper critically for relevant intellectual content. RAAS and RZA: conceived and designed the study. IC: made final approval of the version to be submitted.

ORCID

Francisco Tustumi  <https://orcid.org/0000-0001-6695-0496>

Edno Tales Bianchi  <https://orcid.org/0000-0001-9643-2622>

Sérgio Szachnowicz  <https://orcid.org/0000-0002-6238-3532>

Antonio Afonso de Miranda Neto  <https://orcid.org/0000-0002-9439-9088>

André Luiz Gioia Morrell  <https://orcid.org/0000-0003-3971-349X>

Ricardo Zugaib Abdalla  <https://orcid.org/0000-0002-8700-0067>

Rubens Antonio Aissar Sallum  <https://orcid.org/0000-0003-1823-0042>

Ivan Cecconello  <https://orcid.org/0000-0002-3535-4170>

REFERENCES

- Migaczewski M, Grzesiak-Kuik A, Pędzwiatr M, Budzyński A. Laparoscopic treatment of type III and IV hiatal hernia—authors' experience. *Videosurg Other Miniinvasive Techn.* 2014;9(2):157.
- Felix VN, Yogi I, Senday D, et al. Post-operative giant hiatal hernia: a single center experience. *Medicine.* 2019;98(23):e15834.
- Weitzendorfer M, Pfandner R, Antoniou SA, Schwaiger-Hengstschläger C, Emmanuel K, Koch OO. Short-term results after laparoscopic repair of giant hiatal hernias with pledgeted sutures: a retrospective analysis. *Hernia.* 2019;23(2):397-401.
- Stringham JR, Phillips JV, McMurry TL, et al. Prospective study of giant paraesophageal hernia repair with 1-year follow-up. *J Thorac Cardiovasc Surg.* 2017;154(2):743-751.
- Zielinski MD, Goussous N, Schiller HJ, Jenkins D. Chemical components separation with botulinum toxin A: a novel technique to improve primary fascial closure rates of the open abdomen. *Hernia.* 2013;17(1):101-107.
- Soltanizadeh S, Helgstrand F, Jorgensen LJ. Botulinum toxin A as an adjunct to abdominal wall reconstruction for incisional hernia. *Plast Reconstr Surg Glob Open.* 2017;5:e1358.
- Armijo PR, Pokala B, Misfeldt M, Pagkratis S, Oleynikov D. Predictors of hiatal hernia recurrence after laparoscopic anti-reflux surgery with hiatal hernia repair: a prospective database analysis. *J Gastrointest Surg.* 2019;23(4):696-701.
- Riley DS, Barber MS, Kienle GS, et al. CARE 2013 explanations and elaborations: reporting guidelines for case reports. *J Clin Epidemiol.* 2017;1(89):218-235.
- Farooque F, Jacombs AS, Roussos E, et al. Preoperative abdominal muscle elongation with botulinum toxin A for complex incisional ventral hernia repair. *ANZ J Surg.* 2016;86(1-2):79-83.
- Ibarra-Hurtado TR, Nuño-Guzmán CM, Echeagaray-Herrera JE, Robles-Vélez E, de Jesús G-J. Use of botulinum toxin type a before abdominal wall hernia reconstruction. *World J Surg.* 2009;33(12):2553-2556.
- Bueno-Lledó J, Carreño-Saenz O, Torregrosa-Gallud A, Pous-Serrano S. Preoperative botulinum toxin and progressive pneumoperitoneum in loss of domain hernias—our first 100 cases. *Front Surg.* 2020;7(3):1-8.
- Catalán-Garza V, Peña-Soria MJ, Sáez-Carlin P, Cabeza-Gómez JJ, García-Fernández A, Torres-García AJ. Long-term results of botulinum toxin type A in complex abdominal wall repair and review of the literature. *Updates Surg.* 2020;72(4):1-6.
- Montecucco C, Schiavo G. Mechanism of action of tetanus and botulinum neurotoxins. *Mol Microbiol.* 1994;13(1):1-8.
- Le Page PA, Furtado R, Hayward M, et al. Durability of giant hiatus hernia repair in 455 patients over 20 years. *Ann R Coll Surg Engl.* 2015;97(3):188-193.

SUPPORTING INFORMATION

Additional supporting information may be found online in the Supporting Information section.

How to cite this article: Tustumi F, Bianchi ET, Szachnowicz S, et al. Preoperative botulinum toxin type A: A case report of a proposed new strategy for giant hiatal hernia management. *Clin Case Rep.* 2020;8:3411–3414. <https://doi.org/10.1002/ccr3.3416>