

Bone Morphogenetic Protein-2 and Demineralized Bone Matrix in Difficult Bony Reconstructions in Cleft Patients

Katelyn G. Makar, MD, MS
Steven R. Buchman, MD
Christian J. Vercler, MD, MA

Summary: Reconstruction of alveolar clefts includes fistula repair and bone grafting. However, bone is often harvested from the iliac crest or the skull, which can be associated with considerable donor site morbidity, and the failure rate may be as high as 20%. As such, some centers utilize bone morphogenetic protein (BMP)-2 to reconstruct the bony cleft. However, this remains an off-label use, and therefore we propose using BMP-2 only in patients with tenuous soft tissues, when the likelihood of graft failure is high. In four patients, we used BMP-2 with demineralized bone matrix (DBM) to reconstruct defects related to clefts—three patients had alveolar clefts, and the fourth patient was referred to us, with resorption of a necrotic premaxilla after premaxillary setback. In all cases, the decision was made to forego bone grafting intraoperatively given the poor quality of soft tissue and the increased risk of bone graft exposure. BMP-2 was infused onto a carrier and placed in the fistula, and Grafton DBM was then packed into the defect. In three cases, small amounts of bone from the piriform aperture were mixed with the BMP-2/DBM. After 3–7 months, all patients had generated bone in the clefts and did not require bone grafting. While we continue to prefer a “like with like” reconstruction, bone grafting has a high likelihood of failure in patients with suboptimal soft tissues or tight closures. We suggest that combining BMP-2 and DBM in higher risk patients is an excellent option to avoid bone graft loss and reoperation. (*Plast Reconstr Surg Glob Open* 2021;9:e3611; doi: [10.1097/GOX.0000000000003611](https://doi.org/10.1097/GOX.0000000000003611); Published online 22 June 2021.)

INTRODUCTION

Alveolar clefts in patients with cleft lip and/or cleft palate (CLCP) must be repaired to allow safe eruption of permanent dentition and closure of the associated fistula.¹ The standard procedure includes autogenous bone graft, most often taken from the iliac crest or the cranial vault.^{2,3} Unfortunately, this procedure has been associated with considerable donor site morbidity, with significant pain and problems with ambulation if iliac crest is used, which can prolong length of stay.⁴ Additionally, the failure rate of alveolar cleft bone grafting approaches 20%.¹

Given the potential for failure and donor site morbidity, alternatives have been sought. Various centers have utilized bone morphogenetic protein (BMP)-2 on a collagen carrier⁵ or in combination with demineralized bone matrix (DBM) for reconstruction.^{1,6} At high concentrations, BMPs stimulate de novo bone formation.¹ In comparison with bone grafting, BMP-2 has exhibited promise as an equivalent alternative with regard to bone healing and presents no donor site morbidity.^{1,5,6} While some advocate using BMP-2 in all repairs, this remains an off-label use. Therefore, we prefer to use BMP-2 in situations wherein the soft tissue is tenuous with an increased risk of bone graft exposure, graft loss, and reoperation.

PATIENTS AND METHODS

With approval from the institutional review board, we reviewed three patients with tenuous soft tissue surrounding their alveolar clefts who underwent reconstruction with Infuse BMP-2 and Grafton DBM. One patient had a “locked out” premaxilla with failed attempts at orthodontic expansion anteriorly. Another

From the Department of Surgery, University of Michigan, Ann Arbor, Mich.

Received for publication December 2, 2020; accepted March 18, 2021.

Copyright © 2021 The Authors. Published by Wolters Kluwer Health, Inc. on behalf of The American Society of Plastic Surgeons. This is an open-access article distributed under the terms of the Creative Commons Attribution-Non Commercial-No Derivatives License 4.0 (CCBY-NC-ND), where it is permissible to download and share the work provided it is properly cited. The work cannot be changed in any way or used commercially without permission from the journal.

DOI: [10.1097/GOX.0000000000003611](https://doi.org/10.1097/GOX.0000000000003611)

Disclosure: All the authors have no financial interest in relation to the content of this article.

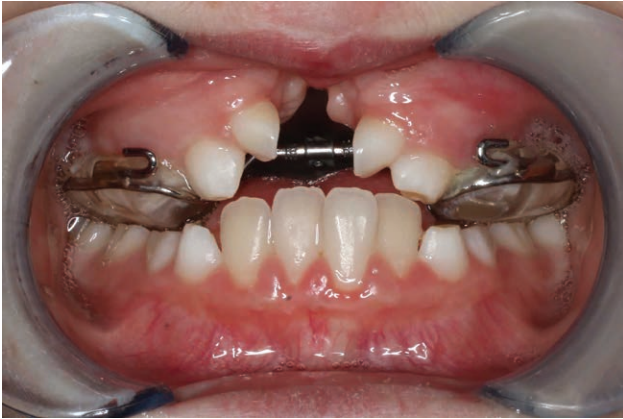

Fig. 1. Preoperative photograph of the fourth patient with necrosed premaxilla.

patient presented with a residual left alveolar cleft despite having undergone bone grafting at an outside institution. The third patient presented with bilateral alveolar clefts. In all three patients, the alveolar clefts extended so far posteriorly that a revision palatoplasty was also required. A fourth patient whose premaxilla necrosed and resorbed after premaxillary setback at an outside institution also underwent reconstruction of the premaxilla with BMP-2 and Grafton DBM (Fig. 1) (Medtronic, Minneapolis, Minn.).

Surgical Technique

During repair of the alveolus, repeated assessments of the soft tissue are made. If the closure is difficult or the soft tissue appears tenuous with increased risk for graft exposure, the decision is made intraoperatively to use BMP-2 with Grafton DBM. BMP-2 is infused onto a gel foam carrier and placed within the repaired fistula gap. Grafton DBM is then added for volume. In three cases, a small amount of bone from the piriform aperture was mixed with the BMP/DBM. Autologous bone was harvested from the nearby piriform. This bone was sometimes available due to an underlying anatomic abnormality. It was also

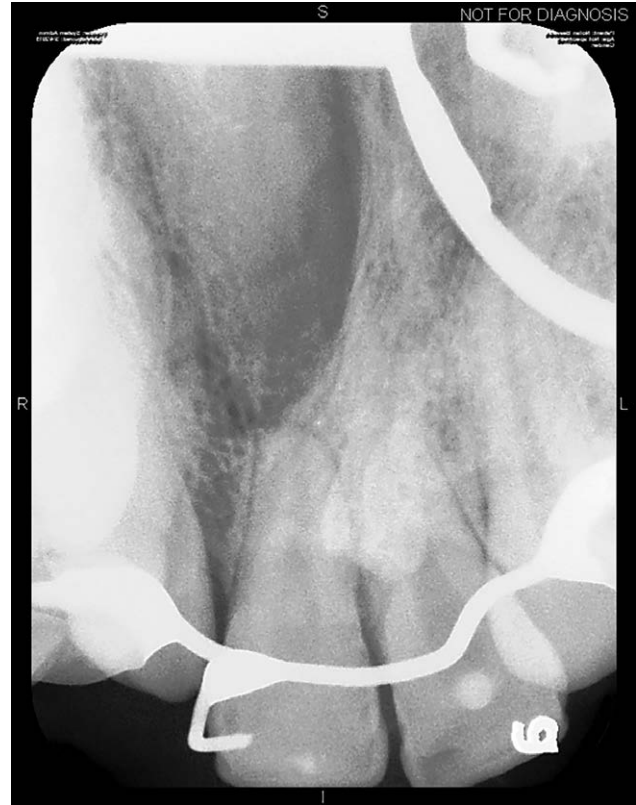


Fig. 3. Periapical film demonstrating bone generation in both clefts 4 years after repair.

occasionally harvested from the maxillary crest. This was in no way sufficient for an autologous reconstruction, but was rather used (if available) instead of additional demineralized bone matrix. The gingivoperiosteal flaps are then advanced over this area and closed.

In the patient who lost his premaxilla, the fistulas were closed in the usual fashion. Next, the BMP soaked carrier and DBM were packed into the large central defect. Gingival flaps were then advanced mesially and closed in a straight line.

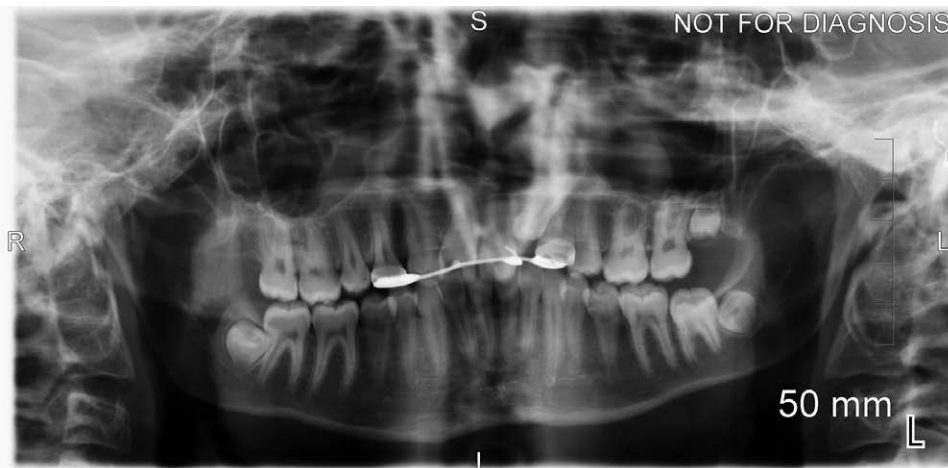


Fig. 2. Panorex film 4 years after bilateral alveolar cleft repairs using BMP-2 and DBM.

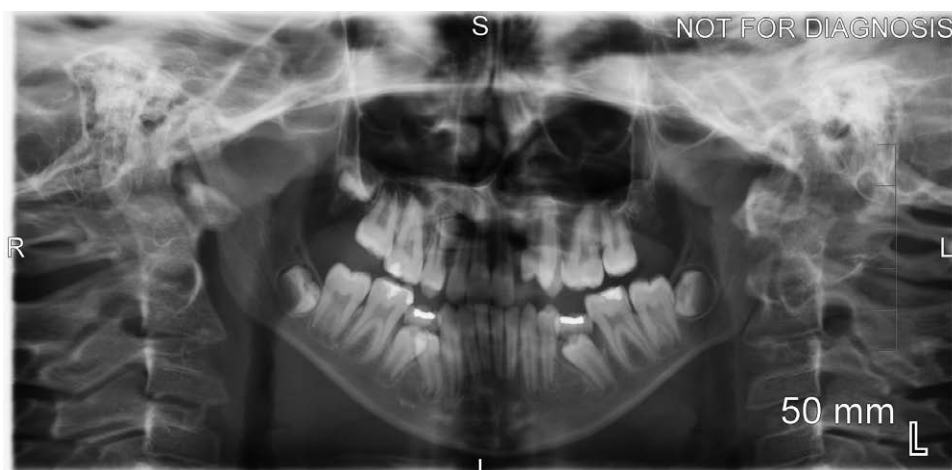

Fig. 4. Panorex film 5 months after left-sided alveolar cleft repair with BMP-2 and DBM.

RESULTS

The first patient with a locked out premaxilla exhibited complete bony healing on panorex imaging 3 months after surgery with no residual fistula on examination. He was able to resume orthodontic treatment, and follow-up panorex and occlusal films 4 years later (Figs. 2, 3) confirmed bone in the clefts. A panorex film obtained 5 months later on the second patient with a unilateral cleft demonstrated bone within the previous cleft (Fig. 4). In the third patient, clinical documentation noted that postoperative imaging demonstrated bony healing in bilateral clefts 7 months later. In the patient with the necrosed premaxilla, clinical documentation also noted that postoperative imaging revealed bone in the premaxilla area with descending permanent teeth after 4 months. None of these patients required additional bone grafting, and all were able to resume orthodontic treatment with successful movement of teeth into the area.

DISCUSSION

Reconstruction of cleft-related bony defects remains challenging in some patients, especially when the surrounding soft tissue is suboptimal. The gold standard has largely consisted of replacing “like with like” by utilizing bone graft, either from the iliac crest or the skull.^{3,6,7} However, donor site morbidity can be considerable, often causing pain that can merit a longer hospital stay.⁵ Additionally, bone graft can resorb as a result of exposure in patients with tenuous soft tissue closures, resulting in donor site morbidity and the need for reoperation.¹ Some advocate for a two-staged approach in difficult clefts, wherein the fistula is closed and bone grafting is performed a few months later.⁸ This approach has merit but mandates two operations with their attendant risks. The strategy of using BMP-2/DBM carries the significant benefit of avoiding a second operation as well as precluding any associated donor site morbidity.

In patients with robust soft tissue, we prefer a “like with like” approach and harvest bone graft for

reconstruction. The use of BMP-2 and DBM for this indication is off-label, and thus the complete risk profile remains unknown, which must be explained to parents. Prior work in orthopedic surgery demonstrated increased complications, including ectopic bone formation, with the use of BMP-2.⁹ Additionally, there is concern that BMP-2 may have tumorigenic properties, although the evidence for this is highly inconsistent.¹⁰ Thus, our follow up protocol consists of only annual cleft team appointments. It is also widely known that BMP-2 is correlated with increased swelling postoperatively, although this has had no impact on the quantity of graft we use intraoperatively or the incidence of dehiscence postoperatively.^{6,11} Therefore, when the chance of failure seems high intraoperatively, we maintain a low threshold for considering BMP-2 and DBM. Our experience indicates that this is a reasonable and often successful approach, without the need for bone grafting in the future. The “sine qua non” of successful repair is the ability to move teeth into the bone, which occurred in all four patients. Even if this approach is unsuccessful, it still allows for fistula repair and obviates the waste of graft, which could be performed later.

Despite the cost of these materials, the absence of donor site pain shortens hospital stay, which rendered BMP-2 more economical than bone grafting in one center.⁵ It also potentially obviates a second operation in a patient whose bone graft may fail, thus further reducing cost in high-risk situations. Therefore, in certain patients, reconstruction with BMP-2 and DBM may decrease waste of healthcare resources.

In conclusion, using BMP-2 and DBM for the repair of difficult alveolar clefts, or even reconstruction of an entire premaxilla, may be a reasonable and often successful option when soft tissue closure puts classic bone grafting at high risk for failure.

Christian J. Vercler, MD, MA
C.S. Mott Children's Hospital
1540 E. Medical Center Drive
Ann Arbor, MI 48109
E-mail: cvercler@med.umich.edu

REFERENCES

1. Francis CS, Mobin SSN, Lypka MA, et al. rhBMP-2 with a demineralized bone matrix scaffold versus autologous iliac crest bone graft for alveolar cleft reconstruction. *Plast Reconstr Surg.* 2013;131:1107–1115.
2. Santiago PE, Schuster LA, Levy-Bercowski D. Management of the alveolar cleft. *Clin Plast Surg.* 2014;41:219–232.
3. LaRossa D, Buchman S, Rothkopf DM, et al. A comparison of iliac and cranial bone in secondary grafting of alveolar clefts. *Plast Reconstr Surg.* 1995;96:789–97; discussion 798.
4. Rawashdeh MA, Telfah H. Secondary alveolar bone grafting: The dilemma of donor site selection and morbidity. *Br J Oral Maxillofac Surg.* 2008;46:665–670.
5. Dickinson BP, Ashley RK, Wasson KL, et al. Reduced morbidity and improved healing with bone morphogenetic protein-2 in older patients with alveolar cleft defects. *Plast Reconstr Surg.* 2008;121:209–217.
6. Hammoudeh JA, Fahradyan A, Gould DJ, et al. A comparative analysis of recombinant human bone morphogenetic protein-2 with a demineralized bone matrix versus iliac crest bone graft for secondary alveolar bone grafts in patients with cleft lip and palate: Review of 501 cases. *Plast Reconstr Surg.* 2017;140:318e–325e.
7. Horswell BB, Henderson JM. Secondary osteoplasty of the alveolar cleft defect. *J Oral Maxillofac Surg.* 2003;61:1082–1090.
8. Kim MJ, Lee JH, Choi JY, et al. Two-stage reconstruction of bilateral alveolar cleft using Y-shaped anterior-based tongue flap and iliac bone graft. *Cleft Palate Craniofac J.* 2001;38:432–437.
9. Poon B, Kha T, Tran S, et al. Bone morphogenetic protein-2 and bone therapy: Successes and pitfalls. *J Pharm Pharmacol.* 2016;68:139–147.
10. Tian H, Zhao J, Brochmann EJ, et al. Bone morphogenetic protein-2 and tumor growth: Diverse effects and possibilities for therapy. *Cytokine Growth Factor Rev.* 2017;34:73–91.
11. Yaremchuk K, Toma M, Somers M. Acute airway obstruction associated with the use of bone-morphogenetic protein in cervical spinal fusion. *Laryngoscope.* 2010;120(Suppl 4):S140.