




Since January 2020 Elsevier has created a COVID-19 resource centre with free information in English and Mandarin on the novel coronavirus COVID-19. The COVID-19 resource centre is hosted on Elsevier Connect, the company's public news and information website.

Elsevier hereby grants permission to make all its COVID-19-related research that is available on the COVID-19 resource centre - including this research content - immediately available in PubMed Central and other publicly funded repositories, such as the WHO COVID database with rights for unrestricted research re-use and analyses in any form or by any means with acknowledgement of the original source. These permissions are granted for free by Elsevier for as long as the COVID-19 resource centre remains active.



Contents lists available at ScienceDirect

Auris Nasus Larynx

journal homepage: www.elsevier.com/locate/anl

Case Report

COVID-19 presenting as acute epiglottitis: A case report and literature review

Shusuke Iwamoto¹, Mitsuo P. Sato^{1,*}, Yujiro Hoshi, Naoki Otsuki, Katsumi Doi

Department of Otorhinolaryngology, Kindai University Faculty of Medicine, Osaka-Sayama, Osaka 589-8511, Japan

ARTICLE INFO

Article history:

Received 23 September 2021

Accepted 13 December 2021

Available online xxx

Keywords:

COVID-19

Acute epiglottitis

Pneumonia

Tuberculous laryngitis

ABSTRACT

Coronavirus disease 2019 (COVID-19) occasionally causes acute laryngitis, requiring emergency treatment. Understanding the characteristic laryngeal findings can help diagnose COVID-19 earlier, prevent worsening infection, and properly manage airway obstruction. Herein, we report the case of a 44-year-old male with acute epiglottitis likely caused by COVID-19. On presentation, chest computed tomography (CT) showed no signs of pneumonia. However, the larynx had extensive necrotic-like erosive lesions resembling those of tuberculous laryngitis. COVID-19 was diagnosed by reverse-transcription polymerase chain reaction, and secondary bacterial superinfections were suspected after blood testing. The symptoms improved after administration of antibiotics (sulbactam sodium/ampicillin sodium), steroids (dexamethasone), and favipiravir. The patient developed a high fever on the sixth day of hospitalization, and pneumonia was identified on CT. Various culture tests, including tuberculosis, were negative. Thus, remdesivir was administered for COVID-19-induced pneumonia. The patient gradually recovered, was transferred to another hospital, and was discharged on the 35th day of hospitalization. Six previous case reports of COVID-19-induced acute epiglottitis suggested that acute epiglottitis preceded the onset of pneumonia. The laryngeal findings from this report may be useful for diagnosing COVID-19 that does not cause pneumonia and for bringing attention to pneumonia after a COVID-19 diagnosis.

© 2021 Oto-Rhino-Laryngological Society of Japan Inc. Published by Elsevier B.V. All rights reserved.

1. Introduction

Coronavirus disease 2019 (COVID-19), caused by severe acute respiratory syndrome coronavirus 2 (SARS-CoV-2), is a rapidly progressing respiratory disease that also affects the upper aerodigestive tract via angiotensin-converting enzyme 2 or transmembrane protease/serine subfamily member 2 receptors [1,2], causing a sore throat and odynophagia. There are reports of COVID-19-induced acute laryngitis requiring

emergency treatment, indicated by acute epiglottitis in adults and croup in infancy [3–9]. Frequently, this requires urgent airway management, which generates aerosols and increases the risk of spreading the infection. Thus, understanding the laryngeal abnormalities associated with COVID-19 is essential. However, few laryngo-fiberscope images of COVID-19-induced acute laryngitis have been presented [5]. Additionally, the time between acute laryngitis onset and pneumonia has not been reviewed. Herein, we report a case of COVID-19-induced acute epiglottitis necessitating immediate hospitalization with subsequent pneumonia. Further, we reviewed previous reports on COVID-19-induced acute epiglottitis in adults to understand whether epiglottitis precedes the onset of pneumonia.

* Corresponding author at: Department of Otorhinolaryngology, Kindai University Faculty of Medicine, Ohno-higashi 377-2, Osaka-sayama-city, Osaka 589-8511, Japan.

E-mail address: qqd755pd@spice.ocn.ne.jp (M.P. Sato).

¹ These authors contributed equally to this work.

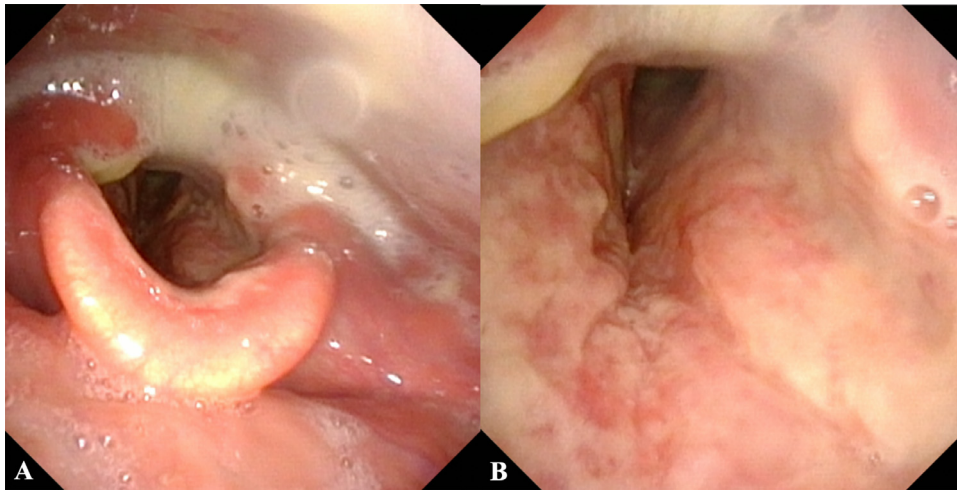


Fig. 1. Laryngo-fiberscope findings. Reddish and erosive lesions predominantly occurred inside the larynx. The arytenoid region was also reddish and swollen, and saliva pooling occurred in the pyriform sinus (A). Necrotic-like erosive lesions extended to the subglottic space (B).

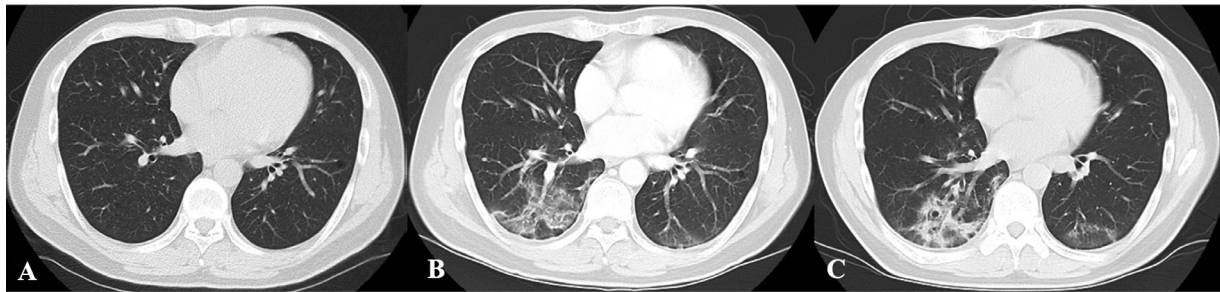


Fig. 2. Non-contrast chest computed tomography. Pneumonia was not found on presentation (A) but emerged on the sixth day of hospitalization (B), improved gradually, and finally became scarified (C).

2. Case presentation

A 44-year-old man complaining of sore throat and odynophagia was referred to our hospital after receiving an intravenous drip of ceftriaxone (2 g) for acute pharyngitis. The patient had no medical comorbidities and was a non-smoker. On presentation, the patient's vital signs were: body temperature, 37.1°C; heart rate, 122 beats per min; blood pressure, 138/88 mm Hg; and peripheral venous blood oxygen saturation (SpO₂) value, 99% in room air. There were no abnormalities in the pharynx or neck. The laryngeal fiberscope showed entirely necrotic-like erosions within the larynx, presenting as a red to white coarsely roughened surface that extended from the laryngeal side of the epiglottis to the subglottis and a red swollen mucosa with erosions in the bilateral arytenoid regions. Vocal cord paralysis was not observed (Fig. 1). Laboratory data revealed a white blood cell (WBC) count of 10 580/ μ L and a C-reactive protein (CRP) level of 14.075 mg/dL. Non-contrast chest computed tomography (CT) indicated no signs of pneumonia (Fig. 2A). However, a nasopharyngeal swab tested positive for SARS-CoV-2 (N501Y type) by reverse-transcription polymerase chain reaction (RT-PCR), necessitating immediate hospitalization to manage the compromised airway. Fig. 3 presents the treatment course. Sulbactam sodium/ampicillin sodium (SBT/ABPC) was administered for suspected secondary bacterial superinfections, and dexa-

methasone and favipiravir were administered for COVID-19. The laryngeal lesions and laboratory data improved, and the SpO₂ did not decrease. However, fever resurged on the sixth day of hospitalization, and the WBC count and CRP level deteriorated. Culture tests, including tests for *Mycobacterium*, and rapid antigen tests for adenovirus, respiratory syncytial virus, and group A streptococci were performed on blood and sputum; all were negative. However, enhanced chest CT identified pneumonia (Fig. 2B). COVID-19-induced pneumonia was diagnosed and treated with remdesivir [10]. The patient's pneumonia improved (Fig. 2C), and he was transferred to another hospital and finally discharged on the 35th day of hospitalization.

3. Discussion

We report a case of acute epiglottitis caused by COVID-19, requiring immediate patient hospitalization owing to a compromised airway. Fiberoptic laryngoscopy revealed a diffusely erythematous larynx with necrotic-like erosions; this process included the subglottic mucosa and arytenoids. Table 1 provides information from a review of six cases of acute epiglottitis caused by COVID-19. The descriptive laryngeal findings were similar to those of common acute epiglottitis. Only one report presented an image of acute epiglottitis; the larynx was partially affected by erosive lesions [5]. These results suggest

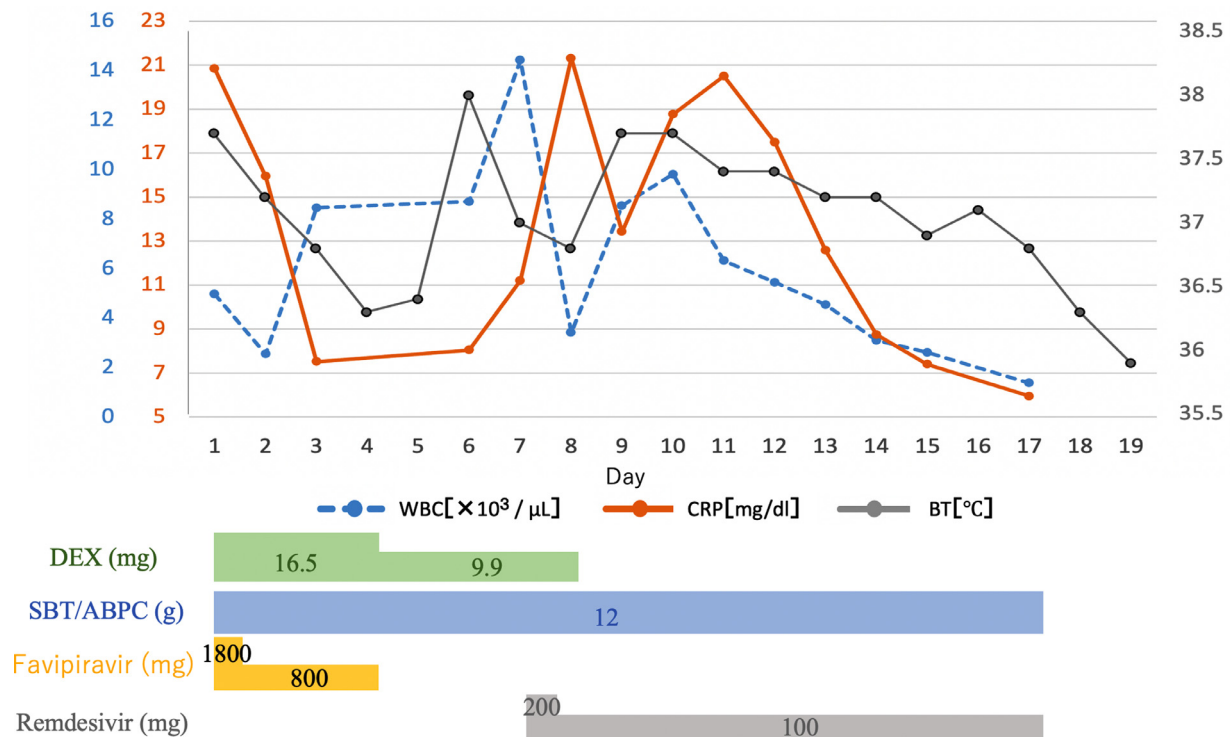


Fig. 3. The treatment progress. COVID-19-induced pneumonia occurred on the sixth day of hospitalization. Remdesivir was administered, and the patient improved and was transferred to another hospital on the 19th day. WBC, white blood cells; CRP, C-reactive protein; BT, body temperature.

that necrotic-like erosive lesions may characterize COVID-19-induced acute laryngitis. Further, the lesions of acute laryngitis are similar to those of tuberculous laryngitis [11]. Thus, diagnosis requires culture tests, as in our patient’s case. Regarding the time course between acute epiglottitis and pneumonia in Table 1, acute epiglottitis occurred before pneumonia in two of three cases. The onset of acute epiglottitis also preceded pneumonia in our case. Thus, these laryngeal findings may be associated with a COVID-19 diagnosis before the onset of pneumonia. Although RT-PCR is the gold standard for diagnosing COVID-19, it is time-consuming and occasionally provides false negative results. Therefore, a comprehensive diagnosis should be made based on the patient’s general condition, symptoms, and other examinations. Chest CT is the most informative tool for diagnosing COVID-19, but is less informative for cases without or before the onset of pneumonia. In particular, there is limited time for examinations in patients with acute epiglottitis requiring emergency treatment, in whom the airway must be ensured before diagnostic test results are complete. As such, understanding the laryngeal findings of COVID-19-induced acute epiglottitis allows for earlier treatment and prevents worsening infection. More cases must be analyzed for confirmation of these findings, as only a few studies have been reported.

As Table 1 shows, five of six patients required airway ensurance; four patients underwent tracheotomies, and one patient was intubated. In our patient’s case, we would have attempted to perform intubation first if severe dyspnea had developed, since the epiglottis was not swollen. Additionally, an operating room with negative pressure was prepared in the event that tracheostomy was necessary. As COVID-19-

induced acute epiglottitis can result in pneumonia and the need to ensure the airway, physicians should make appropriate provisions for possible emergency management [12]. The extent of prophylactic airway management needed is difficult to determine; however, we suggest that the efficacy of steroids for a compromised airway should be confirmed first, in conjunction with hourly laryngeal examinations in the acute phase. Compared to case management for common acute epiglottitis, in which the epiglottis is swollen, we recommend performing tracheotomy earlier for COVID-19-induced acute epiglottitis.

We perform PCR testing for COVID-19 on all patients to be hospitalized, in compliance with infection-preventive measures. Furthermore, full personal protective equipment (PPE), such as N-95 masks, gowns, caps, eye protection, and gloves, are used in ambulatory practice and treatment of inpatients who undergo procedures that carry the risk of aerosol generation. All medical team members are required to wear full PPE under conditions in which aerosols may be generated, such as using a laryngeal fiberoptic. This patient had a mild fever; therefore, he was treated in a room adjusted with negative pressure in a different ward.

SARS-CoV-2 can lead to secondary bacterial infections. A meta-analysis of 3338 patients identified secondary bacterial infections in 6.9 % of COVID-19 patients [13]. We suspected that our patient had a secondary bacterial infection based on a neutrophil-dominated inflammatory reaction and susceptibility to SBT/ABPC. In the six reports of COVID-19-induced acute epiglottitis, all patients received antibiotics and survived. Therefore, we recommend administering antibiotics and other medications, including steroids, for COVID-19-induced acute epiglottitis leading to airway obstruction.

Table 1. A review of six cases of acute epiglottitis caused by COVID-19.

Author	Age	Gender	Smoking	Laryngeal findings	Pneumonia	Antibiotics	Steroids	Airway management
Fondaw, 2020	60	Male	+	Erythematous, purulent epiglottitis*	+	+	-	Tracheotomy
Embercy, 2021	53	Male	-	Swollen, erythematous and non-purulent epiglottitis	None	+	+	Tracheotomy
Renner, 2021	29	Male	Unknown	Hyperemic, swollen epiglottitis with necrotic-like lesions**	Unknown	+	-	Tracheotomy
Smith, 2021	43	Male	+	Reddish and swollen epiglottitis	Unknown	+	+	Inubation
Cordial, 2021	49	Male	Unknown	Edematous and suppurative epiglottitis*	+	+	+	Tracheotomy
Alqaisi, 2021	26	Female	Unknown	Edematous epiglottitis, tongue base, and arytenoid	+	+	+	None

* Laryngo-fiberscopy was not used.

** An image was published in the paper.

4. Conclusion

COVID-19-induced acute epiglottitis may precede pneumonia. Thus, understanding the laryngeal findings may prevent worsening infection.

Funding statement

No funds, grants, or other support was received.

Declaration of Competing Interest

The authors have no conflicts of interest to declare.

Acknowledgments

We would like to thank Editage (www.editage.com) for English language editing.

References

- [1] Oz M, Lorke DE, Kabbani N. A comprehensive guide to the pharmacologic regulation of angiotensin converting enzyme 2 (ACE2), the SARS-CoV-2 entry receptor. *Pharmacol Ther* 2021;221:107750. doi:10.1016/j.pharmthera.2020.107750.
- [2] Sato T, Ueha R, Goto T, Yamauchi A, Kondo K, Yamasoba T. Expression of ACE2 and TMPRSS2 proteins in the upper and lower aerodigestive tracts of rats: Implications on COVID 19 infections. *Laryngoscope* 2021;131:E932–9. doi:10.1002/lary.29132.
- [3] Fondaw A, Arshad M, Batool S, Robinson B, Patel T. COVID-19 infection presenting with acute epiglottitis. *J Surg Case Rep* 2020;2020:rjaa280. doi:10.1093/jscr/rjaa280.
- [4] Embercy J, Velala SS, Marshall B, Hassan A, Meghjee SP, Malik MJ, et al. Acute epiglottitis due to COVID-19 infection. *Eur J Case Rep Intern Med* 2021;8:002280. doi:10.12890/2021_002280.
- [5] Renner A, Lamminmäki S, Ilmarinen T, Khawaja T, Paajanen J. Acute epiglottitis after COVID-19 infection. *Clin Case Rep* 2021;9:e04419. doi:10.1002/ccr3.4419.
- [6] Smith C, Mobarakai O, Sahra S, Twito J, Mobarakai N. Case report: epiglottitis in the setting of COVID-19. *IDCases*. ID 2021;24:e01116. doi:10.1016/j.idcr.2021.e01116.
- [7] Cordial P, Le T, Neuenschwander J. Acute epiglottitis in a COVID-19 positive patient: a case report. *Am J Emerg Med* 2021. <http://dx.doi.org/10.1016/j.ajem.2021.06.077>, Jul 7:S0735-6757(21)00567-2.
- [8] Alqaisi S, Almomani A, Alwakeel M, Akbik B. 239: epiglottitis case report: a unique presentation of COVID-19 infection. *Crit Care Med* 2021;49:105. doi:10.1097/01.ccm.0000726844.46189.61.
- [9] Venn AMR, Schmidt JM, Mullan PC. Pediatric croup with COVID-19. *Am J Emerg Med* 2021;43 287.e1–287.e3. doi:10.1016/j.ajem.2020.09.034.
- [10] Spinner CD, Gottlieb RL, Criner GJ, Arribas López JR, Cattelan AM, Soriano Viladomiu A, et al. Effect of remdesivir vs standard care on clinical status at 11 days in patients with moderate COVID-19: a randomized clinical trial. *JAMA* 2020;324:1048–57. doi:10.1001/jama.2020.16349.
- [11] Zang J, Tian Y, Jiang X, Lin XY. Appearance and morphologic features of laryngeal tuberculosis using laryngoscopy: a retrospective cross-sectional study. *Medicine (Baltimore)* 2020;99:e23770. doi:10.1097/MD.00000000000023770.
- [12] Naunheim MR, Zhou AS, Puka E, Franco RA Jr, Carroll TL, Teng SE, et al. Laryngeal complications of COVID-19. *Laryngoscope Investig Otolaryngol* 2020;5:1117–24. doi:10.1002/lio2.484.
- [13] Langford BJ, So M, Raybardhan S, Leung V, Westwood D, MacFadden DR, et al. Bacterial co-infection and secondary infection in patients with COVID-19: a living rapid review and meta-analysis. *Clin Microbiol Infect* 2020;26:1622–9. doi:10.1016/j.cmi.2020.07.016.