



## Case report

## Gallbladder lymphangioma simulating liver hydatid cyst: A case report

Osama N. Dukmak<sup>a,\*</sup>, Fajr M.A. Sarhan<sup>a</sup>, Saad Mufid Ali Mohammad<sup>a</sup>, Mohammad Emar<sup>b</sup>, Rashad Al Zaro<sup>b</sup>, Rafiq M.A. Salhab<sup>b</sup>

<sup>a</sup> Faculty of Medicine, Al-Quds University, Jerusalem, Palestine

<sup>b</sup> Al-Ahli Hospital, Hebron, Palestine

## ARTICLE INFO

## Keywords:

Gallbladder lymphangioma

Case report

Hydatid cyst

## ABSTRACT

**Introduction and importance:** Gallbladder lymphangiomas are very-rare, yet benign tumors that start developing in early life. Those tumors often go unnoticed until adulthood as they grow into a larger size or a complication happens. Despite its rarity, suspicion for the diagnosis should be maintained by the physicians.

**Case presentation:** A 14-year-old female patient presented to the hospital complaining of right upper quadrant abdominal pain of one month duration. Physical examination showed mild upper quadrant tenderness. Serology testing for the patient only showed eosinophilia. Computed tomography showed a large non-enhancing cystic lesion attached to the gallbladder. Presumptive diagnosis of hydatid cyst was made, and the patient was treated accordingly. Histological analysis of mass showed dilated lymphatic vessels, hence the shift in diagnosis towards a lymphangioma was made.

**Clinical discussion:** Gallbladder lymphangioma are usually asymptomatic, but they can present with pain, nausea and vomiting. Multiple complications had been reported including compression of the nearby structures, intra-abdominal infection, rupture, torsion or hemorrhagic transformation. Surgical removal of the mass is the treatment of choice.

**Conclusions:** Right upper quadrant pain can be the presenting symptom of liver pathology. Histological assessment is needed to confirm the diagnosis which will show dilated lymphatic vessels.

## 1. Introduction

Lymphangiomas are rare, benign tumors of the lymphatic system that develop in patients at age of 5 years or younger. Those tumors are usually asymptomatic, but can enlarge to cause symptoms at an older age [1]. There have been 10 reported cases of gallbladder lymphangiomas making it a very rare diagnosis [1–4]. Gallbladder lymphangiomas can present with nausea, vomiting and fullness. Complications such as hemorrhage, infection, perforation and torsion can happen [5].

In this article we present a case of coincidental diagnosis of gallbladder lymphangioma after a surgical removal of presumed hydatid cyst in a 14-year-old patient. We highlight the approach to treatment, histological and radiological pictures and the diagnostic challenges.

This paper has been reported in-line with the SCARE 2020 criteria [6].

## 2. Case presentation

A previously healthy 14-year-old female patient presented to the hospital with a right upper quadrant abdominal pain of one month duration. The pain was of a gradual onset, colicky in nature, with no radiation. It was associated with nausea, but not with jaundice, itching, change in stool and urine color, fever, chills or change in mental status. The patient had no history of constipation, bleeding per rectum, intermittency, dripping, fever and chills. The patient's medical and surgical histories were non-remarkable. No known food or drug allergies were noted. No smoking history was noted. The patient's family history didn't show any notable medical diseases.

On the physical examination, the patient looked well, oriented to time, and place. No jaundice, pallor or cyanosis was noted. Vital signs were as follows: Blood pressure of 108/72 mm Hg, heart rate of 71 beats/min, temperature of 36.3 °C, with a respiratory rate of 16 breaths/min. No chest wall tenderness on palpation, chest and cardiac auscultation were non remarkable. Abdominal examination showed mild right

\* Corresponding author at: Al-Quds University-School of Medicine, Abu-Dis, East Jerusalem, Palestine.

E-mail address: [Osama.dukmak112@hotmail.com](mailto:Osama.dukmak112@hotmail.com) (O.N. Dukmak).

upper quadrant tenderness, with no palpable hepatosplenomegaly. No appreciable ascites was seen.

Serological testing only showed eosinophilia of 3.11, and a borderline bilirubin level of 1.2 mg/dl. Alkaline phosphatase, aspartate aminotransferase, and electrolytes panel were normal.

A decision for abdominal computed tomography (CT) with oral and IV contrast was made (Fig. 1.A and B), and showed gallbladder wall enhancement with a large non-enhancing cystic lesion that measured 12\*8 cm, this mass had no calcification or clue of rupture. No intra or extra-biliary dilation was noted.

Presumptive diagnosis of hydatid cyst was made and the patient was started on albendazole for one month duration, and a decision for surgical resection of the mass was made after a month of albendazole usage.

The patient successfully completed the albendazole course with no complications during the treatment period. The patient was then referred to the hospital to commence with the treatment plan.

A surgical right subcostal incision was made, and the peritoneum was opened. Adhesions had to be lysed prior to the full visualization of the cyst. Intraoperatively, the cyst had a thin wall that originates from the inferior liver surface and was adhering to the stomach wall. The mass was filled with clear fluid (Fig. 2.A). The gallbladder wall was impeded in the mass (Fig. 2.B). The presumed hydatid cyst was not found and a different type of cysts was found instead. The entire cyst and gallbladder were removed and peri cystectomy was done according to a dissection plan.

The resected pathology (Figs. 3.A and B) showed a cystic mass measuring 12 \* 8 cm. The wall thickness was 0.2 cm, and the gallbladder measured 6 \* 3 cm. The serosal cystic lesion measured 5 \* 3 \* 0.3 cm.

Biopsy from the lesion showed a thin-walled cyst composed of many dilated lymphatic spaces (Fig. 4.A and B). Immunohistochemical testing was not done.

The diagnosis was shifted from the hydatid cyst to cystic lymphangioma, which was not expected due to the rarity of this cyst.

The post-surgical course of the patient showed a healing subcostal scar. No postoperative complications were noted. The patient was advised to follow up in the general surgery clinic after the discharge.

### 3. Clinical discussion

Lymphangiomas are rare, benign tumors of the lymphatic system that usually develop in children of 5 years of age and younger. Because they are asymptomatic until the mass enlarges to cause symptoms, most lymphangiomas are diagnosed at adulthood incidentally [1]. Lymphangiomas may appear in any organ of the body except the brain. It more commonly involves the skin and soft tissue of the head and neck (95 %), and lymphangioma occurring in the gastrointestinal tract is uncommon [1].

Lymphangiomas involving the gallbladder are extremely rare, representing only 0.8 %–1 % of all intra-abdominal lymphangiomas [1–3].

To the best of our knowledge, only 10 cases of gallbladder lymphangioma have been reported worldwide as of March 2012 [4].

The clinical presentations of gallbladder lymphangioma are either asymptomatic or cause pain, nausea, vomiting, and abdominal fullness. Our patient presented with colicky right upper quadrant pain of a one-month duration, and these symptoms were mostly caused by the mass effect of the huge cystic lymphangioma of the gallbladder against the surrounding structures. It's important to notice that gallbladder lymphangioma could present with complications such as hemorrhage, infection, perforation, torsion and rupture. In 2012, a case of hemorrhagic gallbladder lymphangioma was reported [5]. However, there are no clinical features that can be used to differentiate gallbladder lymphangioma from the other intra-abdominal masses [7].

Preoperative diagnosis of gallbladder lymphangioma remains difficult because it is very rare, and sometimes imaging studies such as US and CT cannot distinguish it from other lesions [8]. CT scan with IV contrast done for our patient showed non-enhancing large cystic lesion, and the appearance was suggesting a liver hydatid cyst as it was difficult to observe the origin of the cyst, thus it's somewhat difficult to diagnose a lymphangioma before a surgical excision with a follow-up histological identification.

The use of advanced imaging tools such as magnetic resonance imaging or magnetic resonance cholangiopancreatography may be helpful in predicting the diagnosis of gallbladder lymphangioma before histological identification. One recent report described the MRI findings of gallbladder lymphangiomas based on the findings of splenic cystic lymphangiomas [9]. This report suggested that characteristic magnetic

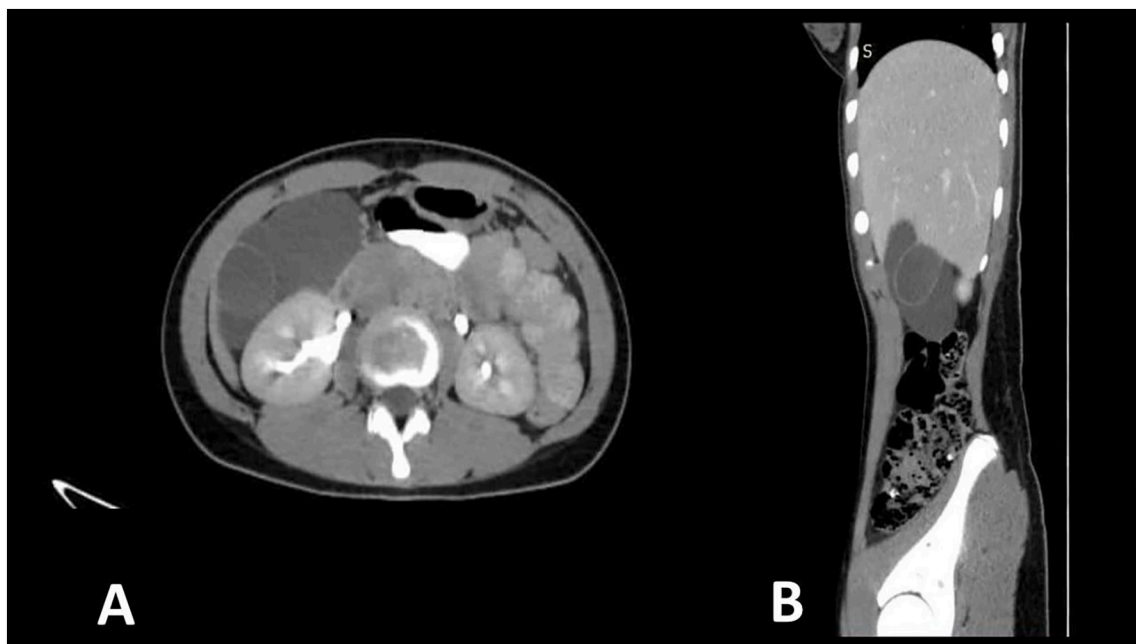


Fig. 1. A: Axial CT scan showing large non-enhancing lesions, B: coronal CT scan with oral and IV contrast.

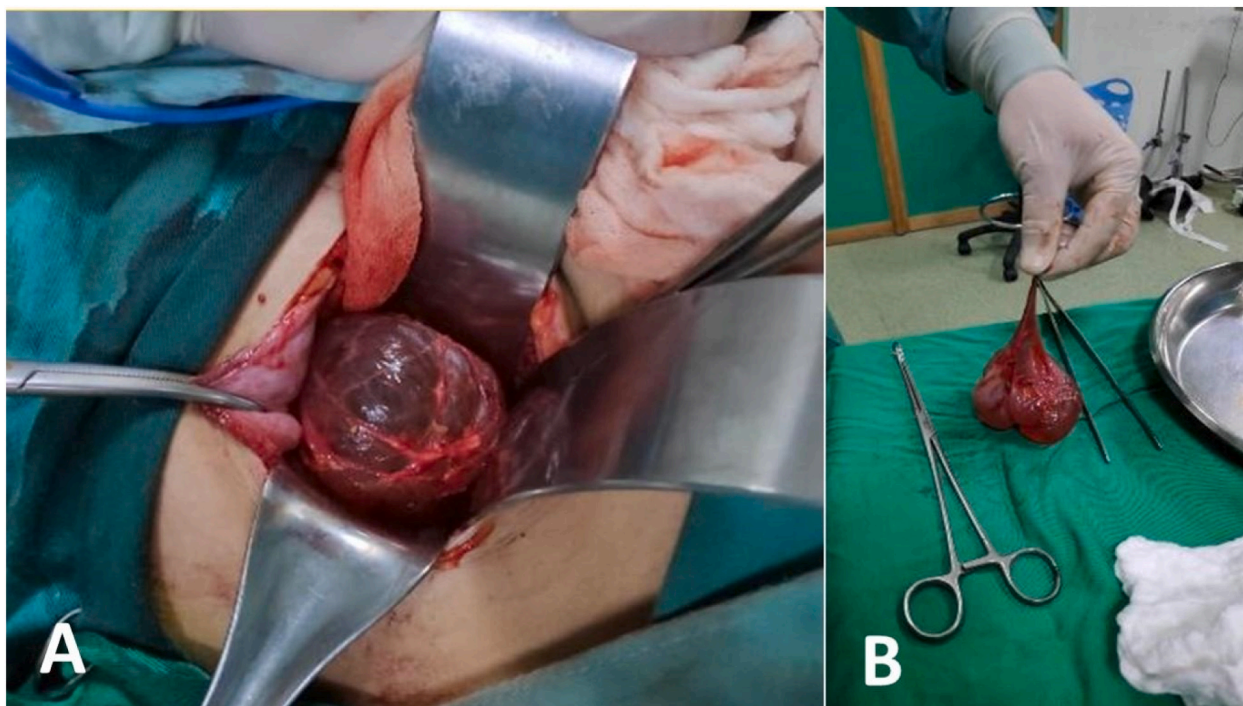


Fig. 2. A: intraoperative image for the cyst, B: cyst after resection.

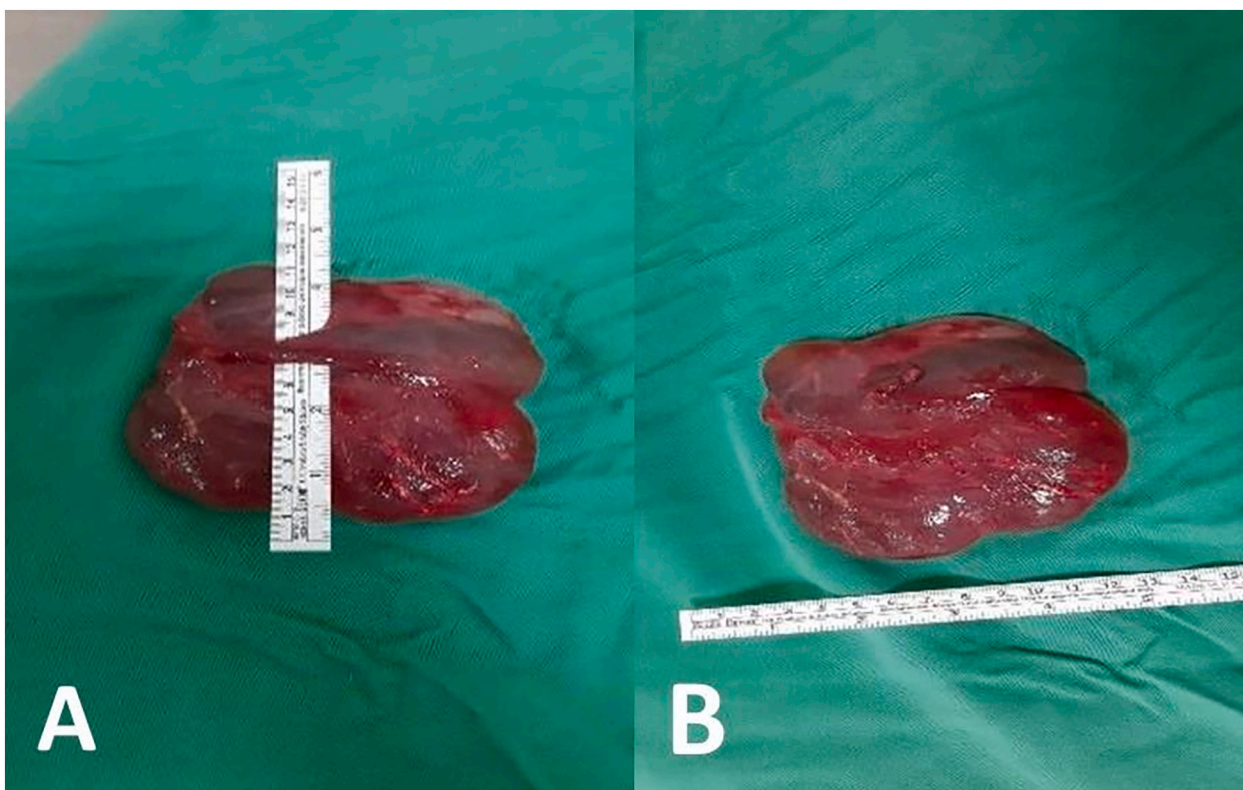


Fig. 3. A: The measured length is 12 cm. B: The measured width is 8 cm.

resonance findings would be very helpful for the differential diagnosis of gallbladder lymphangioma.

In terms of histology, lymphangiomas are classified as simple, cavernous or cystic [10]. The histological characteristics of a cystic lymphangioma can include the presence of lymphoid tissue in the cyst

wall, flat endothelial lining of the cyst rather than the cuboidal or columnar epithelium, and the presence of smooth muscle in the cyst wall [10]. The histological findings of our case were consistent with these features.

Regarding the management of gallbladder lymphangioma, complete



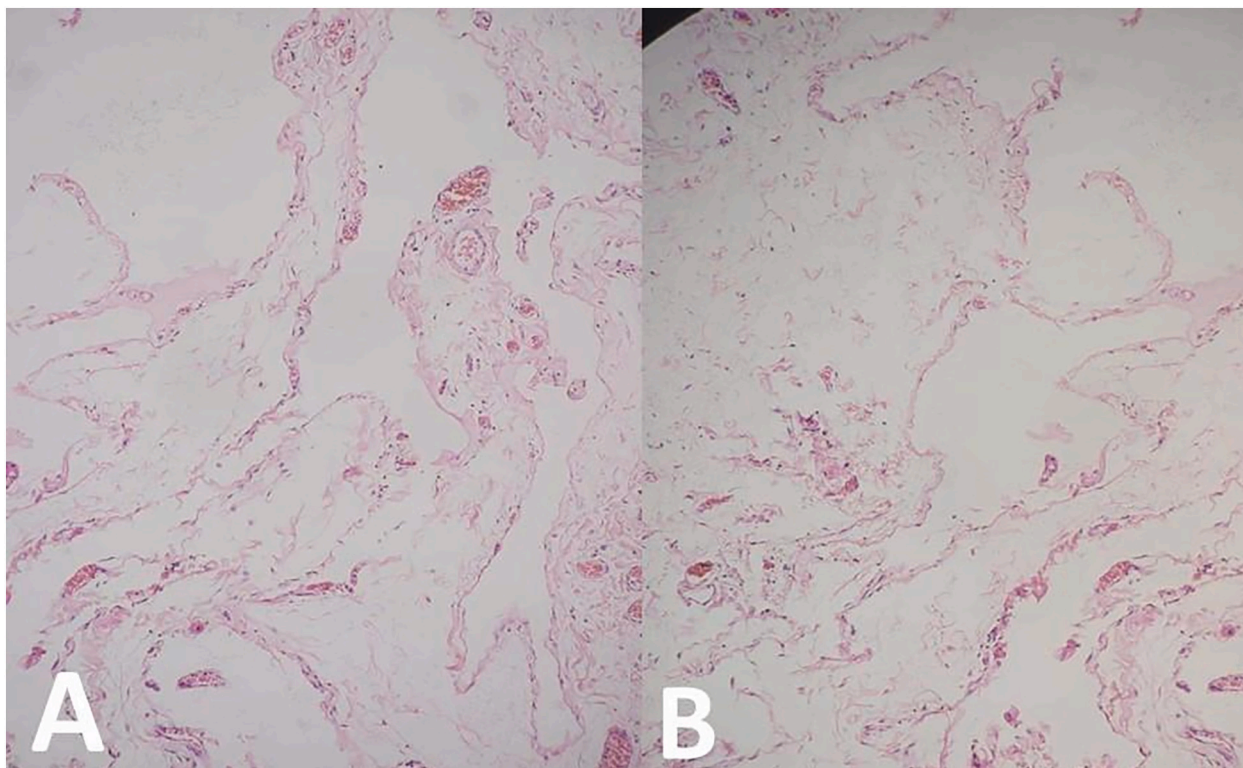


Fig. 4. A shows the dilated lymphatic spaces, B: shows the dilated lymphatic spaces.

surgical excision is the treatment of choice, and it should be done as soon as the diagnosis is made because if the mass grows large to compress surrounding structures and vessels, it can cause significant symptoms and comorbidities. Furthermore, intra-abdominal infection, rupture, torsion or hemorrhage can occur as a complication of the already present mass [5]. In our case, the mass and gallbladder were excised and peri-cystectomy was done. Recurrence has been reported with incomplete resection, but if the lesion is completely resected, long-term prognosis is excellent [1].

We report here on the first case of cystic lymphangioma of the gallbladder in Palestine.

#### 4. Conclusions

This case illustrates that diagnosing gallbladder lymphangioma can be a hurdle. This rare entity requires a better diagnostic modality for earlier diagnosis prior to the surgery. The latest update in literature mentioned that magnetic resonance imaging or magnetic resonance cholangiopancreatography are showing promising steps in diagnosing gallbladder lymphangioma prior to the histological assessment. Complete surgical resection is the current gold standard of treatment.

#### Consent

Written informed consent was obtained from the patient for Publication of this case report and accompanying image. A copy of the informed consent is available for review by the Editor-in-Chief of this journal on request.

#### Provenance and peer review

Not commissioned, externally peer-reviewed.

#### Ethical approval

N/A.

#### Funding

N/A.

#### Guarantor

Dr Rafiq Salhab.

#### Research registration number

- Name of the registry: N/A.
- Unique Identifying number or registration ID: N/A
- Hyperlink to your specific registration (must be publicly accessible and will be checked): N/A.

#### CRediT authorship contribution statement

Writing the manuscript: Osama N. Dukmak, Fajr M A Sarhan, Saad Mufid Ali Mohammad

Designing the figures: Mohammad Emar, Rafiq Salhab

Reviewing & editing the manuscript: Osama N. Dukmak, Fajr Sarhan, Saad Mohammad, Rafiq Salhab, Mohammad Emar, Rashad Zaro.

#### Declaration of competing interest

The authors declare no conflict of interest.

#### Acknowledgements

Images/figures/photos are suitably anonymized with no patient information or means of identifying the patient.

We would like to thank Dr. Motaz Natsheh for the histopathological interpretation.

## References

- [1] J.K. Kim, K.S. Yoo, J.H. Moon, K.H. Park, Y.W. Chung, K.O. Kim, Gallbladder lymphangioma: a case report and review of the literature [cited 2022 Apr 10], *World J. Gastroenterol.* 13 (2) (2007 Jan 14) 320. Available from: [/pmc/articles/PMC4065967/](#).
- [2] K. Ohba, F. Sugauchi, E. Orito, K. Suzuki, T. Ohno, N. Mizoguchi, Cystic lymphangioma of the gall-bladder: a case report, Available from: *J. Gastroenterol. Hepatol.* 10 (6) (1995) 693–696 <https://pubmed.ncbi.nlm.nih.gov/8580416/>.
- [3] M.D. Bishop, M. Steer, Pancreatic cystic lymphangioma in an adult, Available from: *Pancreas* 22 (1) (2001) 101–102 <https://pubmed.ncbi.nlm.nih.gov/11138961/>.
- [4] M.T. Boskovski, A. Saad, G.M. Israel, R.R. Salem, Lymphangioma of the gallbladder in adults: review of the literature and a case report, *J. Gastrointest. Surg.* 16 (3) (2012 Mar 19) 663–668. <https://eurekamag.com/research/054/200/054200476.php>.
- [5] A. Bridda, L. Dallagnese, M. Frego, Is laparoscopic cholecystectomy safe for lymphangioma of the gallbladder? A complicated case mimicking subhepatic abscess, *Updat. Surg.* 64 (1) (2012 Mar 1) 73–76.
- [6] R.A. Agha, T. Franchi, C. Sohrabi, G. Mathew, for the SCARE Group, The SCARE 2020 guideline: updating consensus Surgical Case REport (SCARE) guidelines, *Int. J. Surg.* 84 (2020) 226–230.
- [7] H. Takiff, R. Calabria, L. Yin, B.E. Stabile, Mesenteric cysts and intra-abdominal cystic lymphangiomas, Available from: *Arch. Surg.* 120 (11) (1985) 1266–1269 <https://pubmed.ncbi.nlm.nih.gov/4051731/>.
- [8] K.W. Noh, E.P. Bouras, M.D. Bridges, R.E. Nakhleh, J.H. Nguyen, Gallbladder lymphangioma: a case report and review of the literature, Available from: *J. Hepato-Biliary-Pancreat. Surg.* 12 (5) (2005 Oct 1) 405–408 <https://onlinelibrary.wiley.com/doi/full/10.1007/s00534-005-0997-9>.
- [9] J.Y. Choi, M.J. Kim, J.J. Chung, S.I. Park, J.T. Lee, H.S. Yoo, Gallbladder lymphangioma: MR findings, Available from: *Abdom. Imaging* 27 (1) (2002 Jan) 54–57 <https://pubmed.ncbi.nlm.nih.gov/11740609/>.
- [10] J.H. Chung, Y.L. Suh, I.A. Park, J.J. Jang, J.G. Chi, Kim Y. Il, A pathologic study of abdominal lymphangiomas, Available from: *J. Korean Med. Sci.* 14 (3) (1999) 257–262 <https://pubmed.ncbi.nlm.nih.gov/10402167/>.