

Original Article

A Case Report of Turner Syndrome with Graves' Disease during Recombinant Human GH Therapy and Review of Literature

Makio Nakagawa, Yasuji Inamo and Kensuke Harada

Department of General Pediatrics, Nerima-Hikarigaoka Nihon University Hospital, Nihon University School of Medicine, Tokyo, Japan

Abstract. An increased incidence of Hashimoto thyroiditis has been reported in patients with Turner syndrome, but several cases of Graves' disease were also described ten to 20 years ago. We report the case of a patient with Turner syndrome who developed Graves' disease, 3 years after successful treatment with recombinant human growth hormone (GH). A diagnosis of Graves' disease was made and treatment with thiamazole was started, which resulted in normalization of the thyroid function. It is important to monitor thyroid function as well as growth parameters in patients with Turner syndrome.

Key words: Turner syndrome, Graves' disease, hyperthyroidism, recombinant human growth hormone therapy

Introduction

An increased incidence of Hashimoto thyroiditis has been reported in patients with Turner syndrome. In view of its pathogenic relationship with autoimmune thyroiditis, Graves' disease would be expected to be frequent in Turner syndrome.

Here we report the case of a 9-yr-old girl with Turner syndrome who developed Graves' disease during recombinant human GH therapy, and we discuss previous reports of this association.

Case Report

The patient was the first child of healthy unrelated parents of normal stature, father 175.0 cm and mother 159.0 cm. The family history was unremarkable. The patient was born after an uncomplicated pregnancy at a gestational age of 37 wks and 1 d. Her birth weight was 2490 g. On examination, lymphedema and webbed neck were detected. Chromosomal analysis of peripheral blood lymphocytes (N=26) showed complete deletion of the short arm of the second X chromosome (karyotype: 45, X). At the age of 5 yr and 2 mo, the girl was referred to us because of short stature. Her height was 98.2 cm (-2.25 SD) and her weight was 14.4 kg (-1.48 SD). Her bone age was 3 yr (Japanese TW2). A GH stimulation test was performed, and the peak GH values after stimulation with clonidine and arginine were 8.39 ng/ml and 5.56 ng/ml,

Received: September 1, 2005

Accepted: January 12, 2006

Correspondence: Dr. Yasuji Inamo, Department of General Pediatrics, Nerima-Hikarigaoka Nihon University Hospital, Nihon University School of Medicine, 2-11-1, Hikarigaoka, Nerima-ku, Tokyo 179-0072, Japan

E-mail: y-inamo@pb3.so-net.ne.jp

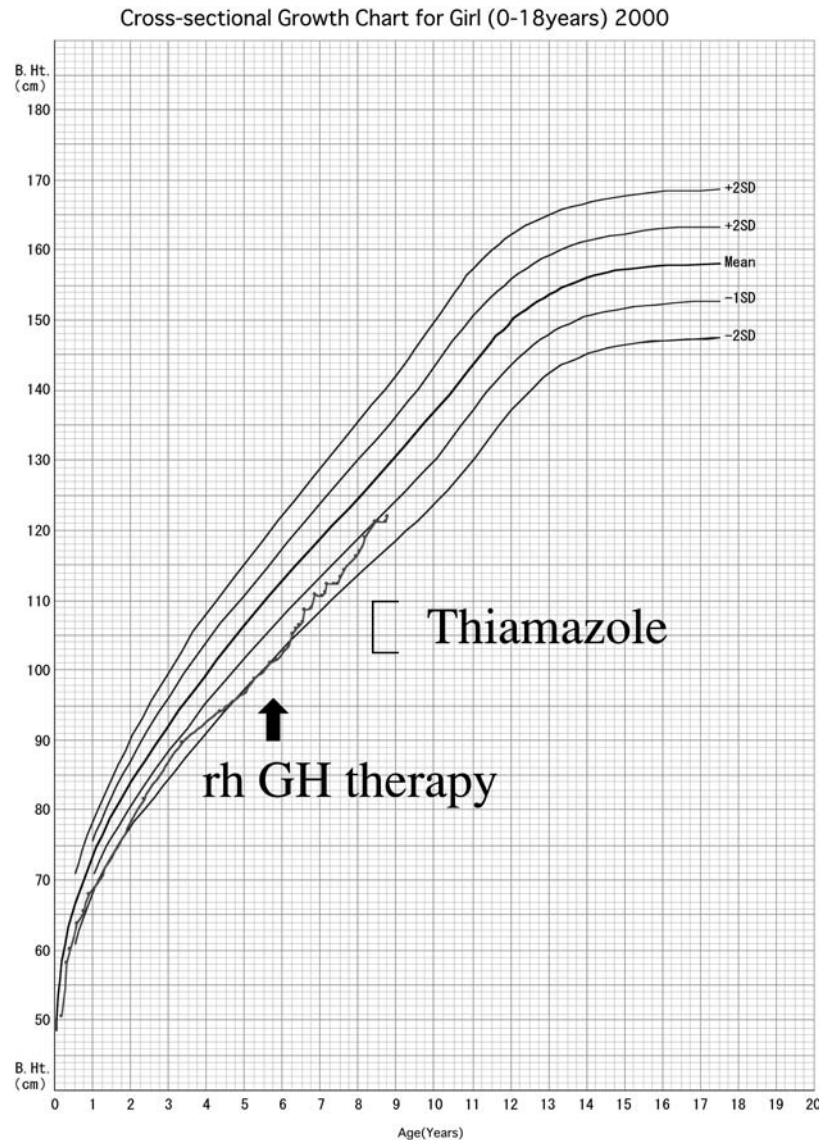


Fig. 1 Growth curve of the patient

respectively. Of note is that diagnosis of complete GH deficiency is less than 5 ng/ml in this assay. Recombinant human (rh) GH therapy (0.175 mg/kg/wk) was initiated with success (Fig. 1). At follow-up three years later, she presented with increased appetite and exophthalmos. Neither palpitation nor heat intolerance were noticed. The thyroid gland was Grade 3, diffuse and soft. Thyroid function tests showed a TSH level of 0.01 μ U/ml (normal, 0.50 to 5.50 μ U/

ml), a free (f) T_4 value of 6.00 ng/dl (normal, 0.85 to 1.80 ng/dl), and a free T_3 value of 21.76 pg/ml (normal, 2.50 to 5.50 pg/ml). Anti-thyroglobulin antibody was 3.4 U/ml (normal, <0.3 U/ml). Anti-thyroid peroxidase antibody was 5.5 U/ml (normal, <0.3 U/ml). TSH receptor antibody (TRAb) was 52% (normal, <15%). These results are compatible with a diagnosis of Graves' disease and treatment with thiamazole was started.

Table 1 Graves' disease in Turner syndrome

Patient No.	Age at diagnosis of Graves' disease	Karyotype	Goiter	Exophthalmos	Thyroid test (x)	Microsome test (x)	TSAb (%)	¹²⁵ I uptake (%)	Treatment	Age at initiation of rhGH therapy	Refer -ence
1	13	45,XO/46,XXqi	+	+	5000	ND	ND	61 (¹³¹ I) 4 hour	Anti-thyroid drug therapy, partial thyroidectomy	no data	1
2	20	45,XO	+	+	25	ND	ND	66 (¹³¹ I)	PTU propranolol	no data	2
3	20	45,XO/46,XX	+	+	640	ND	ND	67 (¹³¹ I)	ND	no data	3
4	23	45,XO	+	+	1024	ND	LATS raised	71 (¹³¹ I)	ND	no data	3
5	9	45,XO/46,XX	ND	ND	ND	ND	ND	ND	PTU	no data	3
6	34	45,XO/46,X,i(Xq)	+	-	100	102400	ND	33 (¹³¹ I)	ND	no data	4
7	13	45,XO	+	+	400	undetectable	positive	66	Anti-thyroid drug therapy	no data	5
8	9	46,Xdel(Xp)	+	+	ND	50	169 (TSAb)	ND	MMI	no data	6
9	22	46,X,i(Xq)	ND	-	negative	25600	85 (TBII)	ND	MMI	no data	7
10	14	45,X/46,Xr(X)	-	-	1600	1600	236 (TSAb)	48.71	None, continued rhGH	9	8
11	13	ND	+	+	ND	ND	59 (TBII)	ND	MMI, continued rhGH	12	9
12	15	45,XO	-	-	positive	positive	11.9 (TBII)	52.5	Transient MMI, restarted rhGH	11	10
13	8	45,XO	+	+	3.4 (TgAb)	5.5 (TPOAb)	52.0 (TBII)	ND	MMI, continued rhGH	5	Our case

TSAb, thyroid-stimulating antibody; PTU, propylthiouracil; MMI, thiamazole; TBII, thyrotropin-binding inhibitory immunoglobulin; TgAb, anti-thyroglobulin antibody; TPOAb, anti-thyroid peroxidase antibody; ND, not described.

At the latest follow up (9 y old), the development of the patient's breast was Tanner stage 1. Treatment with thiamazole was continued and the thyroid function has stayed within normal ranges.

Discussion

The association of Turner syndrome with Graves' disease was reported in English about 10–20 years ago (1–10). Table 1 summarizes the historical thirteen known cases of Graves' disease with Turner syndrome, including our case. This table reveals that the clinical characteristics of Graves' disease with Turner syndrome are similar to those known generally in patients without Turner syndrome in terms of ages of the onset, symptoms and prognosis.

A direct link between GH treatment and Graves' disease is unlikely. Treatment with rhGH was given to 4 patients in Table 1, and it was continued in 3 out of the 4 patients including our case. This continuation of GH treatment, together with the successful treatment of hyperthyroidism, suggests that a direct link between GH treatment and Graves' disease is unlikely. Consistent with this hypothesis, the incidence of hyperthyroidism in Japanese patients with Turner syndrome receiving rhGH therapy is 0.40%, which is similar to overall incidence of hyperthyroidism in patients with Turner syndrome, 0–0.5% (11, 12).

It is well known that hyperthyroidism in patients with Turner syndrome leads to acceleration of height velocity (6, 13). In our patient, the height velocity was not increased by hyperthyroidism, probably because her growth had been already accelerated by rhGH therapy before the onset of hyperthyroidism.

Conclusion

It is important to monitor changes of thyroid function as well as growth parameters in patients

with Turner syndrome, as is recommended by Sybert and McCauley (14).

References

1. McHardy-Young S, Doniach D, Polani PE. Thyroid function in Turner's syndrome and allied conditions. *Lancet* 1970;2:1161–3.
2. Chang JC, Burkle JS. Unusual X chromosome in hyperthyroidism and Turner's syndrome. *NY State J Med* 1973;73:1101–4.
3. Brooks WH, Meek JC, Schimke RN. Gonadal dysgenesis with Turner's syndrome. *J Med Genet* 1977;14:128–9.
4. Kawai K, Kondo K, Terasaki T, Ogata E. A case of Turner's syndrome with hyperthyroidism. *Endocrinol Japon* 1978;25:631–4.
5. Marcocci C, Bartalena L, Martino E, Fenzi GF, Pinchera A. Graves disease and Turners syndrome. *J Endocrinol Invest* 1980;4:429–31.
6. Massa G, Zegher F, Dooms L, Vanderschueren-Lodeweyckx M. Hyperthyroidism accelerates growth in turners syndrome. *Acta Paediatr* 1992;81:362–4.
7. Chiovato L, Larizza D, Bendinelli G, Tonacchera M, Marino M, Mammoli C, *et al.* Autoimmune hypothyroidism and hyperthyroidism in patients with Turner's syndrome. *Eur J Endocrinol* 1996;134:568–75.
8. Sakurai T, Kodama S, Sakamoto S, Yasujima H, Shimizu H, Yoshimura R, *et al.* Hyperthyroidism without clinical symptoms found in Turner syndrome during human growth hormone therapy. *Clin Pediatr Endocrinol* 1993;2 (Suppl 2):107–10.
9. Higashino H, Kitamura M, Cho S, Kobayashi Y. A girl with Turner syndrome with hyperthyroidism during growth hormone therapy. *Clin Pediatr Endocrinol* 1996;5 (Suppl 8):157–8.
10. Murashita M, Satoh K, Abe S, Nakae J, Tajima T, Shinohara N, *et al.* Clinical course of hyperthyroidism in three growth hormone deficient children treated with human growth hormone. *Clin Pediatr Endocrinol* 1998;7 (Suppl 11):85–8.
11. Okada Y. Hyperthyroidism during growth hormone therapy in Japan. *Pharma Medica*

- 1999;17:149–55 (in Japanese).
12. Niimi H. Thyroid disease and autoimmune disease. In: Okada Y, editor. Turner syndrome. Osaka: Medical View Press; 2001. p. 185–92 (in Japanese).
 13. Davies TF, Larson PR. Thyrotoxicosis. In: Larson PR, Kronenberg HM, Melmed S, Polonsky KS, editors. Williams textbook of endocrinology. Tokyo, Saunders; 2002. p. 374–422.
 14. Sybert VP, McCauley E. Turner syndrome. N Engl J Med 2004;351:1227–38.