

# New Algorithm for Chest-wall Surgery and Quality of Life Assessment in Female-to-male Reassignment Patients

Vittorio Ramella, MD\*  
 Giovanni Papa, MD, PhD\*  
 Chiara Stocco, MD\*  
 Lucio Torelli, MD†  
 Benedetta Vasselli, MD\*  
 Zoran M. Arnez, MD, PhD\*

**Background:** Chest-wall contouring surgery (chest-wall reconstructive surgery) is often the first surgical procedure in female-to-male (FtM) gender reassignment surgery (GRS). The main goal of this procedure is to create an aesthetically pleasing male-like chest contour. No universally accepted algorithm exists for detection of the appropriate surgical technique. Also, there is no tool for objective evaluation of the quality of life and satisfaction of these patients after the operation.

**Methods:** This study involves a single-center clinical trial assessing the patients who underwent subcutaneous mastectomy in FtM GRS between 2003 and 2019. The selection of patients was based on the new “simplified” algorithm consisting of 2 different surgical techniques: the semicircular and the double-incision with free nipple grafting. The selection was based on 3 criteria: breasts size, breast ptosis, and skin elasticity. The outcomes and complication rates were collected and analyzed. The patients’ satisfaction and Quality of Life was assessed with a 5-point Likert scale questionnaire, specifically conceived for FtM patients. The aesthetic evaluation was performed using a 5-point Likert scale dealing with the 5 items featuring as the main goals of GRS.

**Results:** 184 mastectomies were performed in 92 FtM GRS patients. The overall reoperation rate was 11.9%. The patient survey revealed both a high satisfaction rate and a good aesthetic result (4.4/5).

**Conclusions:** The proposed algorithm facilitates the selection of the most suitable technique for top surgery. The patient satisfaction rate evaluated by the proposed Health-Related Quality of Life questionnaire confirmed the outcomes of the use of the algorithm. Further studies to validate the proposed evaluating tools are needed. (*Plast Reconstr Surg Glob Open* 2020;8:e3121; doi: [10.1097/GOX.0000000000003121](https://doi.org/10.1097/GOX.0000000000003121); Published online 24 September 2020.)

## INTRODUCTION

For most people, the gender assigned at birth corresponds with the experienced gender identity, defined as self-identification as male or female.<sup>1</sup> Some individuals, however, may feel different degrees of inconsistency between these two components and experience what is called gender dysphoria. Most of the social difficulties

faced by FtM patients are related to the persistence of the female-like profile, which they try to conceal by using breast binders. This practice, however, often leads to skin rashes or acne and restricts physical activity, besides being uncomfortable.<sup>2,3</sup> Hence, the procedure of chest-wall contouring surgery—designed to create an aesthetically pleasing male-like chest contour—is aimed precisely at alleviating the high degree of discomfort associated with this aspect.<sup>4</sup> In small and non-ptotic breasts, this can be achieved by subcutaneous removal of the glandular and adipose tissues (semi-circular technique). In large and ptotic breasts, however, the double-incision with free nipple grafting (DIFNG) is unavoidable if the surgeon wants to remove the skin excess and to reduce and relocate the nipple-areola complex. Numerous studies have proposed different surgical algorithms, but none has been universally accepted.<sup>5-7</sup> In addition, up to now, no specific questionnaire assessing the impact on the Quality of Life (QoL) and the satisfaction of the outcome has yet been

*From the \*Department of Medical, Surgical and Health Sciences, Plastic and Reconstructive Surgery Unit, University of Trieste, Trieste, Italy; and †Department of Medicine, Surgery and Health Sciences, University of Trieste, Trieste, Italy.*

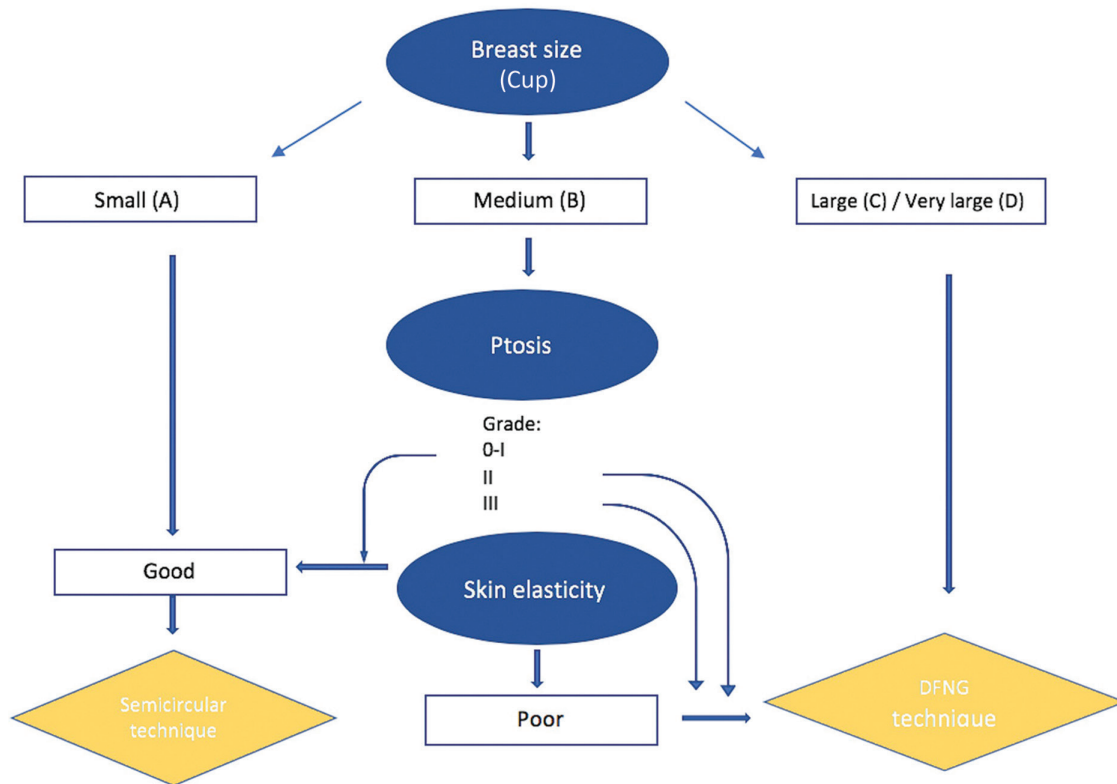
*Drs Ramella and Papa contributed equally to this work.*

*Received for publication January 16, 2020; accepted July 27, 2020.*

*Copyright © 2020 The Authors. Published by Wolters Kluwer Health, Inc. on behalf of The American Society of Plastic Surgeons. This is an open-access article distributed under the terms of the [Creative Commons Attribution-Non Commercial-No Derivatives License 4.0 \(CCBY-NC-ND\)](https://creativecommons.org/licenses/by-nc-nd/4.0/), where it is permissible to download and share the work provided it is properly cited. The work cannot be changed in any way or used commercially without permission from the journal.*

*DOI: [10.1097/GOX.0000000000003121](https://doi.org/10.1097/GOX.0000000000003121)*

**Disclosure:** *The authors have no financial interest to declare in relation to the content of this article.*



**Fig. 1.** The new “simplified” algorithm for subcutaneous mastectomy.

validated. These data are crucial to improve the standards of care and clinical outcomes.

In this article we present a new “simplified” algorithm to facilitate the choice of the proper surgical technique, a new Health-Related QoL Survey Tool, specifically conceived for FtM patients and the sub-sequential aesthetic outcome assessment.

### MATERIALS AND METHODS

All data of patients who underwent chest-wall contouring surgery at the Plastic and Reconstructive Surgery Unit of the Cattinara University Hospital of Trieste, between April 2003 and May 2019 were collected.

Two surgical techniques were performed according to the algorithm adopted by the authors: the semicircular (hemi-areola) approach and the DIFNG technique (Fig. 1). Since the round block technique, which is used for patients with small/medium cup presenting asymmetry, was used only once in our series, it was replaced by the two other techniques to simplify the algorithm. A total of 184 subcutaneous mastectomies, in 92 patients, were performed. The patients included in the study were diagnosed with persistent gender dysphoria, had signed an informed consent, and held a court ruling that enabled them to proceed with Gender Reassignment Surgery (GRS). The acute and delayed complications rate<sup>8,9</sup> was recorded and compared with the recent literature (Table 1). In addition, the patient’s postoperative quality of life and satisfaction by

using a new questionnaire specifically conceived for FtM patients was assessed (Table 2). The questionnaire, written in Italian, was developed on the basis of the *Breast-Q*, a validated survey tool for women with breast cancer, and was then submitted postoperatively to the patients operated on from 2016 to 2018.

Among these, 19 patients were effectively contacted and only 12 returned the questionnaire. The difficulties in contacting the patients were due to changes of phone numbers, personal data (including name), and not willing to be surveyed, even if anonymous. Eventually, the aesthetic surgical outcome was evaluated by using a complete series of photographs (preoperative, intraoperative and postoperative) of 36 patients who underwent surgery and they were not recognizable on basis of distinctive features (tattoos, piercings). Two plastic surgeons, different from those who had performed the surgery, were asked to score

**Table 1. Acute Reoperations and Secondary Operations Rate: The Current Literature versus the Hospital of Trieste**

Study	No. Breasts	Acute Reoperations (Percentage)	Secondary Operations (Percentage)
Wölter et al <sup>7</sup>	346	32 (9.2%)	31 (9%)
Monstrey et al <sup>6</sup>	184	8 (4.3%)	59 (32%)
Cregten-Escobar <sup>22</sup>	404	20 (5.0%)	122 (30.1%)
Hospital of Trieste (2019)	184	10 (5.4%)	12 (6.5%)

**Table 2. The HR-QOL and Postoperative Satisfaction Survey Tool**

QoL Domains	Totally Dissatisfied	Dissatisfied	Quite Satisfied	Satisfied	Very Satisfied
Psychosocial well-being					
Do you feel more comfortable now than you used to feel in situations which require to be open-chest (such as the beach, the pool, etc.)?	1	2	3	4	5
Sexual well-being					
Do you feel more comfortable as regard to your new sexual identity?	1	2	3	4	5
Physical well-being					
How much more comfortable are you now that you no longer have to hide?	1	2	3	4	5
Satisfaction Domains	Totally Dissatisfied	Dissatisfied	Quite Satisfied	Satisfied	Very Satisfied
Satisfaction with the result					
Are you satisfied about how your chest looks after the surgery?	1	2	3	4	5
Satisfaction with the surgical planning					
Is the result consistent with what was originally designed?	1	2	3	4	5
Overall satisfaction					
Are you satisfied with the overall result?	1	2	3	4	5

The questionnaire submitted to the patients; it consists of 6 domains concerning the postoperative quality of life and satisfaction of the patients. Answers are based on a 5-point Likert scale.

**Table 3. Aesthetic Evaluation Carried Out on the Main Goals of CRS**

Main Goals of Chest-wall Contouring Surgery	Very Poor	Poor	Good Enough	Good	Very Good
Removal of the breast tissue and skin excess	1	2	3	4	5
Proper reduction and positioning of the nipple and the areola	1	2	3	4	5
Obliteration of the inframammary fold	1	2	3	4	5
(Ideally) The minimization of chest-wall scars	1	2	3	4	5
Creating an aesthetically pleasing male-chest contour	1	2	3	4	5

For each item a 5-point Likert scale answer ranging from 1 “very poor” to 5 “very good” was provided.

the 5 items acknowledged to be the main goals of Chest-wall Reconstructive Surgery (CRS)<sup>3,10</sup> by using a 5-point Likert scale (Table 3). Plastic surgeons’ evaluation was required, in our opinion, because, in addition to evaluation of the aesthetic result, the main issue was the selection of the appropriate surgical technique in relation to the patient characteristics. The agreement in response was calculated to appreciate significant differences between the judgments and the results were then analyzed based on the average score.

**The New “Simplified” Algorithm**

The present study suggests a new “simplified” algorithm as a practical tool to assist surgeons in selection of the appropriate surgical technique. The algorithm selects the surgical technique to be used based on three criteria: the breasts size (cup), the breasts ptosis, and the degree of elasticity of the skin (Fig. 1).

It proposes only 2 surgical techniques, the semicircular and the DIFNG. The reduction of the number of the surgical options might ensure a higher level of expertise of the surgical team as reflected in the final surgical outcome. Also, it derives from the need to find unifying and reproducible criteria to make this algorithm a viable tool for other surgeons, especially in those centers where clinical experience is limited.

As seen from the algorithm (Fig. 1), the primary assessment is to evaluate the size of the breast cup, followed by

the degree of breast ptosis and finally, the key determinant for selection of a more or less invasive technique, by the skin elasticity. The trickiest condition is a medium breast cup; in this case, if the skin quality is good enough the choice falls on the semi-circular technique, or if the skin quality is poor, the choice should be a more extensive surgical procedure. The only case that falls outside the preoperative criteria for selection of the appropriate surgical technique is a marked breast asymmetry; in this case, none of the surgical procedures proposed by this algorithm would be suitable because they would result in excessive scars on the one side and in an incomplete mammary tissue removal on the other.<sup>11</sup> Therefore, the authors suggest that, in such cases, the semicircular technique should be performed on the smaller breast, whereas the round block technique is applied on the bigger breast.<sup>12</sup>

**The Questionnaire**

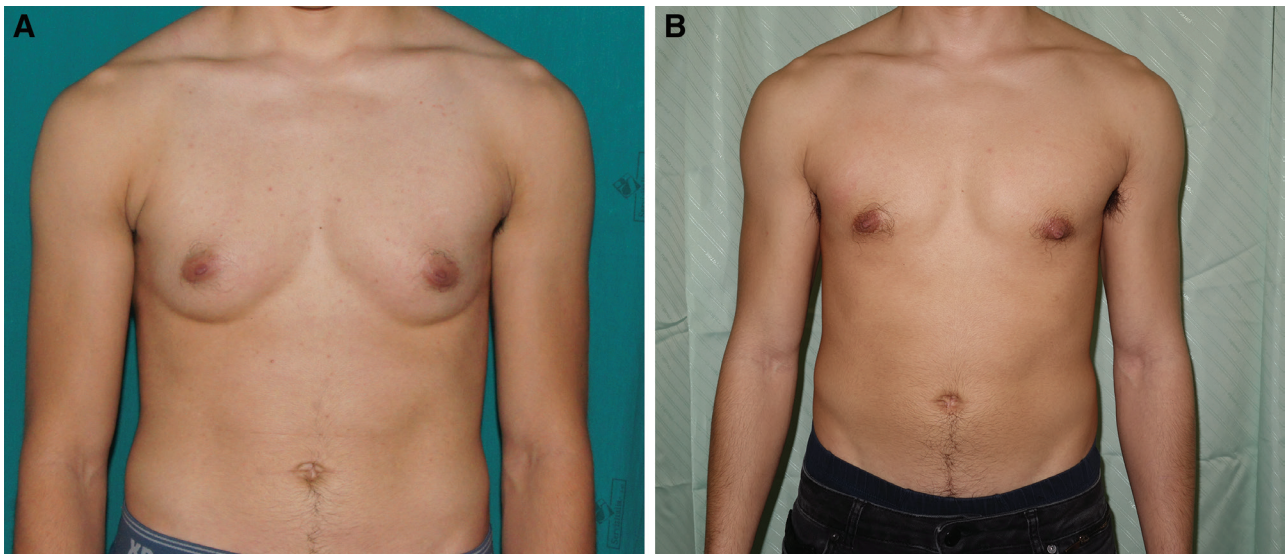
The questionnaire was structured on the basis of Breast-Q<sup>13,14</sup> on 6 domains related to quality of life and postoperative patient satisfaction. The domains could be grouped into two macro-areas, the first of which related to the quality of life and the second to the patient satisfaction in postoperative care. Domains related to the quality of life considered psychosocial, sexual, and physical well-being. On the other hand, as far as satisfaction measurement was concerned, the domains of

reference were the satisfaction with the result, with the preoperative planning, and patients' overall satisfaction (Table 2). For each domain, one question was postulated as to relate the domain of reference within the context of patients' daily life, that is, for the general health the question asked was "How much more comfortable are you now that you no longer have to hide your breast?" (Table 2). Patients could answer with a statement on a 5-point Likert scale, in which 1 corresponded to "totally dissatisfied" and 5 to "very satisfied." The QoL survey was administered in Italian because the mother tongue of all patients is Italian.

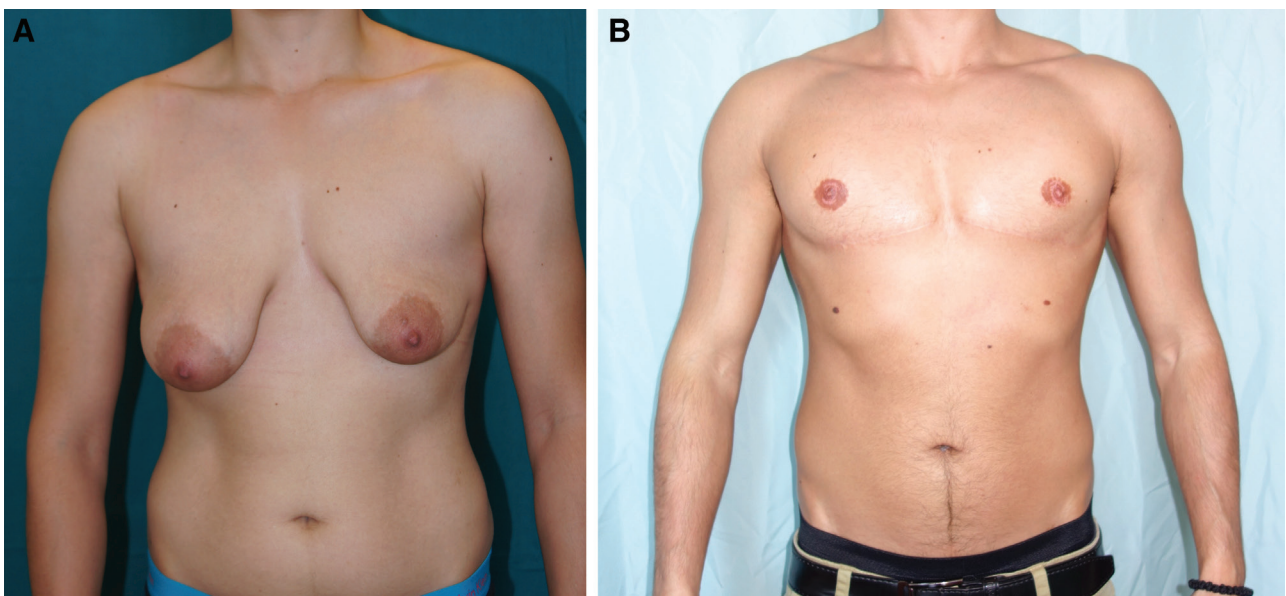
**The Aesthetic Evaluation**

The aesthetic evaluation was performed using post-operative photographs on a representative sample of 36 patients who had undergone Top Surgery in the period from 2003 and 2019 taken 1 month and 1 year after surgery. This rather small sample of patients resulted from selecting the photographs: not all the patients who were operated on had a complete photographic history, or pictures were not taken in a standardized fashion, or they had markings that made them recognizable.

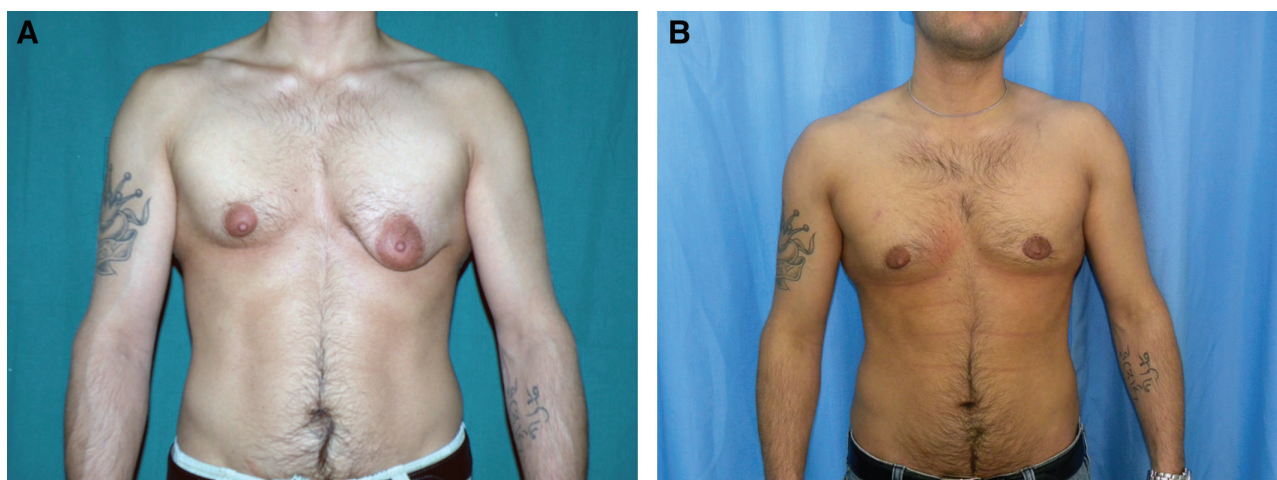
Two plastic surgeons, different from those who had performed the surgery, were asked to score the 5 items



**Fig. 2.** A 27-year-old patient who underwent the semicircular technique for subcutaneous mastectomy. Preoperative (A) and 1 year after surgery frontal views (B).



**Fig. 3.** A 26-year-old patient presenting with breast ptosis and asymmetry. A DIFNG surgery was performed to excise the excess skin, correct the asymmetry, and place the nipple-areola complex where more indicated. Preoperative (A) and 1 year after surgery frontal views (B).



**Fig. 4.** A 28-year-old patient presenting with breast asymmetry who received a round block technique on the left breast to correct the nipple-areola complex asymmetry and a semi-circular technique on the right side. Preoperative (A) and 1 year after surgery frontal views (B).

**Table 4. Outcome Parameters**

Complications	Semicircular	DIFNG	Round Block	Total
Minor				
Partial NAC necrosis	1	0	0	1
Seroma	0	0	0	
Major				
Full NAC necrosis			0	
Hematoma with revision	1	4	0	5
Secondary revisions				
Contour revisions	1	1	0	2
NAC revisions	0	0	0	
Scar revisions	1	2	0	3
Total of the revisions				11

NAC, nipple-areola complex.

acknowledged to be the main goals of CRS by using a 5-point Likert scale concerning (Table 3). The evaluation was not only related to the aesthetic result itself but to the appropriacy of the choice of the surgical technique in relation to the patients’ characteristics, which made mandatory a plastic surgeon evaluation, reason why skilled figures were asked to score the pictures.

The 5 items considered were: (1) the removal of breast tissue; (2) the proper nipple positioning and reduction; (3) the obliteration of the inframammary fold; (4) the minimizing the chest wall scars; and (5) the appropriate chest contouring. The agreement in response was calculated to appreciate significant differences between the judgments given by the two surgeons; the results were then analyzed based on the average score.

## RESULTS

Ninety-two patients underwent masculinizing chest-wall contouring surgery, for a total of 184 subcutaneous mastectomies between April 2003 and May 2019. Twenty-three patients underwent the semicircular approach (46 mastectomies in total) (Fig. 2) and 86 had the double-incision mastectomy with free nipple grafting technique (136 mastectomies) (Fig. 3). The combination of the round block technique and the semicircular approach was performed on one patient because of a marked breast

asymmetry (Fig. 4). Complications (such as hematoma/wound dehiscence,<sup>15</sup> etc.) were encountered in 11 patients (11.9%) (Table 4).

Therefore, we submitted the questionnaire assessing the quality of life and satisfaction with the outcomes to the patients operated on between 2016 and 2018. More than 80% of the patients experienced positive outcomes in reference to the quality of life macro-area, indicating a significant improvement in this area. As for the satisfaction domains, more than 50% of the surveyed declared to be “very satisfied” or “satisfied.” This result can be considered significant because the aesthetic results are strongly influenced by the patients’ preoperative expectations. Only 19 patients returned the questionnaire due to the difficulties in contacting these patients because of phone number change, changing of personal data (including name) and the unwillingness to be surveyed, even if in an anonymous way.

The final part of the study focused on the evaluation of the surgical outcomes. The agreement in response—intended as max 1-point of tolerance—resulted in more than 75% for all the answers analyzed. Any considerable variation—intended as above 1 point of tolerance—was found in the remaining 25% of the scores. This proportion allows analyzing data, considering the average of the scores provided by the two surveyors. The analysis of the data showed that the item concerning the removal of breast tissue and excess skin was evaluated with an average of 4,7, considering 5 as the maximum score. The correct positioning of the nipple–areola complex was found to have an average of 4.05, the obliteration of the inframammary fold was evaluated with a score of 4,5, and finally the item concerning the minimization of scars was evaluated with an average of 4,09, still out of a maximum score of 5. As far as the chest masculinization aspect was concerned, which is a crucial point of the evaluation, it was evaluated with an average score of 4,4. With regard of this latter question, considering the degree of discordance, it emerged that 84% of the patients were evaluated with judgments equal to “very good” and “good.”

## DISCUSSION

In recent years, there has been a significant increase in the demand for GRS and, in particular, for chest-wall masculinization surgery. This increase is likely to be due to a greater attention towards gender dysphoria, particularly in medical, paramedical, and legal environments. Subcutaneous mastectomy is the first, and often the only, surgical procedure in GRS.<sup>16</sup> The aim of this procedure is the masculinization of the chest. By giving the chest a masculine appearance, an attempt is made to alleviate the discomfort these patients feel when exhibiting such as evident female characteristic, namely the breast.<sup>17,18</sup> Although different surgical techniques for chest masculinization have been proposed in the literature, only a few articles have suggested algorithms for choosing the most correct surgical approach to use.

The Department of Plastic and Reconstructive Surgery of Trieste has conceived and adopted a precise preoperative decision-making algorithm, which could be defined as “simplified.” Based on the criteria chosen for the preoperative evaluation, that is, the size of the breasts, the ptosis, and the elasticity of the skin, the algorithm allows for a straightforward selection of the surgical technique toward a more or a less invasive procedure. In general, the most frequently used technique was the DIFNG because it is indicated in medium to large breasts, with grade II or III ptosis and with moderate/poor skin elasticity (characteristics most commonly encountered in patients). This approach leads to a more extensive scarring of the chest wall and can be burdened by NAC partial/total necrosis (which can be managed with conservative treatments<sup>19–21</sup>).

Only when the patient presents small, non ptotic breasts and with good skin elasticity, the choice falls on the semicircular technique, which is therefore an approach reserved for a few selected cases only. A comparison with the existing literature has shown how this decision-making algorithm allows results that are in line with, if not better than, many other specialized centers in this field. Among the articles analyzed in the narrative review, we have chosen those that used the same surgical techniques as we had (Fig. 1). The need for a delayed revision surgery was compared with a recent review published in 2018.<sup>8</sup> We deliberately considered only the rate of additional procedure needed for aesthetic improvements because, in our opinion, it provides a better measure of the best surgical technique to perform as well as of the expertise of surgeons.

Table 1 shows that the secondary operation rate of the hospital of Trieste was 6,5% (11/184), which is significantly lower than in the studies published both from Monstrey et al<sup>6</sup> and Cregten Escobar et al,<sup>22</sup> respectively 32% and 30.1% ( $P = 0.001$ ). In comparison with the complications recorded by Wolter et al,<sup>7</sup> our complication rate is lower, but not significantly: 9% ( $P = 0.1108$ ).

The algorithm was designed as simple as possible, to give a readily accessible tool for surgeons who practice this type of surgery. Chest wall contouring is widely performed but often the overall surgeries that each center performs are not enough to gain adequate experience with all the available techniques. The importance of masculinizing chest surgery lies in the fact that, in addition to modifying

the aesthetic aspect of the patients who consequently perceived themselves physically more at ease with the chosen gender, it also allows them to fully live the new gender role in family, social, and sexual context.

Therefore, to provide a full and comprehensive care of the patient, it was decided to assess also patients' quality of life and postoperative satisfaction by means of a questionnaire, specifically conceived for FtM patients. The questionnaires showed that, as expected, the overall patient satisfaction was higher in the semicircular subcutaneous mastectomy group. This—although the rate of secondary revisions in this group is higher compared to the double-incision mastectomy group (13.0% vs. 4.4%)—is attributable to the fact that the scars in this group are shorter, which is often the main concern for the patient. However, a very high level of satisfaction was also found in the group of double-incision mastectomy, demonstrating that although the scars and invasiveness of the operation are greater, the result can be equally satisfactory.

The evaluation showed that all the items considered were evaluated as “good” (4/5) or “very good” (5/5). With regard to the masculinization of the chest (*item 5*), considering the agreement in response, 84% of the patients were scored either “good” or “very good,” which indicate an overall satisfactory result.

The limitations of the study are represented by a relatively small cohort of patients, the single center experience, and the QoL evaluation using a unvalidated questionnaire. In addition, not all patients filled the questionnaire form and some of them were lost at the follow-up.

The suggested algorithm can be considered as simplified because it considered only 2 types of surgical technique; however they can be found adequate when dealing with FtM chest masculinization.

## CONCLUSIONS

The present study shows the advantages of adopting a new “simplified” decisional algorithm to facilitate the selection of the most suitable technique for chest wall reconstructive surgery. It also provides the basis for the validation of an evaluative tool, labeled as “The Health-Related QoL and patient satisfaction survey tool after chest-wall reconstructive surgery,” aimed at appraising objectively the outcomes of the surgery from the patient's point of view.

Zoran M. Arnez, MD

Department of Medical, Surgical and Health Sciences  
Plastic and Reconstructive Surgery Unit

University of Trieste  
ASUITS Trieste

Strada di Fiume 447, Trieste 34137, Italy

E-mail: [zoran.arnez@asuits.sanita.fvg.it](mailto:zoran.arnez@asuits.sanita.fvg.it)

## ACKNOWLEDGMENTS

All patients filled an informed valid consent prior to the surgery. This study was performed in accordance with the ethical standards of the 1964 Declaration of Helsinki as revised in 2000. The study was registered within the internal database of audits held in the Plastic Reconstructive and Aesthetic Surgery of Cattinara Hospital (Trieste) and the Hospital institution

accepted the publication of the data obtained and previously presented in the clinical audit section. The work presented is an observational longitudinal study, and it follows the STROBE checklist for cohort studies.

### REFERENCES

1. American Psychiatric Association. *DSM-V Manuale Diagnostico e Statistico Dei Disturbi Mentali*. Raffaello Cortina Editore. IBS; 2013.
2. Hage JJ, Bloem JJ. Chest wall contouring for female-to-male transsexuals: Amsterdam experience. *Ann Plast Surg*. 1995;34:59–66.
3. Hage JJ, van Kesteren PJ. Chest-wall contouring in female-to-male transsexuals: basic considerations and review of the literature. *Plast Reconstr Surg*. 1995;96:386–391.
4. Trombetta C, Liguori G, Pascone M, et al. Total sex-reassignment surgery in female-to-male transsexuals: a one-stage technique. *BJU Int*. 2002;90:754–757.
5. Berry MG, Curtis R, Davies D. Female-to-male transgender chest reconstruction: a large consecutive, single-surgeon experience. *J Plast Reconstr Aesthet Surg*. 2012;65:711–719.
6. Monstrey S, Selvaggi G, Ceulemans P, et al. Chest-wall contouring surgery in female-to-male transsexuals: a new algorithm. *Plast Reconstr Surg*. 2008;121:849–859.
7. Wolter A, Diedrichson J, Scholz T, et al. Sexual reassignment surgery in female-to-male transsexuals: an algorithm for subcutaneous mastectomy. *J Plast Reconstr Aesthet Surg*. 2015;68:184–191.
8. Wilson SC, Morrison SD, Anzai L, et al. Masculinizing top surgery: a systematic review of techniques and outcomes. *Ann Plast Surg*. 2018;80:679–683.
9. Arnež ZM, Ramella V, Papa G, et al. Is the LICOX PtO2 system reliable for monitoring of free flaps? Comparison between two cohorts of patients. *Microsurgery*. 2019;39:423–427.
10. Takayanagi S, Nakagawa C. Chest wall contouring for female-to-male transsexuals. *Aesthetic Plast Surg*. 2006;30:206–212; discussion 213.
11. Ramella V, Papa G, AZ. Surgical therapy: chest wall contouring for female-to-male transsexuals. In Trombetta C, Liguori G, Bertolotto, M (Eds.). *Management of Gender Dysphoria*. Springer, MI; 2015:281–287.
12. Maas M, Howell AC, Gould DJ, et al. The ideal male nipple-areola complex: a critical review of the literature and discussion of surgical techniques for female-to-male gender-confirming surgery. *Ann Plast Surg*. 2020;84:334–340.
13. Stocco C, Figus A, Razzano S. Upgrading the BREAST-Q questionnaire with donor site evaluation after PAP flap breast reconstruction. *J Plast Reconstr Aesthet Surg*. 2018;71:928–929.
14. Cohen WA, Mundy LR, Ballard TN, et al. The BREAST-Q in surgical research: a review of the literature 2009-2015. *J Plast Reconstr Aesthet Surg*. 2016;69:149–162.
15. Stocco C, Berton F, Papa G, et al. Vicryl hypersensitivity test with histological response. *Dermatitis*. 2016;27:145–146.
16. Nelson L, Whallett EJ, McGregor JC. Transgender patient satisfaction following reduction mammoplasty. *J Plast Reconstr Aesthet Surg*. 2009;62:331–334.
17. Alexander J, Hobbs SJ, May K, et al. Postural characteristics of female dressage riders using 3D motion analysis and the effects of an athletic taping technique: a randomised control trial. *Phys Ther Sport*. 2015;16:154–161.
18. Cherubino M, Scamoni S, Maggiulli F, et al. Breast reconstruction by tissue expansion: what is the integrity of the chest wall? *J Plast Reconstr Aesthet Surg*. 2016;69:e48–e54.
19. Papa G, Pangos M, Renzi N, et al. Five years of experience using a dermal substitute: indications, histologic studies, and first results using a new single-layer tool. *Dermatol Surg*. 2011;37:1631–1637.
20. Sisti A, Grimaldi L, Tassinari J, et al. Nipple-areola complex reconstruction techniques: a literature review. *Eur J Surg Oncol*. 2016;42:441–465.
21. Losco L, Cigna E. Aesthetic refinements in C-V flap: raising a perfect cylinder. *Aesthet Surg J*. 2018;38:NP26–NP28.
22. Cregten-Escobar P, Bouman MB, Buncamper ME, et al. Subcutaneous mastectomy in female-to-male transsexuals: a retrospective cohort-analysis of 202 patients. *J Sex Med*. 2012;9:3148–3153.