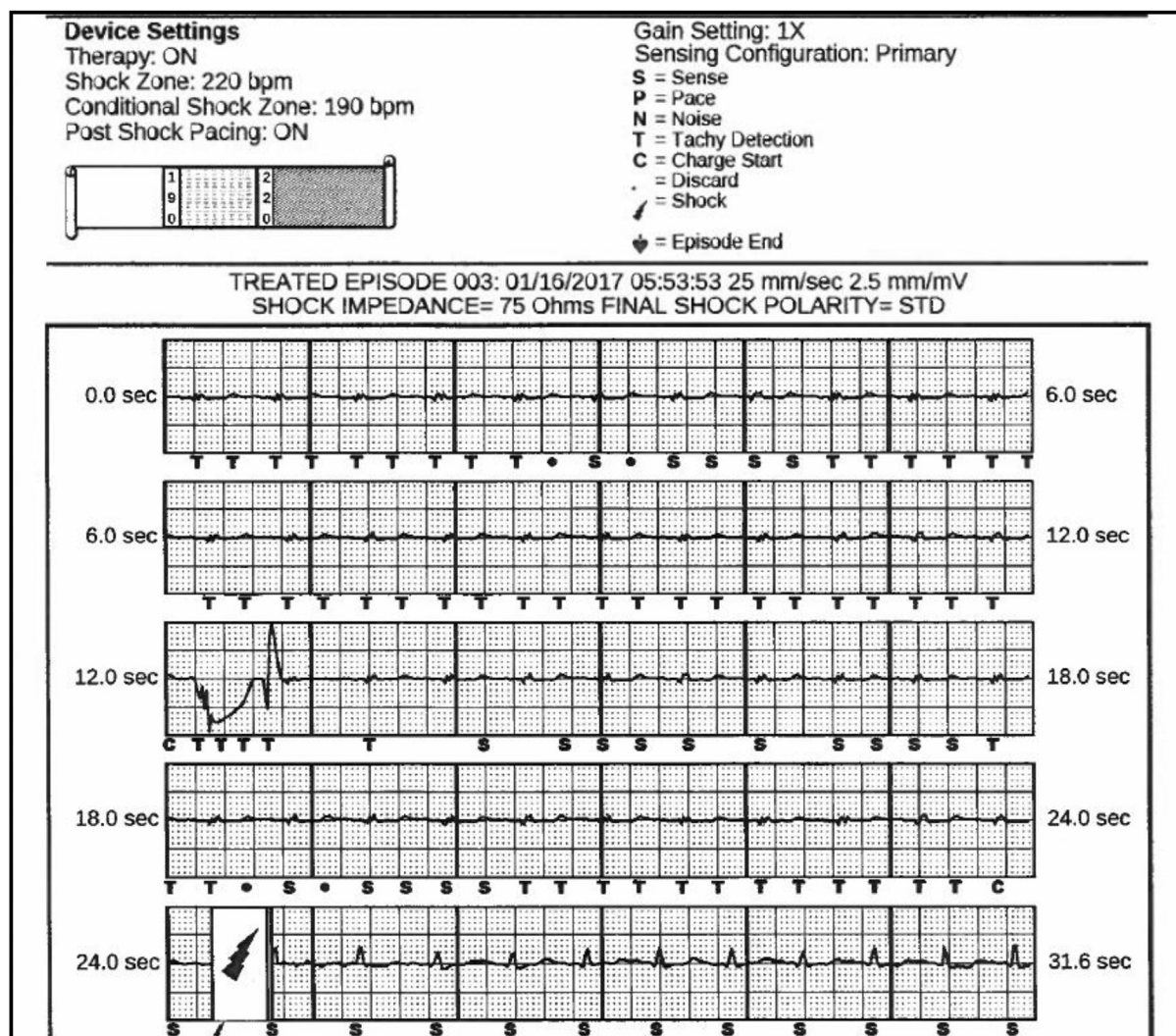


# T-wave oversensing from postural changes: A rare cause of inappropriate shock from a subcutaneous defibrillator



Muhammad R. Afzal, MD, Auroa Badin, MD, Raul Weiss, MD, Ralph Augustini, MD, John D. Hummel, MD

From the Department of Internal Medicine, Division of Cardiovascular Medicine, The Ohio State University Wexner Medical Center, Columbus, Ohio.



**Figure 1** Figure shows the inappropriate shock due to reduction of QRS amplitude and thus leading to T-wave oversensing.

**KEYWORDS** Inappropriate ICD shock; Subcutaneous ICD (Heart Rhythm Case Reports 2017;3:380–383)

**Address reprint requests and correspondence:** John D. Hummel, MD, FACC, FAHA, Davis Heart & Lung Research Inst., The Ohio State University, 473 West 12th Ave, Columbus, OH 43210. E-mail address: [john.hummel@osumc.edu](mailto:john.hummel@osumc.edu).

## Introduction

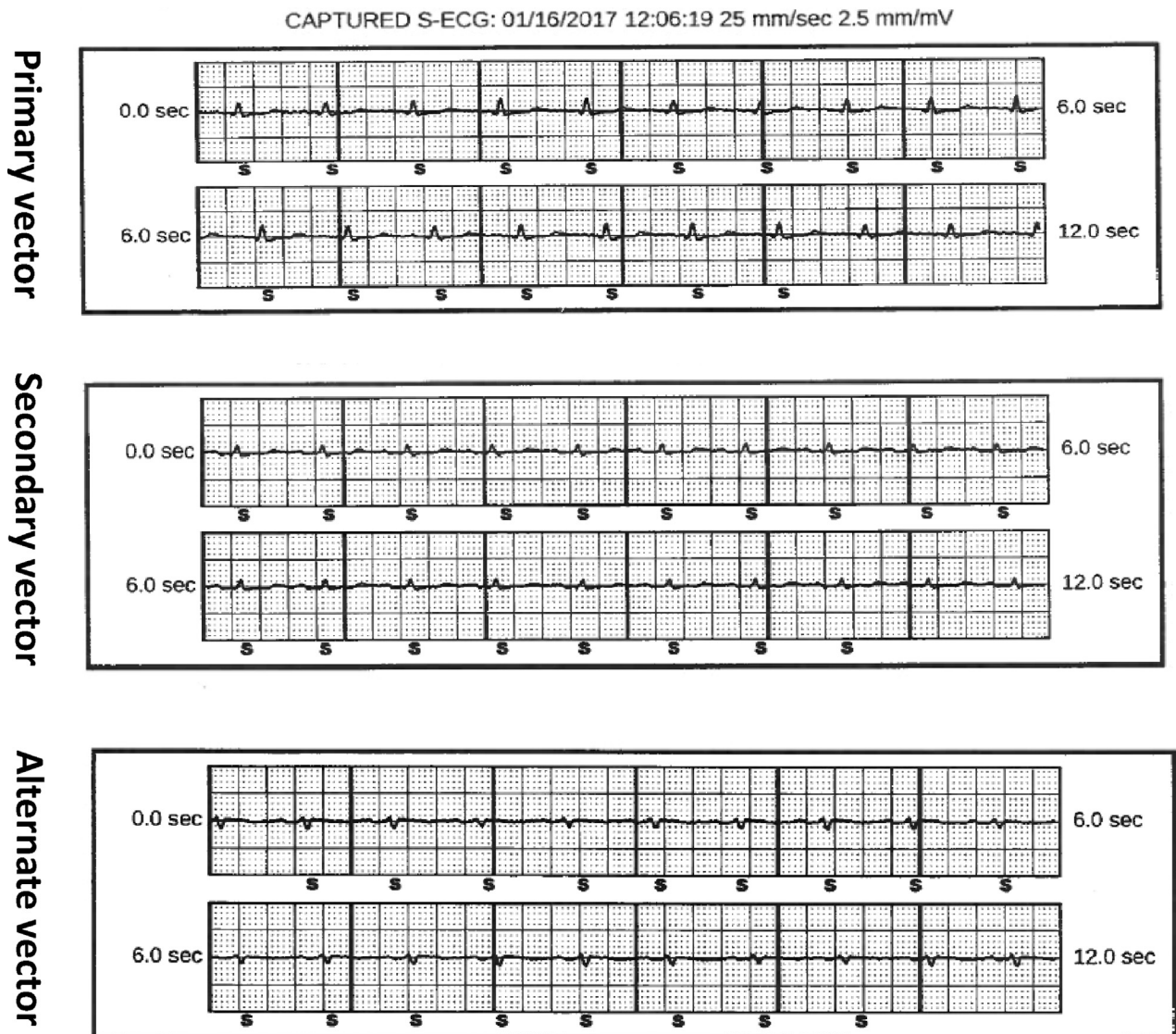
Inappropriate shock therapy from T-wave oversensing (TWOS) is a well-described complication in patients with subcutaneous implantable cardioverter-defibrillator (S-ICD). We report a case of inappropriate shock from TWOS during postural change.

**KEY TEACHING POINTS**

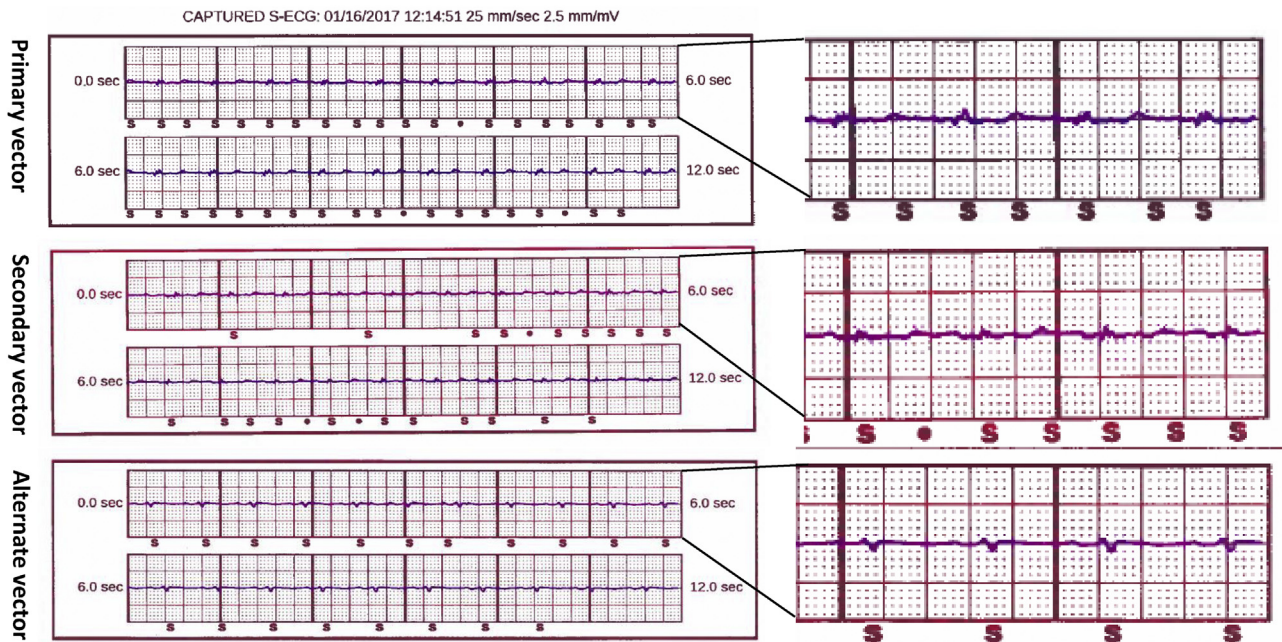
- Inappropriate shock therapy from T-wave oversensing (TWOS) is the most common reason for inappropriate shocks in patients with a subcutaneous implantable cardioverter-defibrillator (S-ICD).
- Postural changes can lead to diminished QRS amplitude, resulting in TWOS.
- Screening of vectors in left lateral position should be considered in patients with risk of TWOS.

**Case report**

A 38-year-old man with history of hypertrophic obstructive cardiomyopathy and S-ICD for primary prevention presented to the emergency room after 2 shock therapies from the device. The first shock occurred during sleep. The second shock occurred while the patient was lying on his left side. He did not have any palpitation, chest pain, or shortness of breath prior to the second shock. His comorbidities included morbid obesity, obstructive sleep apnea, and hypertension. Complete blood count and basic metabolic profile performed in the emergency room did not reveal any significant abnormality. A 12-lead electrocardiogram (ECG) revealed normal sinus rhythm with normal PR, QRS, and QT intervals. Device interrogation revealed that all the parameters were within



**Figure 2** Figure showing the electrograms from the programmer in the primary, secondary, and alternate vectors in the supine posture. There is no evidence of reduction in the amplitude of QRS and, thus, T-wave oversensing.



**Figure 3** Figure showing the electrograms from the programmer in the primary, secondary, and alternate vectors in the left lateral position. There is significant reduction in the amplitude of QRS and, thus, T-wave oversensing in the primary and secondary vectors. The alternate vector is unaffected and was programmed as the sensing vector.

normal limits. The device was programmed with dual zones. The patient had the primary vector (corresponding to lead I) as the programmed sensing vector. Both shocks were inappropriate owing to diminished amplitude of QRS and thus resulting in TWOS (Figure 1). During device interrogation, all 3 vectors (primary, secondary, and alternate, corresponding to leads I, II, and AVF, respectively) were screened in and did not reveal any change in the size of QRS (Figure 2). The patient's history of shock while lying on the left side prompted us to check all the vectors in the left lateral position. There was reduction in the amplitude of QRS and thus TWOS in the primary and secondary vectors in the left lateral posture; however, the alternate vector was unaffected (Figure 3). A chest radiograph was performed to assess the location of the shocking coil and pulse generator. There was no significant change in the position of the shocking coil or pulse generator when compared with radiograph position at the time of device implantation. A treadmill ECG was performed to assess TWOS at peak exercise. There was no significant increase in the T-wave amplitude during exercise. The reduction in the size of QRS for the primary and secondary vectors in the left lateral position was reproducible and always led to TWOS. However, the alternate vector was unaffected by postural changes and was thus selected as the final programmed vector.

## Discussion

TWOS was the most common reason for inappropriate shocks in patients with S-ICD.<sup>1</sup> Owing to the presence of electrodes outside the chest cavity and variable distance

from the heart, the sensing vectors are not immune to errors. In earlier experience with S-ICD, the incidence of inappropriate shock due to TWOS was significantly higher; however, this has steadily decreased in the more contemporary experience. This has been attributed to the prescreening process, routine dual-zone programming, and introduction of newer discrimination algorithms. The current S-ICD system incorporates several strategies to minimize TWOS. Using a specially designed cutaneous ECG assessment tool, patients are screened prior to implant. This tool identifies patients with large T waves, in ratio to the R wave, that increase the risk of TWOS. During implant, the S-ICD evaluates 3 possible sensing vectors and chooses one that has minimum potential for TWOS. The device also incorporates algorithms that measure the minimum and maximum amplitudes of each potential QRS complex, time intervals between detections, widths of each detected complex, and morphologic comparison of the currently detected complex to both the previous complex and a stored normal sinus rhythm, known as the "Reference ECG." Subsequently, an improvement of the algorithm by comparing the morphology of 3 successive detections to identify when 2 similar QRS complexes are separated by a dissimilar T-wave complex resulted in significant reduction of inappropriate shocks due to TWOS.<sup>2-4</sup> However, several of these updates are not available in the devices implanted prior to availability of newer software (personal communication with the industry representative).

In a recent study of hypertrophic obstructive cardiomyopathy patients who underwent S-ICD, 1 patient received an



inappropriate shock due to reduction in QRS amplitude during bending over.<sup>5</sup> There have been no other reports of inappropriate shocks due to postural changes in the large series of S-ICD.<sup>6</sup> In the current case, the primary and secondary vectors were affected by the postural change. Primary and secondary vectors correspond to ECG leads III and II, respectively, and incorporate the pulse generator as an essential component of these vectors. We believe that a change in the position of the can in left lateral position is the probable reason for the diminished QRS and thus TWOS. As patients with hypertrophic obstructive cardiomyopathy have had increased incidence of inappropriate shocks, these patients may be at higher risk of TWOS during postural changes as well.

In summary, this case highlights a unique issue that should be considered in every patient who suffers an inappropriate shock, especially owing to diminished size of QRS. All 3 vectors should be checked in the left lateral position to assess for reduction in the amplitude of QRS.

## References

1. Olde Nordkamp LR, Brouwer TF, Barr C, Theuns DA, Boersma LV, Johansen JB, Neuzil P, Wilde AA, Carter N, Husby M, Lambiase PD, Knops RE. Inappropriate shocks in the subcutaneous ICD: incidence, predictors and management. *Int J Cardiol* 2015;195:126–133.
2. Brisben AJ, Burke MC, Knight BP, Hahn SJ, Herrmann KL, Allavattam V, Mahajan D, Sanghera R, Gold MR. A new algorithm to reduce inappropriate therapy in the S-ICD system. *J Cardiovasc Electrophysiol* 2015;26:417–423.
3. Kooiman KM, Knops RE, Olde Nordkamp L, Wilde AA, de Groot JR. Inappropriate subcutaneous implantable cardioverter-defibrillator shocks due to T-wave oversensing can be prevented: implications for management. *Heart Rhythm* 2014;11:426–434.
4. Gold MR, Weiss R, Theuns DA, Smith W, Leon A, Knight BP, Carter N, Husby M, Burke MC. Use of a discrimination algorithm to reduce inappropriate shocks with a subcutaneous implantable cardioverter-defibrillator. *Heart Rhythm* 2014;11:1352–1358.
5. Weinstock J, Bader YH, Maron MS, Rowin EJ, Link MS. Subcutaneous implantable cardioverter defibrillator in patients with hypertrophic cardiomyopathy: an initial experience. *J Am Heart Assoc* 2016;5:e002488.
6. Lambiase PD, Gold MR, Hood M, Boersma L, Theuns DA, Burke MC, Weiss R, Russo AM, Kaab S, Knight BP. Evaluation of subcutaneous ICD early performance in hypertrophic cardiomyopathy from the pooled EFFORTLESS and IDE cohorts. *Heart Rhythm* 2016;13:1066–1074.