

Original Article

Epidural scarring after lumbar disc surgery: Equivalent scarring with/without free autologous fat grafts

M. Dobran, D. Brancorsini¹, M. Della Costanza, V. Liverotti, F. Mancini, D. Nasi, M. Iacoangeli, M. Scerrati

Departments of Neurosurgery and ¹Pathological Anatomy, Umberto I General Hospital, Università Politecnica delle Marche, Ancona, Italy

E-mail: *M. Dobran - dobran@libero.it; D. Brancorsini - donatella.brancorsini@ospedaleiruni.marche.it; M. Della Costanza - martina.dellacostanza@mail.com; V. Liverotti - vale.liverotti86@gmail.com; F. Mancini - Fabrizio.geremia.mancini@gmail.com; D. Nasi - davidenasi83@libero.it; M. Iacoangeli - neurotra@tiscali.it; M. Scerrati - mscerrati@virgilio.it

*Corresponding author

Received: 18 April 17 Accepted: 28 June 17 Published: 01 August 17

Abstract

Background: To limit epidural fibrosis and prevent scar formation/nerve tethering that may contribute to chronic postoperative pain; some surgeons have utilized epidural autologous fat grafts following lumbar microdiscectomy.

Methods: We investigated the correlation between post-microdiscectomy epidural scarring [including select magnetic resonance imaging (MRI) studies] and clinical outcomes in 36 patients operated for symptomatic. MRI documented L4-L5 and L5-S1 disk herniations with (18 patients) and without (18 patient) the application of free fat grafts. In addition, histological evaluation of the original fat grafts was performed in 4 patients requiring additional surgery.

Results: We found no clear association between the use of autologous graft fats and the clinical outcomes in this study.

Conclusion: In this preliminary study involving only 36 patients, the prospective randomized use of free autologous fat grafts did not appear to influence outcomes following microdiscectomy.

Key Words: Epidural fibrosis, failed back syndrome, microdiscectomy, post-discectomy syndrome

Access this article online

Website:

www.surgicalneurologyint.com

DOI:

10.4103/sni.sni_142_17

Quick Response Code:

INTRODUCTION

Epidural fibrosis following spinal surgery occurs because fibrotic tissue replaces epidural fat. For many years, the application of free fat grafts after microdiscectomy had been widely used to prevent epidural scarring, but the results were controversial.^[1,2,6] We still do not know if epidural fat replacement reduces epidural fibrosis and improves outcomes. The purpose of this study was to compare the clinical outcomes for patients undergoing microdiscectomy and treated with and without the application of epidural autologous free fat grafts.

MATERIALS AND METHODS

Lumbar microdiscectomies (interlaminar approaches) were performed at the L4-L5 (17 patients) and

This is an open access article distributed under the terms of the Creative Commons Attribution-NonCommercial-ShareAlike 3.0 License, which allows others to remix, tweak, and build upon the work non-commercially, as long as the author is credited and the new creations are licensed under the identical terms.

For reprints contact: reprints@medknow.com

How to cite this article: Dobran M, Brancorsini D, Costanza MD, Liverotti V, Mancini F, Nasi D, et al. Epidural scarring after lumbar disc surgery: Equivalent scarring with/without free autologous fat grafts. *Surg Neurol Int* 2017;8:169. <http://surgicalneurologyint.com/Epidural-scarring-after-lumbar-disc-surgery:-Equivalent-scarring-with/without-free-autologous-fat-grafts/>

L5-S1 (19 patients) levels in 36 patients, with an average age of 39.4 years [Table 1]. All patients had magnetic resonance imaging (MRI)-documented lumbar disc herniations, radiculopathy, and had failed conservative treatment for at least 2 months. Patients were randomized into two groups: those with (18 patients) and those without (18 patients) the application of autologous free fat grafts (1 cc fat over the dura/roots). No epidural drains were placed.

Outcomes, MRI, and statistical postoperative analyses

Preoperatively, all patients underwent MRI studies, as well as evaluations utilizing the visual analogue scale (VAS) and Oswestry Disability Index (ODI) scores. Postoperatively, the VAS and ODI were repeated at 1 and 6 months in all patients, whereas MRI studies were randomly obtained at 6 postoperative months in only 15 patients (8 without fat grafts and 7 with fat grafts). Statistics analyses were performed utilizing the paired *t*-test (a *P* value less than 0.05 was considered significant).

RESULTS

Operative data and clinical outcome

For both groups, the mean operative time was 60 and the mean length of hospital stay was 4 days. The mean preoperative and all postoperative (1 month, 6 months) ODI and VAS scores remained comparable for both groups [Table 1].

Epidural fibrosis on MRI and clinical outcome

Select postoperative MRI scans were randomly performed in 15 patients (excluding the four patients operated on early after their first surgery for complications). These studies showed no correlation between epidural fibrosis and symptoms. In fact, 6 patients exhibited MR-documented focal compression of the dural sac but were asymptomatic (e.g., no symptoms, no deficits).

Postoperative complications and histological evaluation of the fat graft

One month post-operatively, 1 patient required secondary surgery (laminectomy/fusion) to address a lumbar fracture.^[3-5] During surgery, the prior fat graft was removed for histological examination. Three other patients required secondary surgery for disc recurrences. Histological evaluation of their fat grafts confirmed normal fibroblast cells in 3 patients; with only one showing nearly entire replacement of the fat graft by fibrous tissue [Figure 1]. Note, repeat surgery for these latter 3 patients likely reflected insufficient disc removal at the of original surgery (e.g., inadequate visualization and shortcomings of the microdiscectomy approach).

DISCUSSION

The epidural fibrosis around dura mater and nerve roots at the operative site after microdiscectomy is a possible

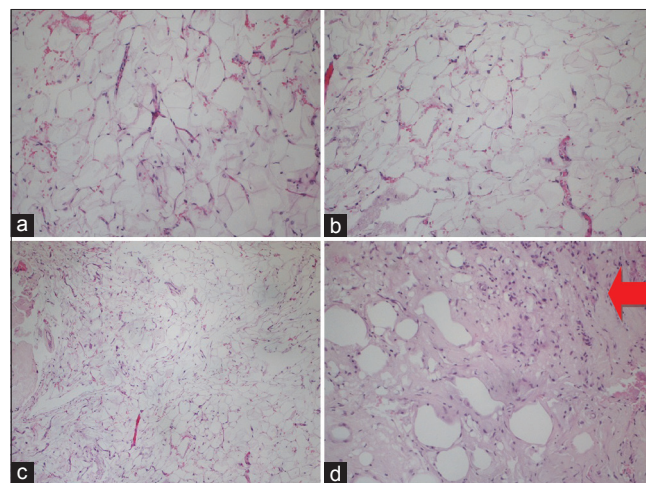


Figure 1: H and E specimens of autologous graft-fat. (a-c) Normal adipocytes with no fibroblasts invasion. (d) The arrow shows fibroblast invasion of the autologous free fat -graft

Table 1: Baseline characteristic and clinical outcome (VAS and ODI at 1 and 6 months after surgery) of the two groups

Data	With fat graft	No fat graft	<i>P</i>
Number of Patients	18	18	/
L4-L5 discs	10	7	0.5
L5-S1 discs	8	11	0.5
Average age (Range)	42.33 years (24-59 years)	42.44 years (23-57 years)	0.48
Males	10	12	
Females	8	6	
VAS scores (mean)			
Preoperative	8.56	9.1	0.09
1 month postop	3.50	2.89	0.17
6 months postop	1.72	1.44	0.23
ODI scores (mean)			
Preoperative	85.67	84.89	0.44
1 month postop	36.44	34.11	0.37
6 months postop	16.33	12.33	0.09

cause of failed back syndrome. Nerve fibers encased in collagenous scar tissue suffer an increase in neural tension, impairment of axoplasmic transport, and restriction of arterial supply and venous return. Compression of nerve tissue can induce clinical symptoms such as numbness, pain, and muscle weakness.^[7,8] Recently, many materials including silastic, Dacron, methacrylate, synthetic foam, elastase, etc. have been evaluated to prevent peridural scar with no clear documentation of beneficial results. The autologous free fat graft is the most popular and economic material used to prevent scar formation.

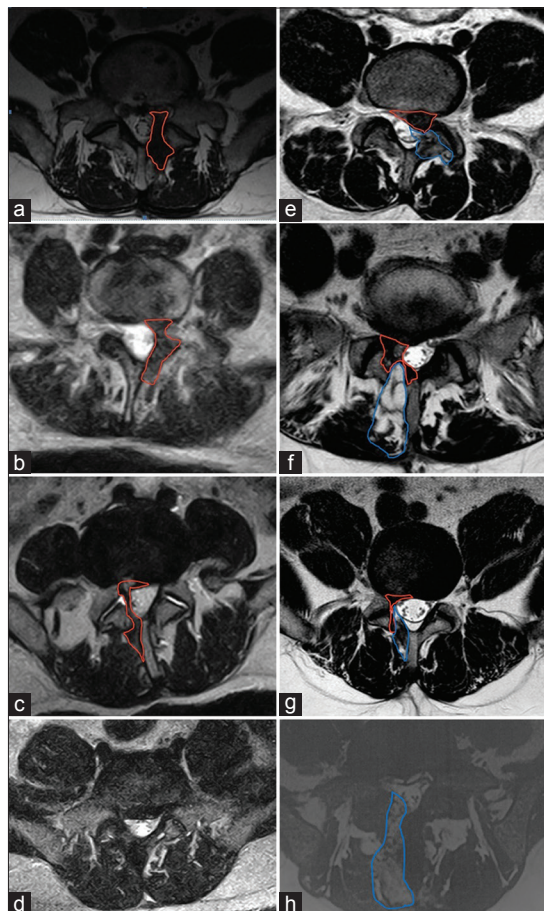


Figure 2: Axial MRI T2W images at the level of surgical access. (a-c) Patients operated without autologous graft-fat with evidence of scar tissue formation (red line). (d) Patient operated without autologous graft-fat without sign of scar tissue. (e-g) Patients operated with positioning of autologous fat-graft (blue line) and evidence of scar formation (red line) (h) Patient operated with positioning of autologous fat-graft (blue line), without sign of scar tissue formation

In this series, the histology of the removed fat graft in 2 patients showed normal amounts of fibroblasts in the fat graft, whereas a third showed colonization by fibroblasts.

In the present study, the absence of the autologous free fat graft in microdiscectomy was not correlated with scar formation on select MRI images [Figure 2] or clinical outcomes.

CONCLUSION

In conclusion, as documented in this study, the use of peridural free fat grafts following lumbar microdiscectomy did not change the clinical outcome. Furthermore, select MRI images documented that free autologous fat grafts did not prevent postoperative scar formation. Moreover, the main cause of persistence of pain after microdiscectomy in our series was related to insufficiency of first surgery (inadequate disc removal/nerve root decompression), as demonstrated in the three patients with early disc herniation recurrences.

Financial support and sponsorship

Nil.

Conflicts of interest

There are no conflicts of interest.

REFERENCES

- Annertz M, Jonsson B, Strömqvist B, Holt S. No relationship between epidural fibrosis and sciatica in the lumbar postdiscectomy syndrome: A study with contrast-enhanced magnetic resonance imaging in symptomatic and asymptomatic patients. *Spine (Phila Pa 1976)* 1995;20:449-53.
- Coskun E, Suzer T, Topuz O, Zencir M, Pakdemirli E, Tahta K. Relationships between epidural fibrosis, pain, disability, and psychological factors after lumbar disc surgery. *Eur Spine J* 2000;9:218-23.
- Dobran M, Iacoangeli M, Nasi D, Nocchi N, Di Rienzo A, Di Somma L, et al. Posterior titanium screw fixation without debridement of infected tissue for the treatment of thoracolumbar spontaneous pyogenic spondylodiscitis. *Asian Spine J* 2016;10:465-71.
- Dobran M, Iacoangeli M, Di Somma LGM, Di Rienzo A, Colasanti R, Nocchi N, et al. Neurological outcome in a series of 58 patients operated for traumatic thoracolumbar spinal cord injuries. *Surg Neurol Int* 2014;5(Suppl 7):S329-32.
- Dobran M, Nasi D, Brunozzi D, Di Somma L, Gladi M, Iacoangeli M, et al. Treatment of unstable thoracolumbar junction burst fractures: Short-segment pedicle fixation with inclusion of fracture level versus long-term instrumentation. *Acta Neurochir (Wien)* 2016;158:1883-9.
- Geisler FH. Prevention of peridural fibrosis: Current methodologies. *Neurol Res* 1992;21(Suppl 1):S9-22.
- Martin-Ferrer S. Failure of autologous fat grafts to prevent post operative epidural fibrosis in surgery of the lumbar spine. *Neurosurgery* 1989;24:718-21.
- Merrild U, Sogaard IB. Sciatica caused by perifibrosis of the sciatic nerve. *J Bone Joint Surg* 1986;68:706.