

Location of Ruptured Bullae in Secondary Spontaneous Pneumothorax

Jinseok Choi, M.D.¹, Hyo Yeong Ahn, M.D.¹, Yeong Dae Kim, M.D.¹,
Hoseok I, M.D.¹, Jeong Su Cho, M.D.¹, Jonggeun Lee, M.D.²

¹Department of Thoracic and Cardiovascular Surgery, Pusan National University Hospital, Medical Research Institution, Pusan National University School of Medicine, ²Department of Thoracic and Cardiovascular Surgery, Jeju National University Hospital, Jeju National University School of Medicine

Background: The surgical treatment of secondary spontaneous pneumothorax (SSP) can be complicated by fragile lung parenchyma. The preoperative prediction of air leakage could help prevent intraoperative lung injury during manipulation of the lung. Common sites of bulla development and ruptured bullae were investigated based on computed tomography (CT) and intraoperative findings. **Methods:** The study enrolled 208 patients with SSP who underwent air leak control through video-assisted thoracoscopic surgery (VATS). We retrospectively reviewed the sites of bulla development on preoperative CT and the rupture sites during VATS. **Results:** Of the 135 cases of right-sided SSP, the most common rupture site was the apical segment (31.9%), followed by the azygoesophageal recess (27.4%). Of the 75 cases on the left side, the most common rupture site was the apical segment (24.0%), followed by the anterior basal segment (17.3%). **Conclusion:** The azygoesophageal recess and parenchyma along the cardiac border were common sites of bulla development and rupture. Studies of respiratory lung motion to measure the pleural pressure at the lung surface could help to determine the relationship between cardiogenic and diaphragmatic movement and bulla formation or rupture.

Key words: 1. Secondary spontaneous pneumothorax
2. Bullae
3. Chest computed tomography
4. Video-assisted thoracoscopic surgery

Introduction

In cases of secondary spontaneous pneumothorax (SSP) requiring surgical intervention, it can be difficult to locate air leaks because of diffuse adhesions and fragile lung parenchyma. To prevent unnecessary manipulation and intraoperative injury of the lung, rupture sites should be predicted preoperatively. Herein, we investigated the common sites of bulla

development and rupture.

Methods

The study enrolled 208 patients with SSP who underwent air leak control through video-assisted thoracoscopic surgery (VATS) from 2006 to 2014. In this study, only patients with SSP induced by chronic obstructive pulmonary disease were included; patients

Received: March 14, 2017, Revised: July 10, 2017, Accepted: July 11, 2017, Published online: December 5, 2017

Corresponding author: Hyo Yeong Ahn, Department of Thoracic and Cardiovascular Surgery, Pusan National University Hospital, Medical Research Institute, Pusan National University School of Medicine, 179 Gudeok-ro, Seo-gu, Busan 49241, Korea (Tel) 82-51-240-7267 (Fax) 82-51-243-9389 (E-mail) pretty2124@hanmail.net

© The Korean Society for Thoracic and Cardiovascular Surgery. 2017. All right reserved.

© This is an open access article distributed under the terms of the Creative Commons Attribution Non-Commercial License (<http://creativecommons.org/licenses/by-nc/4.0>) which permits unrestricted non-commercial use, distribution, and reproduction in any medium, provided the original work is properly cited.

Table 1. Perioperative characteristics

Characteristic	General anesthesia (n=175)	Epidural anesthesia (n=33)	p-value
Age (yr)	63.8±12.8	62.03±15.34	0.4
Gender (male:female)	148:27	24:9	
Preoperative chest tube drainage (day)	11.84±15.71	11.23±8.17	0.40
Pulmonary lung function			
Forced expiratory volume in 1 second/forced vital capacity	61.93±9.02	18.40±2.55	0.00 ^{a)}
Chronic obstructive pulmonary disease grade	66.84±5.75	22.57±6.22	0.24
Stage I	105	0	
Stage II	52	0	
Stage III	18	0	
Stage IV	0	33	
Preoperative dyspnea score based on American Thoracic Society	1.73±0.49	3.07±0.25	0.00 ^{a)}

Values are presented as mean±standard deviation or number (%).

^{a)}Statistically significant difference.

with SSP caused by connective tissue disease, malignancy, or infectious lung disease were excluded.

Although conservative management (e.g., intercostal tube drainage over 2 weeks or pleurodesis with a 50% glucose solution administered through a chest tube) was usually performed in patients with SSP, under the following conditions surgical intervention was considered: a persistent air leak for more than 7 days, incomplete lung expansion due to a persistent air leak, and more than 2 recurrences of pneumothorax. Surgical intervention was performed under epidural anesthesia in patients with 2 recurrences of pneumothorax and poor results on pulmonary function tests (PFTs), such as forced expiratory volume in 1 second (FEV₁) <1.2 L, FEV₁/forced vital capacity <40%, diffusing capacity of the lungs for carbon monoxide <60%, dyspnea >grade 3 (based on the American Thoracic Society score), or arterial blood gas analysis on room air showing PaCO₂ >50 mm Hg and PaO₂ <60 mm Hg (Table 1).

Because bullae can develop in multiple lesions, all sites of bulla development were investigated using preoperative computed tomography (CT), and the bulla rupture sites were explored during VATS (with a single rupture in each case). Complete adhesiolysis was performed in most cases, although in patients with poor PFTs who were vulnerable to a long operating time with 1-lung ventilation, the bulla rupture site was predicted from the preoperative CT, and minimal adhesiolysis was performed to find the ruptured bulla under epidural anesthesia.

The air leaks were controlled by bulla ligation us-

ing a loop, adhesiolysis, chemical pleurodesis, or by covering the leak with visceral pleura. Prior to 2012, chemical pleurodesis using talc was usually performed at Pusan National University Hospital; however, since then, leaks have been covered with visceral pleura after a fatal complication that may have resulted from the use of talc.

All medical records were reviewed retrospectively. This study was approved by the institutional review board of Pusan National University Hospital (NO. H1705-007-055). Informed consent was not required for this retrospective study.

Statistical analyses were performed in R 3.3.2 using SAS ver. 9.3 (SAS Institute, Cary, NC, USA). The Pearson chi-square goodness-of-fit test was used to compare proportions. A type I error rate of 5% was used for hypothesis testing.

Results

Of 208 patients with SSP, 135 were affected on the right side and had a total of 358 bullae. The most common site of bullae on the right side was the upper lobe (197 of 358, 55.0%), followed by the azygoesophageal recess in S6 and S7 (83 of 358, 23.1%) (Fig. 1). In the right upper lobe, the apical (107 of 358, 29.9%) and posterior (60 of 358, 16.8%) segments were the most common sites of bullae, and this distribution was statistically significant in comparison to a null hypothesis of uniform distribution (Table 2). The superior (46 of 358, 12.8%) and mediobasal (37 of 358, 10.3%) segments of the right

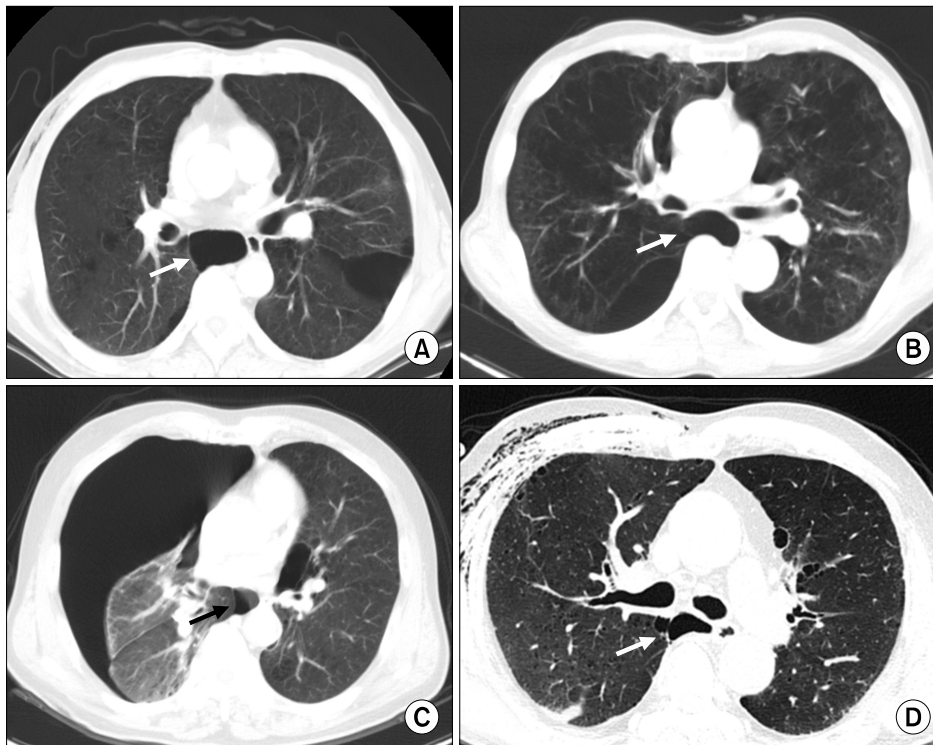


Fig. 1. (A–D) A ruptured bulla (arrow) in the azygoesophageal recess.

lower lobe located in the azygoesophageal recess (83 of 358, 23.2%) were the second most common sites of bullae; however, the distribution of bullae across these sites was not significantly different from the null hypothesis of uniform distribution (Table 2, Fig. 2).

Intraoperatively, we found that the most common site of bulla rupture was the lung apex, especially for bullae originating from the apical segment (43 of 135, 31.9%), and this trend was statistically significant in comparison to the null hypothesis of uniform distribution (Table 3). The second most common site was the azygoesophageal recess (35 of 135, 25.9%), with bullae originating from the superior segment of the right lower lobe (21 of 135, 15.6%) and the mediobasal segment of the right lower lobe (14 of 135, 10.4%), and this distribution was significantly different from the null hypothesis (Table 3). The third most common site was the parenchyma along the cardiac border, such as the medial segment of the right middle lobe (17 of 135, 12.6%); however, this trend was not significantly different from the null hypothesis of uniform distribution (Table 3, Fig. 2).

In the 73 cases on the left side, there were 277 bullae. The most common site of bullae was the ap-

ical (67 of 277, 24.2%) and posterior (64 of 277, 23.1%) segments of the left upper lobe, which showed a significantly non-uniform distribution (Table 2). The anterior segment (37 of 277, 13.4%) and inferior lingular (22 of 277, 7.9%) and anterobasal (21 of 277, 7.6%) segments of the left lower lobe were the second and third most common sites of bullae, although the distribution of bullae across these sites was not significantly different from the null hypothesis of uniform distribution (Table 2, Fig. 2). The most common site of bulla rupture was the apical segment (17 of 73, 23.3%) of the left upper lobe followed by the anterior basal segment (13 of 73, 17.8%) of the left lower lobe; both of these distributions were significantly non-uniform (Table 3). The third most common site of bulla rupture was the superior segment (12 of 73, 16.4%) of the left lower lobe located along the cardiac border, although this trend was not significant (Table 3).

Discussion

Bullectomy under VATS is used to control air leaks in patients with SSP. However, it can be technically difficult depending on the grade of diffuse adhesions,

Table 2. Common intraoperative sites of bullae			
Site	Pulmonary segment	Incidence	Residuals ^{a)}
Right			
Upper lobe	S1, apical	107 (29.9)	11.9
	S2, posterior	60 (16.8)	4.0
	S3, anterior	30 (8.4)	-1.0
Middle lobe	S4, lateral	14 (3.9)	-3.6
Lower lobe	S5, medial	27 (7.5)	-1.5
	S6, superior	46 (12.8)	1.7
	S7, mediobasal	37 (10.3)	0.2
	S8, anterobasal	13 (3.6)	-3.8
	S9, laterobasal	9 (2.5)	-4.5
	S10, posterobasal	15 (4.2)	-3.5
Total		358 (100.0)	
Left			
Upper lobe	S1, apical	67 (24.2)	7.5
	S2, posterior	64 (23.1)	6.9
	S3, anterior	37 (13.4)	1.8
	S4, superior lingular	16 (5.8)	-2.2
	S5, inferior lingular	22 (7.9)	-1.1
Lower lobe	S6, superior	19 (6.9)	-1.7
	S7, mediobasal	16 (5.8)	-2.2
	S8, anterobasal	21 (7.6)	-1.3
	S9, laterobasal	8 (2.9)	-3.7
	S10, posterobasal	7 (2.5)	-3.9
Total		277 (100.0)	

Values are presented as number (%).

^{a)}Residuals=(observed-expected)/square root of the expected, with null hypothesis of uniform distribution (p=0.1); right: goodness-of-fit test $\chi^2=223.96$, df=9, $p \leq 0.0001$; left: goodness-of-fit test $\chi^2=151.34$, df=9, $p \leq 0.0001$.

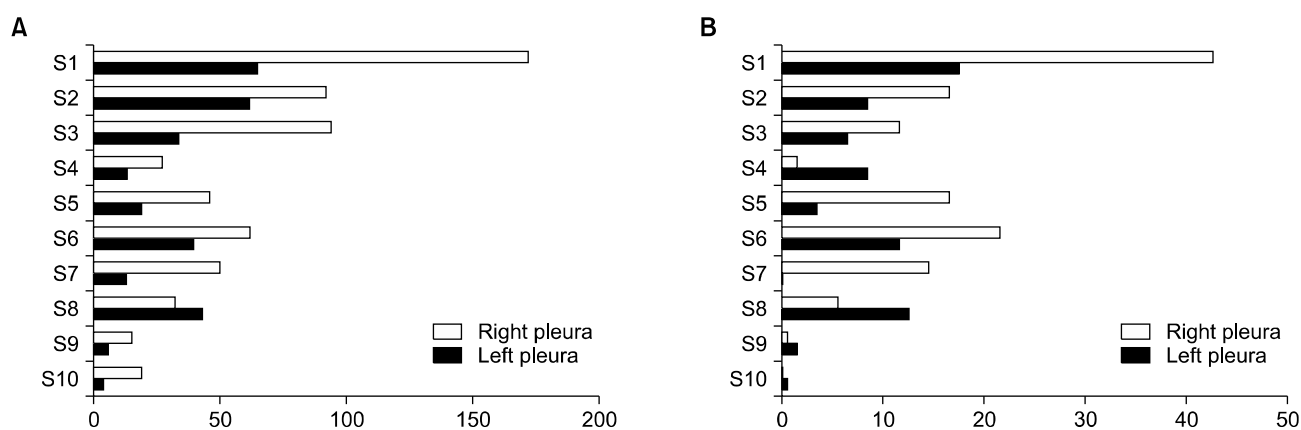


Fig. 2. Locations of bullae formation and rupture by pulmonary segment. (A) Locations of bullae by pulmonary segment. (B) Locations of ruptured bullae by pulmonary segment. S1, apical; S2, posterior; S3, anterior; S4, lateral (right) or superior lingular (left); S5, medial (right) or inferior lingular (left); S6, superior; S7, mediobasal; S8, anterobasal; S9, laterobasal; and S10, posterobasal segments.

underlying emphysema, and location of the ruptured bullae [1,2]. In addition, when there is air leak is near an area with a high density of adhesions that

need to be dissected fully around the bulla, it is not clear how many adhesions will have to be released in order to find the air leak.

Table 3. Common bulla rupture sites found intraoperatively

Site	Pulmonary segment	Incidence	Residuals ^{a)}
Right			
Upper lobe	S1, apical	43 (31.9)	8.0
	S2, posterior	16 (11.9)	0.7
	S3, anterior	12 (8.9)	-0.4
Middle lobe	S4, lateral	3 (2.2)	-2.9
	S5, medial	17 (5.2)	1.0
Lower lobe	S6, superior	21 (15.6)	2.0
	S7, mediobasal	14 (10.4)	0.1
	S8, anterobasal	6 (4.4)	-2.0
	S9, laterobasal	2 (1.5)	-3.1
	S10, posterobasal	1 (0.7)	-3.4
Total		135 (100.0)	
Left			
Upper lobe	S1, apical	17 (23.3)	3.6
	S2, posterior	8 (11.0)	0.3
	S3, anterior	6 (8.2)	-0.5
	S4, superior lingular	8 (11.0)	0.3
	S5, inferior lingular	3 (4.1)	-1.6
Lower lobe	S6, superior	12 (16.4)	1.7
	S7, mediobasal	1 (1.4)	-2.3
	S8, anterobasal	13 (17.8)	2.1
	S9, laterobasal	3 (4.1)	-1.6
	S10, posterobasal	2 (2.7)	-2.0
Total		73 (100.0)	

Values are presented as number (%).

^{a)}Residuals=(observed-expected)/square root of the expected with null hypothesis of uniform distribution ($p=0.1$); right: goodness-of-fit test $\chi^2=103.89$, $df=9$, $p\leq 0.0001$; left: goodness-of-fit test $\chi^2=35.08$, $df=9$, $p\leq 0.0001$.

The results of our study show that bullous lesions readily develop at the lung apex, which is also the most common site of bulla rupture (Fig. 2, Table 2), as has been the case in other case series.

Since there are strong correlations among trans-pulmonary pressure, lung compliance, and the density of alveoli caused by gravity [3-5], the apex was the most common site of bulla development and rupture in our study (Fig. 2, Tables 2, 3). However, some studies have reported that bullae in the recess between the descending aorta and thoracic vertebrae or the azygoesophageal recess are another common point of rupture and have recommended checking for air leaks in those areas [6,7]. In our series, the azygoesophageal recess (Fig. 1) was the second common site of bulla development and rupture on the right side. On the left side, the anterobasal segment of the left lower lobe located along the cardiac border was one of the significant common sites of bulla rupture

(Fig. 2, Table 3).

Considering the common sites of bulla development and rupture, pleural surface pressure appears to be not only affected by gravity but by cardiogenic motion [4,5] and diaphragmatic movement. This may result from the thin layer of pleural liquid that maintains the lung expansion driven by cardiogenic and diaphragmatic movement, which could, in turn, affect pleural surface pressure [5].

Therefore, in patients with no evidence of an air leak in the upper lobe, it is necessary to check for ruptured bullae in the azygoesophageal recess or along the cardiac border. Future development of techniques for measuring the pleural pressure at the lung surface with respiratory lung motion in cases of SSP could help to determine the relationship between cardiogenic and diaphragmatic movement and bulla formation or rupture.

Conflict of interest

No potential conflicts of interest relevant to this article are reported.

Acknowledgments

Yeong Dae Kim received a 2-year research grant from Pusan National University. This work was supported by the Department of Biostatistics, Clinical Trial Center, Biomedical Research Institute, Pusan National University Hospital. We thank the Department of Biostatistics, Clinical Trial Center, Biomedical Research Institute, Pusan National University Hospital for their support.

References

1. Noda M, Oishi H, Maeda S, et al. *Management of surgical approach for intractable secondary spontaneous pneumothorax*. *Kyobu Geka* 2011;64:291-5.
2. Zhang Y, Jiang G, Chen C, Ding J, Zhu Y, Xu Z. *Surgical management of secondary spontaneous pneumothorax in elderly patients with chronic obstructive pulmonary disease: retrospective study of 107 cases*. *Thorac Cardiovasc Surg* 2009;57:347-52.
3. Charalampidis C, Youroukou A, Lazaridis G, et al. *Physiology of the pleural space*. *J Thorac Dis* 2015;7(Suppl 1):S33-7.
4. Feller-Kopman D, Parker MJ, Schwartzstein RM. *Assessment of pleural pressure in the evaluation of pleural effusions*. *Chest* 2009;135:201-9.
5. Lai-Fook SJ. *Pleural mechanics and fluid exchange*. *Physiol Rev* 2004;84:385-410.
6. Asai K, Urabe N. *Secondary spontaneous pneumothorax associated with emphysema and ruptured bullae at the azygoesophageal recess*. *Gen Thorac Cardiovasc Surg* 2008;56:539-43.
7. Kawashima M, Murakawa T, Takahashi T, et al. *Secondary spontaneous pneumothorax due to a ruptured bulla at a left-sided azygoesophageal recess in a patient with right aortic arch*. *Kyobu Geka* 2013;66:563-5.