

Maxillary first molar with two palatal roots located under dental operating microscope

Prashant P. Shetty,¹
Madhusudan S. Astekar,² Ankit Jain,¹
Mihir Pandya¹

¹Department of Conservative and Endodontics; ²Department of Oral Pathology, Paher University, Pacific Dental College and Hospital, Udaipur, India

Abstract

An awareness and understanding of the presence of an additional root and unusual root canal morphology is essential as it determines the successful outcome of endodontic treatment. A thorough knowledge of basic root canal anatomy and its variation is necessary for successful completion of endodontic treatment. This report points to the importance of looking for additional roots and canals with the help of operating microscope. Finding additional roots and canals would enable clinician to successfully treat a case that would otherwise not be successful.

Introduction

A thorough knowledge of tooth morphology, careful interpretation of angled X-rays, proper access preparation and a detailed exploration of the tooth are essential prerequisites for a successful treatment outcome. Magnification, operating microscope, loupes and illumination are aids that must be utilized to achieve this goal.¹ Anatomical characteristics of permanent maxillary molar are generally described as a group of teeth with three roots, one palatal and two buccal roots. The variation include one,² four,³ five⁴ individual roots and unusual morphology⁵ of root canal systems within individual roots. Case reports with five⁶ and six⁷ root canals or with a C-shaped canal configuration⁸ have also been reported earlier.

Christie *et al.* analyzed endodontic treatment in 16 maxillary molars and of 6 extracted teeth with 2 palatal roots and classified these 22 molars into three types (I -III), according to root separation level and their divergences.³ The frequency of 2 palatal roots is low; however, a few cases have been reported in the literature (Saler and Goel BR. Frequency of fourth root canal in the maxillary first molar, an in-vitro study. 1995; unpublished data). Literature is reviewed regarding the presence of extra

canals in palatal root of maxillary molars.⁹ The incidence of 2 root canals in the palatal roots of maxillary molars has been reported to be 2-5.1%. Two canals in a single palatal root may present in one of the following types: i) two separate orifices, two separate orifices and two separate foramina; ii) two separate palatal roots, each with one orifice, one canal and one iii) one palatal root, one orifice, one orifice, a bifurcated canal and two foramina.

The present case comes under type 1 of the Christie *et al.* classification. A dental operating microscope, with its magnification and illumination helps in the easy detection of hidden canals and allows a more detailed vision of the internal root canal system. With the use of the microscope, the success rate has definitely increased in the recent past. A case report of a maxillary first molar with four root canals (one mesiobuccal, one distobuccal and two palatal) using a dental operating microscope is presented here.

Case Report

A 35-year-old male patient reported with a history of pain in relation to the upper right posterior region. Root canal treatment of the particular tooth in question was initiated by a general dental practitioner. Even after the bio-mechanical preparation of all the three canals to the proper working length, the pain did not subside. The patient was referred for further treatment to the Pacific Dental College, Udaipur. Under local anesthesia of 2% lidocaine with 1:1,00,000 epinephrine, the temporary restoration was removed and the access preparation was evaluated for presence of any extra canals. Gates Glidden drills 1, 2 and 3 were used to flare the coronal portion of the canals to improve straight line access. Complete deroofting of pulp chamber was carried out, conventional triangular access preparation was modified to trapezoidal shape, and an exploration of the floor of chamber under a surgical operating microscope revealed four canal orifices. The palatal roots had two orifices, fairly well separated, exiting from the floor of the pulp chamber (Figures 1 and 2). The working length of each canal was estimated by means of an apex locator (Ray Pex 5, VDW GmbH, Germany) and confirmed with intra oral periapical X-ray (Figure 3). The canals were initially instrumented with stainless steel K files (n 10/15) under irrigation with 3% sodium hypochlorite. Biomechanical preparation of both the palatal canals was performed using the crown down technique with Protaper rotary instruments (Dentsply, Maillefer, Switzerland). Mesiobuccal and distobuccal canals were shaped by the crown down technique using a 35 master apical file for

Correspondence: Madhusudan S. Astekar, Department of Oral Pathology, Paher University, Pacific Dental College and Hospital, Udaipur, (Rajasthan), India.
Tel: 09413026974.
E-mail: madhu.tanu@gmail.com

Key words: anatomical variations, maxillary first molar, number of canals, dental operating microscope.

Received for publication: 16 November 2011.
Revision received: 13 December 2011.
Accepted for publication: 17 December 2011.

This work is licensed under a Creative Commons Attribution NonCommercial 3.0 License (CC BY-NC 3.0).

©Copyright P.P. Shetty *et al.*, 2012
Licensee PAGEPress, Italy
Clinics and Practice 2012; 2:e26
doi:10.4081/cp.2012.e26

mesiobuccal (MB) and a 40 for distobuccal (DB). Master cone radiograph was taken (Figure 4). Final irrigation with 17% EDTA followed by 3% sodium hypochlorite (Novo Dental Pvt. Ltd, India) was carried out. The root canal was dried with paper points. Obturation of root canal space was performed with gutta-percha (Dentsply, Maillefer, Switzerland) and AH plus resin sealer (Dentsply DeTrey GmbH, Germany) (Figure 5) using a lateral condensation technique and the tooth was restored with a posterior composite filling P60 (3M Filtek™, USA).

Discussion

The goal of root canal treatment is to obtain a clean root canal system thoroughly and to fill it in all dimensions. Canals are often left untreated because the dentist fails to recognize their presence. The variations in the canal anatomy play an important role in endodontic therapy. The majority of endodontic literature describe maxillary first molar having three root canals. Now with detail understanding of canal morphology with the advent of operating microscope and computed tomography, the occurrence of two palatal roots has been confirmed by Christie *et al.*³ Christie *et al.* speculated that maxillary molars with two palatal roots may be encountered once every three years in a busy endodontic practise. Slowey also reported maxillary molar with two palatal roots.¹⁰ In supernumerary roots, its formation could be related to external factors during odontogenesis. Rostein examined 1200 molars and found a 0.4% incidence

of maxillary molar with four roots.¹¹ The etiology behind formation is unclear. In supernumerary roots, formation could be related to external factors during odontogenesis. Curzon suggests that additional rooted molar trait has a high degree of genetic penetrance.¹²

There could be variation in root morphology in mandibular molars. Carlsen and Alexandersen suggest that if additional roots are present distolingually it should be termed Radix Entomolaris.¹³ If additional roots are present mesiobuccally it should be termed Radix Paramolaris.¹⁴

To determine the presence of additional root, there should be a slightly different approach besides normal procedural protocol, and the clinician should look for the following signs which might indicate the presence of additional root, such as cervical prominence, where it could be detected through periodontal probing. Extra cusp, which is present in combination with cervical prominence, should be X-rayed at different angulations:

i. Multiple radiographs: well angulated periapical fimages should be taken. (Mesio-angular, disto-angular, straight) when evaluating an endodontic failure.

ii. Digital radiography: this offers a variety of software features, significantly enhancing radiographic diagnostics in identifying hidden, calcified or untreated canals.

iii. Coronal flaring: this should be performed for a better visualization of the canal orifice.

iv. White line test: shelf of dentin meets the pulpal floor and forms a groove. It forms a visible road map that can be followed and explored to find canal orifice.

v. Red line test: in chronic cases, blood flows into the orifices, fins and isthmus areas thus serving as a road map for identification of canal orifices.

vi. Piezoelectric ultrasonic: troughing of grooves with ultrasonic tips (CPR tips).

vii. Examination of the pulp chamber floor with a sharp explorer (DG 16).

viii. Champagne bubble test using sodium hypochlorite: After cleaning and shaping procedures, the access cavity is flooded with NaOCl and the solution is observed to see if bubbles are emanating toward the occlusal table from canal orifice. A positive bubble reaction signifies that NaOCl is reacting with residual tissue within the instrumented or the missed canal, or with the residual chelator present within the prepared canal.

ix. Dyes: 1% methylene blue dye, a non-toxic biocompatible dye, is irrigated into the pulp chamber and subsequently rinsed thoroughly with water, dried and visualized to see where the dye has been absorbed. Frequently the dyes will be absorbed into the orifices, fins and isthmus areas.

x. Ruddle's solution: this irrigant is a *cocktail* containing 5% sodium hypochlorite

(NaOCl), hypaque and 17% EDTA. Hypaque is a water soluble, radiopaque, contrast solution which can be used to visualize root canal system anatomy, monitor the remaining wall thickness during preparation procedures, detect pathological defects and manage iatrogenic mishaps. The composition of the Ruddle solution simultaneously provides the *solvent action* of full strength NaOCl, *visualization* as its radiopacity closely matches that of gutta-percha, and improved *penetration* as the tension active agent lowers the surface tension.

- xi. Loupes.¹⁵
- xii. CT and spiral CT scan.^{2,16}
- xiii. Operating microscopes.^{17,18}

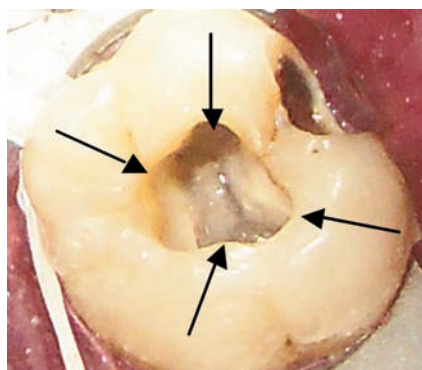


Figure 1. Clinical microscopic photograph showing four canals.

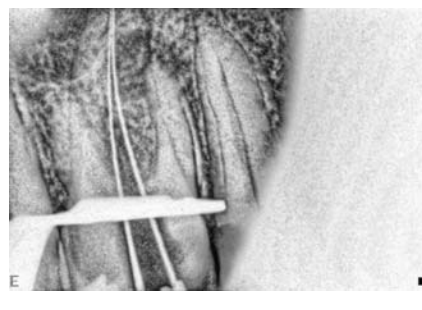


Figure 2. Periapical radiograph showing files in 2 palatal canals.

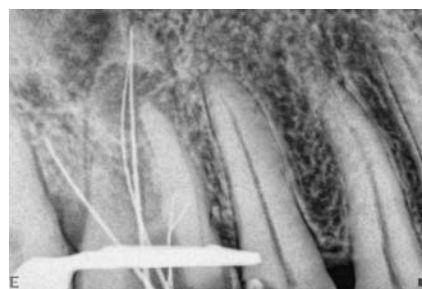


Figure 3. Working length confirmed using periapical radiograph.

Visualization during surgical and conventional endodontic treatment has historically been limited to two-dimensional dental radiography representative of a three-dimensional biological system and what could be seen with the naked eye. Today, endodontic treatment is to a large extent viewed as a microsurgical procedure. The use of optical magnification instruments, such as loupes, microscopes, endoscopes, and oroscopes, enables the

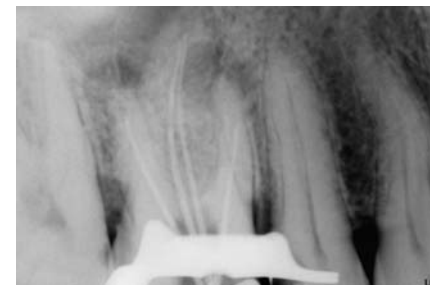

Figure 4. Mastercone intra oral periapical x-ray.

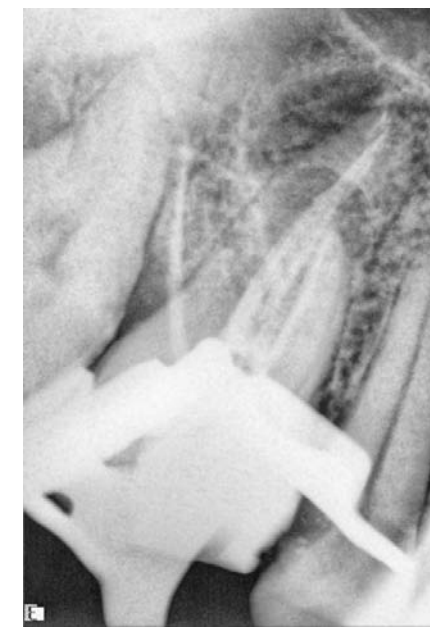

Figure 5. Periapical radiograph after obturation.



Figure 6. Dental operating microscope.

endodontist to magnify a specified treatment field beyond that perceived. Dental loupes are the most common magnification system used in dentistry. The dentist may find the ergonomics incorrect and may need to compensate with poor body posture, causing possible neck and back strain.

Ideal magnification with telescopic loupes is x 2.5. Baumann was the first to report the use and benefits of an operating microscope for conventional endodontics. Since then, the use of the surgical operating microscope (SOM) has evolved in the field of endodontics as an invaluable optical magnification instrument.

The magnification needs in endodontic treatment range from x 3 to x 30.

The advantages of using an SOM during surgical endodontic treatment are enhanced view of the surgical treatment field, fewer X-rays during the surgical procedure, and the ability to document the treatment. When viewing an endodontic treatment field through a microscope, the use of a standard dental mirror or micro mirror is usually required in conjunction with the microscope to overcome the angulation difficulties of certain tooth positions in the mouth. Saunders and Saunders¹⁸ stated that the most common reasons for endodontists not using the SOM during treatment are positional difficulties, inconvenience, and increased treatment intervention.

Conclusions

The variation in root or root canal morphology, especially in multirouted teeth is challenging for diagnosis and successful endodontic therapy. The knowledge of common anatomical characteristics and their possible variation is fundamental. Knowledge of unknown variation

like the case reported here is essential as non-treatment of one additional root or root canal can lead to failure of endodontic treatment. The presence of an additional palatal root is rare but still an unforeseen eventuality, and whenever an endodontist is confronted with unusual difficulties and the patient complains of persistent post medication pain, the possibility of an extra canal or root has to be borne in mind. X-rays and magnification devices are an important tool in diagnosing and treating such complicated cases.

References

1. Vertucci FJ. Root canal morphology and its relationship to endodontic procedures. *Endod Topics* 2005;10:3-29.
2. Gopikrishna V, Bhargavi N, Kandaswamy D. Endodontic management of a maxillary first molar with a single root canal and a single canal diagnosed with a aid of spiral CT: a case report. *J Endod* 2006;32:687-91.
3. Christie WH, Pekoff MD, Fogel HM. Maxillary molar with two palatal root a retrospective clinical study. *J Endod* 1991; 17:80-4.
4. Barbizam JV, Ribeiro RG, Tanomara Filho M. Unusual anatomy of permanent maxillary molars. *J Endod* 2004;30:668-71.
5. Malagnino V, Gallotini L, Passariello P. Some unusual clinical cases on root anatomy of permanent maxillary molar. *J Endod* 1997;23:127-8.
6. Ferguson DB, Kjar KS, Hartwell GR. Three canals in the mesiobuccal root of a maxillary first molar: a case report. *J Endod* 2005;31:400-2.
7. de Almeida-Gomes F, Maniglia-Ferreira C, Carvalho de Sousa B, Alves dos Santos R. Six root canals in maxillary first molars. *Oral Surg Oral Med Oral Pathol Oral Radiol Endod* 2009;108:e157-9.
8. Dankner E, Friedman S, Stabholz A. Bilateral C shape configuration in maxillary first molars. *J Endod* 1990;16:601-3.
9. Stone HL, Stroner FW. Maxillary molars demonstrating more than one palatal root canal. *Oral Surg* 1981;51:649-52.
10. Slowey RR. Radiographic aids in the detection of extra root canal. *Oral Med Oral Path Oral Radiol Endod* 1974;37:762-72.
11. Libfield H, Rostein I. Incidence of four-rooted maxillary second molar: literature review and radiographic survey of 1,200 teeth. *J Endod* 1989;15:129-31.
12. Curzon ME. Miscegenation and the prevalence of three-rooted mandibular first molars in the Baffin Eskimo. *Community Dent Oral Epidemiol* 1974;2:130-1.
13. Carlsen O, Alexanderson V. Radix entomolaris: identification and morphology. *Scand J Dent Res* 1990;98:363-73.
14. Carlsen O, Alexanderson V. Radix paramolaris identification and morphology in permanent mandibular molar: identification and morphology. *Scand J Dent Res* 1991; 99:189-95.
15. Shanelec DA. Optical principles of loupes. *J Calif Dent Assoc* 1992;20:25-32.
16. Rathi S, Patil J, Jaju PP. Detection of mesiobuccal canal in maxillary molars and distolingual canal in mandibular molars by dental CT: a retrospective study of 100 cases. *Int J Dent* 2010;29:1276.
17. Yoshioka T, Kobayashi C, Suda H. Detection rate of root canal orifices with a microscope. *J Endod* 2002;28:452-3.
18. Saunders WP, Saunders EM. Conventional endodontics and the operating microscope. *Dent Clin North Am* 1997;41:415-28.