

# A glimpse into the early origins of medieval anatomy through the oldest conserved human dissection (Western Europe, 13<sup>th</sup> c. A.D.)

Philippe Charlier<sup>1</sup>, Isabelle Huynh-Charlier<sup>2</sup>, Joël Poupon<sup>3</sup>, Eloïse Lancelot<sup>4</sup>, Paula F. Campos<sup>5</sup>, Dominique Favier<sup>6</sup>, Gaël-François Jeannel<sup>6</sup>, Maurizio Rippa Bonati<sup>7</sup>, Geoffroy Lorin de la Grandmaison<sup>1</sup>, Christian Hervé<sup>8</sup>

<sup>1</sup>Department of Forensic Medicine and Pathology, University Hospital R. Poincaré, Paris, France

<sup>2</sup>Department of Radiology, University Hospital Pitié-Salpêtrière (AP-HP), Paris, France

<sup>3</sup>Department of Biological Toxicology, University Hospital Lariboisière (AP-HP), Paris, France

<sup>4</sup>Horiba, Villeneuve d'Ascq, France

<sup>5</sup>Niels Bøhr Institute, Copenhagen, Denmark

<sup>6</sup>International Flavors and Fragrances, Neuilly sur Seine, France

<sup>7</sup>Dipartimento di Storia della Scienza, Università di Padova, Padova, Italy

<sup>8</sup>Laboratory of Medical Ethics and Forensic Medicine, University of Paris 5, Paris, France

## Corresponding author:

Philippe Charlier MD, PhD

Department of Forensic  
Medicine and Pathology  
University Hospital R. Poincaré

104 R. Poincaré Boulevard

92380 Garches, France

Phone: 33 1 47 10 76 80/89

Fax: 33 1 47 10 76 83

E-mail: ph\_charlier@yahoo.fr

**Submitted:** 19 October 2012

**Accepted:** 18 January 2013

Arch Med Sci 2014; 10, 2: 366–373

DOI: 10.5114/aoms.2013.33331

Copyright © 2014 Termedia & Banach

## Abstract

**Introduction:** Medieval autopsy practice is very poorly known in Western Europe, due to a lack of both descriptive medico-surgical texts and conserved dissected human remains. This period is currently considered the dark ages according to a common belief of systematic opposition of Christian religious authorities to the opening of human cadavers.

**Material and methods:** The identification in a private collection of an autopsied human individual dated from the 13<sup>th</sup> century A.D. is an opportunity for better knowledge of such practice in this chrono-cultural context, i.e. the early origins of occidental dissections. A complete forensic anthropological procedure was carried out, completed by radiological and elemental analyses.

**Results:** The complete procedure of this body opening and internal organs exploration is explained, and compared with historical data about forensic and anatomical autopsies from this period. During the analysis, a red substance filling all arterial cavities, made of mercury sulfide (cinnabar) mixed with vegetal oil (oleic and palmitic acids) was identified; it was presumably used to highlight vascularization by coloring in red such vessels, and help in the preservation of the body.

**Conclusions:** Of particular interest for the description of early medical and anatomical knowledge, this “human preparation” is the oldest known yet, and is particularly important for the fields of history of medicine, surgery and anatomical practice.

**Key words:** forensic anthropology, medical anatomy, status of body, death, cadaver, medical ethics, paleopathology, history of medicine.

## Introduction

Little is known about medieval anatomical preparations, as only theoretical treatises signed by surgeons and physicians have survived. In 2003,

a mummified human torso was sold by a medical antiquities art dealer from Paris, and is now conserved in a Canadian private collection; its recent multidisciplinary analysis was the occasion of a whole description of such an anatomical preparation, and to improve our knowledge about early occidental autopsy/dissection techniques and body preservation.

## Material and methods

### Dissecting microscope

A preliminary macroscopic examination was completed with binocular lenses (Leica® WILD M3Z).

### Radiological examination

Multidetector row computed tomography (Philips®, iCT 256) without any iodinated contrast material was carried out, using the following parameters: detector configuration: 64 mm × 0.625 mm; slice thickness: 0.80 mm; tube voltage: 120 kV; dose per section: 601 mAs; and a final DLP of 2,303 mGy · cm.

### Fiberscope

An endoscopic examination was made with a flexible fiberscope Olympus® (GIF-XQ-10) introduced within the mouth (anterograde examination) and the trachea (retrograde examination).

### Elemental analyses

Elemental analyses consisted of plasma mass spectrometry (ICP-MS) on a DRCE spectrometer (Perkin Elmer®, Les Ulis, France), followed by Raman spectroscopy (Labram Aramis, Horiba Jobin Yvon®, Villeneuve d'Asq, France).

### Molecular analyses

First, the surface of the sample was cleaned mechanically in order to prevent potential artifacts due to any extra materials. A first sample was prepared by transesterification reaction by the use of BF<sub>3</sub>/MeOH (70°C, 16 h), after liquid-liquid extraction; the organic phase was evaporated to dryness, then silylated by N,O-bis (trimethylsilyl) acetamide (70°C, 1 h), after evaporation of the residual derivatizing agent. The sample was put in cyclohexane and analyzed by gas chromatography/mass spectrometry (GC/MS). This protocol, adapted from the literature [1, 2], is adequate for the selective detection of lipids, wax or resin components, but inadequate concerning any polysaccharides or proteins. A second sample was directly placed in a glass liner into the injector of the chromatograph, and organic components were directly desorbed at 300°C for 5 min.

The GC/MS Agilent 6890 fitted with the Mass Spectrometer 5973 was mounted with an adapted purge and trap technique, and with Gerstel CombiPal with the CIS4 injector.

### Genetic analyses

Extractions were performed at the University of Copenhagen in a dedicated ancient DNA laboratory using the Qiagen DNEasy extraction kit (Qiagen®, Valencia, CA). The complete hypervariable region I (HVRI) was amplified and sequenced using a combination of five different primer pairs [3]. The sample was sexed using a 106/112 bp fragment (Y chromosome and X chromosome, respectively) of the single copy nuclear gene amelogenin [4].

Polymerase chain reaction (PCR) amplifications were performed in 25 µl volumes, using 1× PCR buffer, 2 mM of MgSO<sub>4</sub>, 0.4 mg/ml bovine serum albumin (BSA), 200 nM of each primer, 200 nM of dNTPs, 0.5 U of High Fidelity Platinum Taq (Invitrogen, Carlsbad, CA) and 2 µl of template DNA. Cycling conditions were: 94°C for 2 min; 50 cycles of 94°C for 30 s, 54/56°C for 30 s and 68°C for 30 s followed by 72°C for 7 min. The PCR products were diluted 1 : 10 and subsequently cloned using the TOPO TA cloning kit for sequencing (Invitrogen®, Carlsbad, CA). A minimum of 8 clones were sequenced for each fragment by the commercial MacroGen facility (MacroGen®, Seoul, South Korea). DNA sequences were edited and aligned using Sequencer 4.7 (Gene Codes Corporation®, Ann Arbor, MI). Results for the sexing assay were visualized in a 2% agarose gel.

### Radiocarbon dating <sup>14</sup>C

Radiocarbon dating by accelerator mass spectrometry (AMS) was carried out by Beta Analytic Radiocarbon Dating Laboratory (Miami, USA), on muscle samples taken from the inner part of the torso during fiberscope examination, free of any gross contamination (confirmed by macroscopic and dissecting microscope examination).

## Results

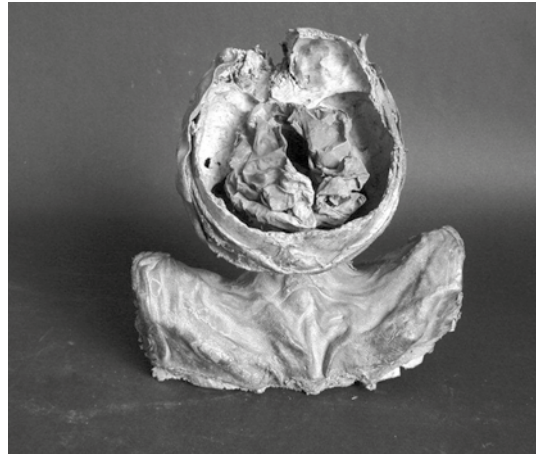
### Anthropological and pathological data

This piece measures 44 by 48 cm and has a brown diffuse coloration (Figures 1 and 2). Traces of rodents' partial eating are visible at the level of the right ear (which has almost entirely disappeared, with partial destruction of the periphery of the external meatus). Alterations due to a past pululation of xylophagous insects are present at the level of the inferior part of the chin, while some pupae are still present in the mouth).

Clear traces of sawing (grossly horizontal in an anatomical plan) are visible at the level of both scapulas' bodies, sternal manubrium, body of the



**Figure 1.** Anterior view of the human anatomical preparation (with permission from Bill Jamieson)



**Figure 2.** Superior and posterior view of the human anatomical preparation (with permission from Bill Jamieson)

5<sup>th</sup> thoracic vertebra (and part of the posterior spine of the 4<sup>th</sup> thoracic vertebra), and 2<sup>nd</sup> to 5<sup>th</sup> left and right ribs. Residues of pleura are still present in both thoracic cavities. The mediastinum is still occupied by various visceral structures (esophagus, trachea, bronchopulmonary arterial trunk, primitive right carotid, right sub-clavicular artery and superior vena cava). The lumen of all precedent arteries, like those of inter-costal and subcutaneous ones, have been filled with a red artificial material (Figure 3). The spinal cord is still present in the medullar canal, but retracted in its dura mater sheath for almost 2 cm.

The anthropological analysis of these remains showed that it was a male individual (many short

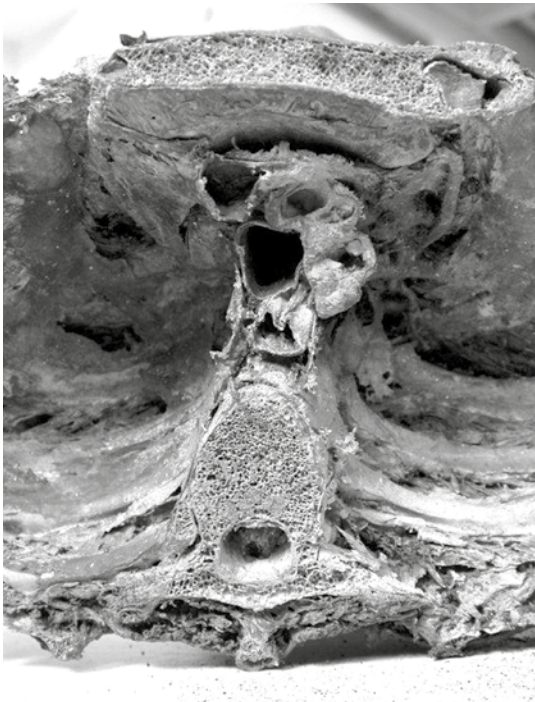
red hairs being still visible at the level of the moustache, beard, and temporo-occipital regions), who died at an adult mature age (over 45 years old). The morphological characters of the skull, into the limits of its partial conservation, were Caucasian [5]. Lesions of mild osteoarthritis were present at the level of the temporomandibular joint [6], associated with severe dental wear and strong *ante-mortem* tooth loss. Only the following teeth were present at death: 31 to 34, and 41 to 44. All the 7 cervical vertebrae were conserved (all with moderate anterior and marginal osteophytes); mild osteoarthritic lesions were also visible on both clavicles (medial and distal extremities), but not on both scapular cavities [7].

#### *Post-mortem* modifications

The skull has been opened after scalping and positioning of skin fragments below both ears. The whole brain has then been removed after a section at the summit of the spinal cord (base of the first cervical vertebra), leaving only the dura mater and the Willis polygon arteries filled with the “metal wax”. The microscopic examination of the craniotomy surface showed that a preliminary section by saw was followed by moderate crushing of the bone section, probably at the moment of the final separation.

A complete skin section has been made just behind the left auricle (maybe in order to limit the retraction tension of all the skull skin during the drying process?); it is impossible to know if a comparable section existed on the opposite side, due to strong alterations by rodents.

An anatomical exploration has been carried out within the left nasal cavity and left retro-orbital region, with complete exposure of vascular, muscular and neurological structures. On the right side of the neck, an exploration of the thyroid gland and



**Figure 3.** Close view of the inferior section surface showing the red filling of supra-aortic arteries

cartilage has been performed, revealing also the first three calcified tracheal rings.

The olfaction of this anatomical piece by two professional perfume “noses” showed a very intense wood smoke odor that may be at the origin of its long-term conservation (i.e. smoking); the kind of wood could not be precisely identified.

### Vascular filling

Both preliminary radiological examination and computed tomography (CT) scan showed the presence of a complete radio-opaque artificial arterial filling (“metal wax”) originating in the supra-aortic vessels and extending to the distal small-caliber arteries, such as subcutaneous ones (Figures 4

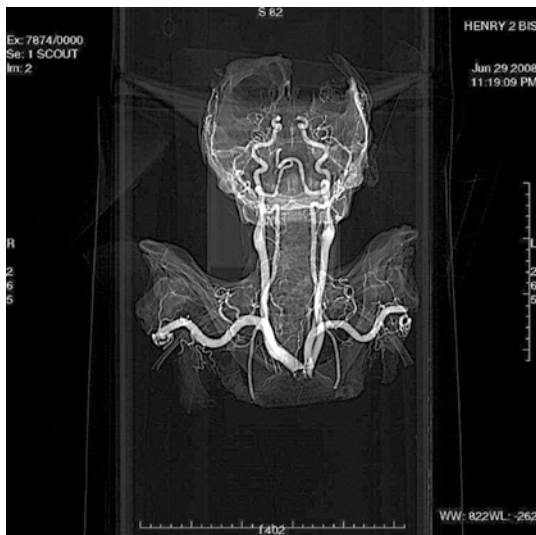


Figure 4. Radiological aspect of the dense filling of supra-aortic arteries

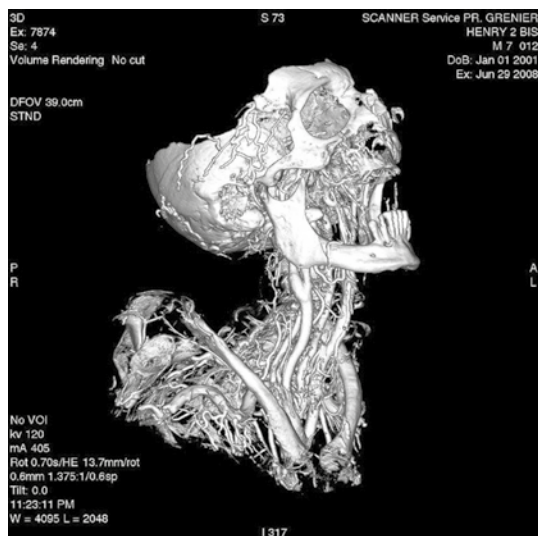


Figure 5. CT scan aspect of the human anatomical preparation (bone density) showing the skeleton, dentition and artery filling

and 5). This filling was evidently *post-mortem*, due to the anatomical site of injection (just over the cardiac-aortic junction), and carried out on a fresh cadaver (distal arteries should not have been filled if carried out after a long *post-mortem* interval).

The results of the elemental analysis of this arterial filling showed the presence of calcium (167 mg/g), mercury (1.3 mg/g), magnesium (0.7 mg/g), strontium (0.5 mg/g), iron (0.37 mg/g), lead (0.17 mg/g), and manganese (0.1 mg/g). Sulfur was also detected in large amounts but was not quantified.

Raman spectroscopy of this substance indicated a heterogeneous composition with, at least, three different colored zones: white, red and dark. Raman spectra indicate that these zones correspond respectively to gypsum (a natural form of calcium sulfate), cinnabar (mercury sulfur) and to a form of amorphous carbon called “natural brown 8” (Figure 6). This latter (also called “Cassel earth” or “Cologne earth”) is a natural substance derived from soil and containing iron oxide, manganese oxide and humic acids, specifically extracted from Cassel and Cologne (Germany).

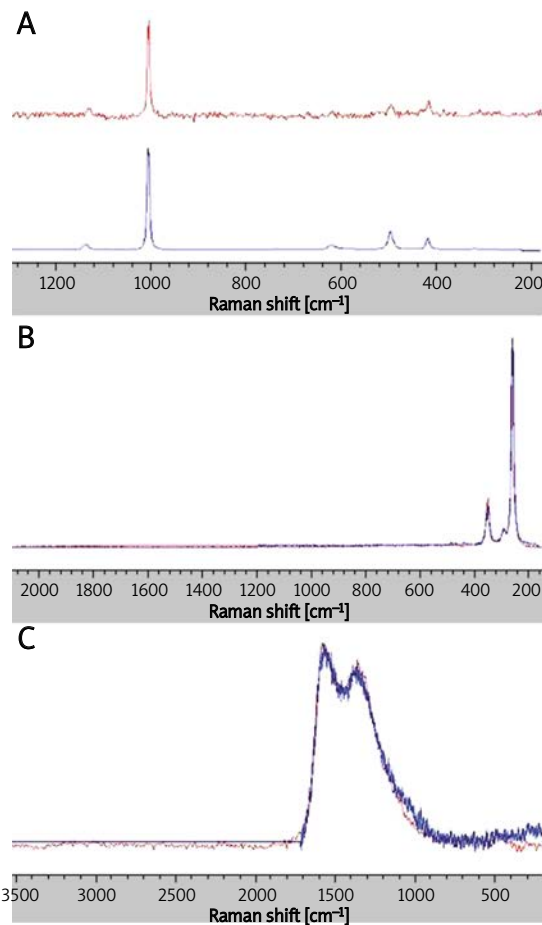
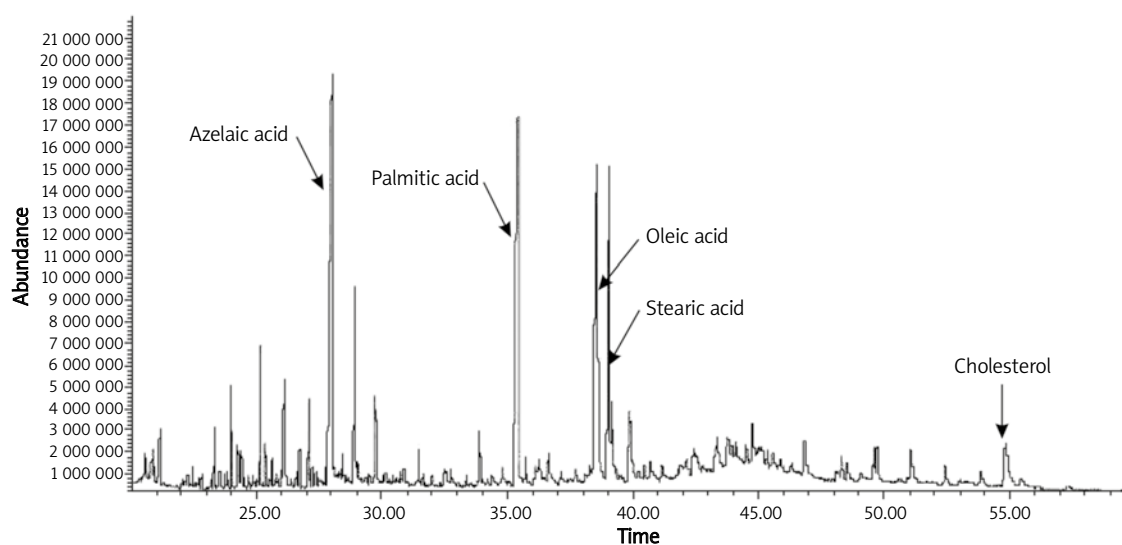


Figure 6. Raman spectra (red lines) of white (A), red (B) and dark (C) zones of the red substance. Blue lines correspond to reference spectra (A: gypsum, B: cinnabar and C: amorphous carbon, “natural brown 8”)



**Figure 7.** Chromatogram of the binding media of the cinnabar sample with highlighting of the main molecular markers. Fatty acids are methylated and cholesterol is silylated

Molecular analyses showed the presence of fatty acids, mainly palmitic acid, stearic acid, and oleic acid (Figure 7). Linoleic acid was also present, but in a small quantity. Diacids with a smaller carbon chain length of between 7 and 10 were present, and among them azelaic was predominant. Such diacids are produced by the oxidation process of the unsaturated fatty acids, and indicate the ageing of the matter. These compounds tend to indicate the presence of a siccativ vegetable oil without any possibility of determining what exact kind was used. Cholesterol, a molecular marker of lipids from animal origin, was also present. We can make the hypothesis that egg yolk has been used in combination with the siccativ oil; in such a case egg yolk may have had the role of a plasticizer.

Results from the thermo desorption analysis confirmed the presence of mercury, which was well identified by mass spectrometry with its characteristic isotopic ratio. Cholesterol and fatty acids were still detected with predominantly palmitic, stearic, and oleic acids.

### Genetic data

We were able to amplify and sequence the complete HVRI (374 bp). The sequence recovered from the pleura differed by a single nucleotide polymorphism at nucleotide position 16193 (C-T) when compared to the Cambridge Reference Sequence. Although this fragment was not long enough to definitively assign a mitochondrial haplogroup to the specimen, it was consistent with a sample of European origin. The sexing essay confirmed that the individual was a male in accordance with the morphological observations.

### Radiocarbon dating

Radiocarbon dating indicated conventional radiocarbon age of  $780 \pm 40$  years BP, 2 sigma calibrated result (95% probability) calibrated to 1200 to 1280 AD (Cal BP 750 to 670).

### Discussion

#### Historical context

Fragments of dissected human bodies dating from before the 19<sup>th</sup> c. are rare, and have mainly been found in archaeological contexts, for example in Venice (Italy), Marseille (south of France), Sens (Burgundy, France) or Douai (north of France), dating from the 17<sup>th</sup> or 18<sup>th</sup> c.; bone remains were closely connected to medical faculties or hospitals [8–10]. Older testimonies of anatomical opening of human cadavers are only known from the literature, especially medical or surgery treatises, and tradition; apart from this 13<sup>th</sup> c. case, no bone or mummified remain has been identified or preserved from this period.

In order to better understand the techniques used for both the opening and conservation of this human dissection, let us first provide a brief history of human body opening. If pharaonic Egyptian mummification has been frequently cited as an example of fine and precise anatomical knowledge, it has to be said that such body openings were performed by non-medico-surgical individuals with only practical knowledge, and without any physiological or pathological view. The first known human scientific dissections were carried out in Alexandria (Egypt) by Greek physicians in the early part of the 3<sup>rd</sup> century B.C., for example Herophilus of Chal-

cedon and Erasistratus of Chios [11, 12]. Before them, and outside of this geographical area, anatomical observations were limited to animal opening (sometimes vivisection) and opportunist examination of externalized bodies or degraded cadavers (for example at a war site or after a grave profanation). In Rome, an external examination of the body was sometimes asked for legal purposes (for example by the Greek physician Antisthenes on the cadaver of Julius Caesar after his murder), but real opening of the corpse was not carried out at that time [13]. All anatomical observations by Galen were made on the altered bodies of gladiators (sometimes with a serious traumatic opening leading to significant organ exteriorization) or directly on animals (especially pigs and monkeys) [14].

Historical continuity of Alexandrian anatomical practice and knowledge was maintained by Arabian physicians, especially Ibn Zuhr (1091–1161, better known as Avenzoar, living in al-Andalus), Ibn Jumay (12<sup>th</sup> century A.D., the personal physician of the sultan Saladin), Abd-el-Latif (living in Egypt circa 1200) and Ibn al-Nafis (attested in Syria in 1242). Some of their treatises were conserved, attesting to their dissection practice and giving results of their observations, but, unfortunately, no autopsy technique was described [15].

As demonstrated by recent research challenging a classical idea [16], Christian Europe was never systematically opposed to any human body dissection. Such regular anatomical openings are known from the 13<sup>th</sup> century, particularly in south Italy [17], regulated by the authorities (including the Church). As a theological and political authority, Pope Innocent III (1198–1216) organized systematic *post-mortem* verification (i.e. an equivalent of “forensic autopsy”) when the death was considered as suspicious [18]. Later, the edict *Ecclesia abhorret a sanguine* by the Council of Tours (1163) and the bulla *Detestandae feritatis* (1299) by Pope Boniface VIII were respectively directed against bloody trial procedures and embalming processes causing body segmentation (three different tombs for the cadaver, the heart, and the viscera), both without any direct contestation of scientific/medical/anatomical dissections [19, 20]. Indeed, a practice of dismemberment of slain crusaders' bodies followed by boiling of the segments to enable defleshing for return of their bones was current at this period; it was called *More teutano* due to the importance of such practices in the order of the Teutonic knights [21, 22].

Human dissection then made its first Western appearance in the last decades of the 13<sup>th</sup> century, in northern and central Italy, “where it was quickly accepted and institutionalized as a technique for understanding the nature and structure of human bodies. By 1300, it was being used in a variety of contexts, including not only public health and crim-

inal justice, but also medical research and teaching” [18].

### Place of this case within the historical background

Even if precisely dated between 1200 and 1280, it is impossible to determine precisely which practitioner was at the origin of this anatomical preparation; but some prestigious names of Italian or Spanish anatomists, physicians, and surgeons may correspond: Guillaume of Salicet (active in Bologna and Salerno around 1275)? Hugues of Lucques (active in Lucca)? Theodorice (active in Catalonia in 1264), Brunus (active in Padova in 1252)? In 1286 the first unambiguous record of an autopsy in Italy (Cremona) is attested, when the chronicler Salimbene described the actions of a physician inquiring the origin of an epidemic [23].

The vascular radio-opaque filling that we can see today thanks to radiography was visible during that epoch only in subcutaneous arteries, and when observing internal cavities and anatomical sections of the preparation. However, it could have also had another practical purpose, that is, firstly, a preservative one. This specimen could represent a kind of anatomy that would be defined as “preservative”, a hypothesis reinforced by the preservative properties of cinnabar comparable to that described much later by the 19<sup>th</sup> c. Italian physician Giuseppe Tranchina, in his *Ragguaglio su la esposizione de' cadaveri col nuovo suo metodo imbalsamati (...) preceduto da un cenno storico su i diversi metodi d'imbalsamare presso gli antichi ed i moderni* (Naples 1835). Indeed, he obtained mummified specimens thanks to the injection of some substances including an alcoholic or aqueous solution of arsenic and cinnabar. Also the symbolic significance of cinnabar should not be forgotten. According to 13<sup>th</sup> c. alchemy, cinnabar (mercury sulfur) is to be considered as a drug of long life as its intense red color is assimilated to the blood and then to the soul [24, 25]. Moreover, it was one of the main constituents, in conjunction with gold, used by the Arabic and occidental alchemists in their search for the “elixir of eternal life”.

In practice, how was cinnabar introduced within the vascular cavities of this human cadaver? The use of syringes in the 13<sup>th</sup> c. has to be taken into account. Concrete proof may be found that in the 15<sup>th</sup> c., syringes had been in use for a long time: a syringe is recognizable on an illustration of *Das Buch 'Der Chirurgia' di Hieronymus Brunschwig* published in 1497; Marco Gatinaro described its use in his *De Curis Egri-tudinum Particularium Noni Almansoris Practica Uber-ima* posthumously published in 1504. This precisely <sup>14</sup>C dated human preparation may be an indirect proof of the use of syringes – or, at least, vascular injection material – during the 13<sup>th</sup> c.

Lastly, who was this man? His cause of death remains unknown, as does his identity (a prisoner? A patient who died in a sanitary institution? An abandoned cadaver?). The exact origin of the anatomical piece still remains a mystery: a private collection (as part of a *Cabinet de curiosité*, for example), hospital or university one? Further historical research is necessary to answer this question.

### **An anatomical piece contemporaneous with the early origins of Western European anatomy**

The late 13<sup>th</sup> century and the early 14<sup>th</sup> century were very rich for anatomical research and publications, with important books on surgery and organ descriptions, for example by the French surgeons Henri of Mondeville (1306–1320) and Guy of Chauliac (1298–1368). At the same time, some European countries legalized the dissection of executed criminals for educational (and leisure) purposes. Around 1315–1316, in the city of Bologna (northern Italy), Mondino of Liuzzi performed the first public dissection on two females, and enhanced in this university the study and teaching of anatomy, based on post-mortem examinations and openings [26].

“Holy autopsies” are also known from the early 14<sup>th</sup> c., performed under ecclesiastic authorities; they consist in “the practice of inspecting the internal organs of a holy person shortly after death for corporeal signs of sanctity” that might be invoked as evidence for further beatification or canonization [16]. In 1308, Chiara of Montefalco (Umbria), a Franciscan abbess, was opened by the nuns from her community (without the presence of any physician); they found a small crucifix and instrument of the Passion in her heart (she indeed claimed “to have Jesus in her heart”), and three gallbladder stones (considered as a remembrance of the Holy Trinity). In 1320, there was carried out in a church the public autopsy of Blessed Margarita from the city of Castello (Italy), a virgin in whom three stones inscribed with images of the Holy Family were found in her heart (the autopsy being performed by two surgeons and three physicians, in front of many ecclesiastics). The goal of such openings is first to see, then to restore the body, in complete opposition to the 13<sup>th</sup> c. human torso, which was opened, partially destroyed and never restored.

What about elsewhere in Europe? According to Park, “with the exception of the University of Montpellier in southern France, there are few known references to autopsies and only one to a dissection in Germany, England or France before the late 15<sup>th</sup> century, including the relatively important medical faculty at Paris” [23]. Indeed, the first dissection known in northern Europe (Vienna, Austria, in 1404) seems to have been an isolated case, per-

formed by an imported Italian lecturer on medicine. The first cases of autopsies carried out in the University of Paris date from 1477, with regular public anatomies from 1481 only. In late medieval times, anatomy was above all a “concrete” science finalized to forensic and preservative scopes (both religious and profane), and it was functional to surgery.

In conclusion, exceptional due to its global conservation, this 13<sup>th</sup> c. anatomical specimen dates from the earliest times of Western European medieval dissections. Fully analyzed by a both historical and scientific multidisciplinary team, it sheds light on much information related to medical education in the Middle Ages: methodology of upper body and head opening, type of conservation, exploration of anatomical cavities (including vascular ones), use of complementary material (syringe), etc. Further historical studies may help in the identification of the original practitioner of this dissection and preparation.

### **Acknowledgments**

All authors would like to thank the owners of this anatomical preparation for their authorization of the study and publication (the late Billy Jamieson, and Michel Grandsard), the two anonymous reviewers and the editor of the journal for their constructive comments.

### **References**

1. Regert M, Colinart S. Chemical alteration and use of beeswax through time: accelerated ageing tests and analysis of archaeological samples from various environmental contexts. *Archaeometry* 2001; 43: 549-69.
2. Regert M, Langlois J, Colinart S. Characterization of wax works of art by gas chromatographic procedures. *J Chromato A* 2005; 1091: 124-36.
3. Malmström H, Gilbert MTP, Thomas MG. Ancient DNA reveals lack of continuity between neolithic hunter-gatherers and contemporary Scandinavians. *Curr Biol* 2009; 19: 1758-62.
4. Gilbert MTP, Haselkorn T, Bunce M. The isolation of nucleic acids from fixed, paraffin-embedded tissues. Which methods are useful, when? *PLoS ONE* 2007; 2: e537.
5. Konigsberg LW, Algee-Hewitt BF, Steadman DW. Estimation and evidence in forensic anthropology: sex and race. *Am J Phys Anthropol* 2009; 139: 68-76.
6. Manfredini D, Segù M, Bertacci A, Binotti G, Bosco M. Diagnosis of temporomandibular disorders according to RDC/TMD axis I findings, a multicenter Italian study. *Minerva Stomatol* 2004; 53: 429-38.
7. Schmitt A, Wapler U, Couallier V, Cunha E. Are bone losers distinguishable from bone formers in a skeletal series? Implications for adult age at death assessment methods. *Homo* 2007; 58: 53-66.
8. Rothenberg K. The autopsy through history. In: *Forensic science*. Embar-Seddon A, Pass AD (eds.). Salem Press, Pasadena 2008; 100-4.
9. Grilletto R, Cardesi E, Boano R, Fulcheri E. Il vaso di Pandora. *Paleopatologia: un percorso tra scienza, storia e leggenda*. Ananke, Torino 2004.

10. Signoli M, Léonetti G, Champsaur P, Brunet C, Dutour O. Demonstration of a cranial autopsy performed during the Great Plague of Marseille (1720-1722). *C R Acad Sci III* 1997; 320: 575-80.
11. Von Staden H. Herophilus, the art of medicine in early Alexandria. Cambridge University Press, Cambridge 1989.
12. Von Staden H. The discovery of the body: human dissection and its cultural contexts in ancient Greece. *Yale J Biol Med* 1992; 65: 223-41.
13. Charlier P. Morts violentes dans l'Antiquité. Fayard, Paris 2010.
14. Nutton V. The unknown Galen. Institute of Classical Studies, London 2002.
15. Loukas M, Lam R, Tubbs RS, Shoja MM, Apaydin A. Ibn al-Nafis: the first description of the pulmonary circulation. *Am Surg* 2008; 74: 440-2.
16. Park K. Holy autopsies. Sainly bodies and medical expertise, 1300-1600. In: *The body in early modern Italy*. Hairston J, Stephens W (eds.). John Hopkins University Press, Baltimore 2010; 61-73.
17. Vaglianti F, Cattaneo C. A medieval contribution to the history of legal medicine: the first European necroscopic registry. *Int J Legal Med* 2010; 124: 669-70.
18. Hirt M, Kovac P. History of forensic medicine (second part). The autopsy in the Middle Age and the Renaissance. *Soud Lek* 2005; 50: 32-7.
19. Valentin F, d'Errico F. Skeletal evidence of operations on cadavers from Sens (Yonne, France) at the end of the XV<sup>th</sup> century. *Am J Phys Anthropol* 1995; 98: 375-90.
20. Pioreschi P. Determinants of the revival of dissection of the human body in the Middle Ages. *Med Hypotheses* 2001; 56: 229-34.
21. Aufderheide A. *The scientific study of mummies*. Cambridge University Press, Cambridge 2003; 5-6.
22. Charlier P. Evolution of embalming methodology in Medieval and modern France (Agnès Sorel, the Duc de Berry, Louis the XI<sup>th</sup>, Charlotte de Savoie). *Med Secoli* 2006; 18: 777-97.
23. Park K. The life of the corpse: division and dissection in late medieval Europe. *J Hist Med Allied Sci* 1995; 50: 111-32.
24. Needham J. Theoretical influences of China on Arabic alchemy. *Revista da Universidade de Coimbra* 1980; 27: 1-28.
25. Mahdihassan S. History of cinnabar as drug, the natural substance and the synthetic product. *Indian J Hist Sci* 1987; 22: 63-70.
26. Park K. The criminal and the saintly body: autopsy and dissection in Renaissance Italy. *Renaissance Quarterly* 1994; 47: 1-33.