

# A Comparative Study to Evaluate the Functional Effect of Unilateral Uvuloplasty after Primary Palatoplasty

Percy Rossell-Perry, PhD,  
FACS\*†

Claudia Olivencia-Flores, MD‡

Arquímedes M. Gavino-  
Gutierrez, MD, MS(c)§¶

Evelyn Caceres-Nano, SLP||

Omar Cotrina-Rabanal,  
DDS\*†\*\*

**Background:** The conventional method for uvular repair suturing the 2 hemi-uvulas of the palatal cleft together in the midline does not allow us to obtain a proper anatomical repair. In our hands, the midline straight closure frequently causes retraction of the uvular tissues with the consequent abnormal appearance of the uvula. We described before a method for uvular repair in patients with cleft palate. The technique consists in preserving one of the hemi-uvulas, which is moved to the midline to form the definitive uvula. The purpose of this study was to evaluate the functional effects of the unilateral uvuloplasty for uvular repair in a group of patients with bilateral cleft palate.

**Methods:** This is a retrospective, single-blinded cohort study between 2 groups of 90 patients with bilateral cleft palate who were operated on using the conventional and unilateral uvuloplasty methods of uvular repair from 2000 to 2009. Data collection was accomplished by physical examination to evaluate the presence of postoperative fistulas and hypernasal speech determined at 6 months to 5 years after surgery. In addition, postoperative dimensions of the velopharynx were measured by a single-blind examiner using a computed tomography scan.

**Results:** Our comparative study found statistically significant differences between the 2 groups in favor of the unilateral uvuloplasty group.

**Conclusions:** We observed that the use of unilateral uvuloplasty for uvular reconstruction reduces the velopharyngeal space and the frequency of hypernasality in patients with bilateral cleft palate. (*Plast Reconstr Surg Glob Open* 2015;3:e415; doi: 10.1097/GOX.0000000000000393; Published online 11 June 2015.)

Cleft palate uvular repair and the impact on velopharyngeal function have not been evaluated. The conventional uvular repair method

From the \*San Martin de Porres University, Lima, Peru; †“Outreach Surgical Center Lima Peru,” ReSurge Int, Lima, Peru; ‡Plastic Surgery Service, Edgardo Rebagliatti Martins Hospital, Lima, Peru; §A.B. PRISMA, Lima, Peru; ¶Universidad Peruana Cayetano Heredia, Lima, Peru; ||School of Pedagogic Training, Lima, Peru; and \*\*ARMONIZAR Foundation, Lima, Peru.

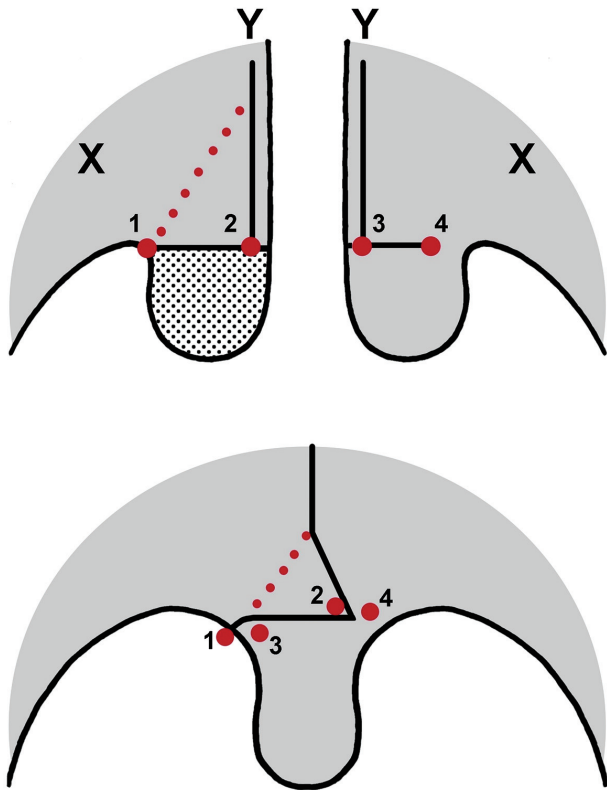
Received for publication January 18, 2015; accepted April 23, 2015.

Copyright © 2015 The Authors. Published by Wolters Kluwer Health, Inc. on behalf of The American Society of Plastic Surgeons. All rights reserved. This is an open-access article distributed under the terms of the Creative Commons Attribution-NonCommercial-NoDerivatives 3.0 License, where it is permissible to download and share the work provided it is properly cited. The work cannot be changed in any way or used commercially.

DOI: 10.1097/GOX.0000000000000393

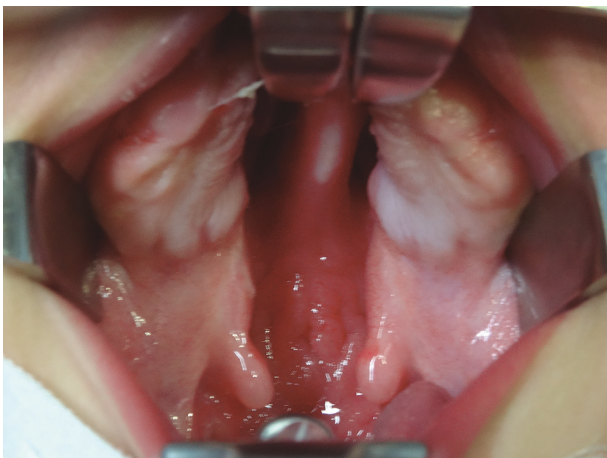involves suturing the 2 hemi-uvulas of the cleft palate and does not produce a proper anatomical repair. In our hands, this closure method frequently causes retraction of the uvular tissues along with abnormal appearance and function of the uvula. To address this issue, we developed unilateral uvuloplasty. Unilateral uvuloplasty is a new method for uvular repair that is based on the use of one hemi-uvula (Figs. 1–3).<sup>1</sup> A similar uvular repair method has been described by Navarro and Bardales.<sup>2</sup> The unilateral uvuloplasty technique involves preserving one of the hemi-uvulas and moving it to the midline to form the definitive uvula during cleft closure in patients with cleft palates. Huang et al,<sup>3</sup> Kuehn and

**Disclosure:** The authors have no financial interest to declare in relation to the content of this article. The Article Processing Charge was paid for by the authors.

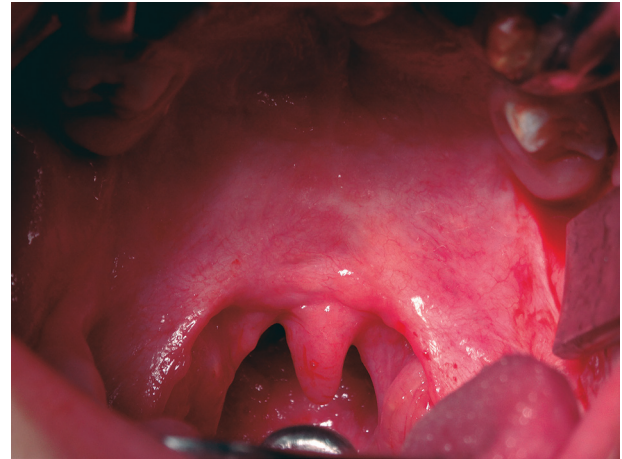

**Figure 1.** Surgical technique for uvula repair in patients with cleft palate using one hemi-uvula. Dotted line: Line of incision to remove a triangle from the edge of the nasal mucosa. Point 1: The lateral point at the base of the excised uvula. Point 2: The medial point at the base of the excised uvula. Point 3: The medial point at the base of the preserved uvula. Point 4: The lateral point at the base of the preserved uvula. Point X: Maxillary tuberosity. Point Y: Hard and soft palate junction.

Kahane,<sup>4</sup> and Kuehn et al<sup>5</sup> described the function of the uvula, and their findings suggest that the uvula increases the midline bulk and maximizes midline pharyngeal contact.



**Figure 2.** Preoperative view showing a 1-year-old patient with bilateral cleft palate.



**Figure 3.** Postoperative view of repaired cleft palate using the unilateral uvuloplasty for uvular repair.

Our previous clinical trial evaluated the relationship between unilateral uvuloplasty and velopharyngeal function, but was limited by a small sample size and low statistical power.<sup>1</sup> As a result, we decided to evaluate this relationship using a larger number of patients. The purpose of the current study was to compare functional outcomes between patients with bilateral cleft palates who underwent conventional uvuloplasty versus unilateral uvuloplasty. We hypothesized that the unilateral uvuloplasty procedure would be more effective than conventional uvuloplasty for the functional correction of the velopharyngeal sphincter.

### MATERIALS AND METHODS

This is a retrospective single-blinded cohort study using 2 groups of patients ( $n = 90/\text{group}$ ) with bilateral cleft palates who underwent either conventional uvular repair or unilateral uvuloplasty from 2000 to 2009. The author (P.R.-P.) operated on all of the patients who received a diagnosis of nonsyndromic bilateral cleft palate within 12–14 months of age. Patients were evaluated for cleft severity based on the palatal index as follows: mild ( $<0.2$ ), moderate ( $0.2\text{--}0.4$ ), and severe ( $>0.4$ ).<sup>6</sup> The palatal index is the proportion between the width of the cleft (ie, cleft severity) and the sum of both palatal segment widths (ie, tissue deficiency) measured at the junction of the hard and soft palates.

#### Study Groups

Group A patients (control) received conventional uvuloplasty in which the 2 hemi-uvulas of the cleft were sutured together at the midline (ie, a straight line closure). Group B patients received unilateral uvuloplasty in which the larger hemi-uvula of the cleft was preserved while the smaller hemi-uvula was

excised (Figs. 1–3). In both groups, the cleft palate was closed at 12–14 months of age with Bardach’s 2-flap palatoplasty<sup>7</sup> and Sommerlad’s intravelar veloplasty.<sup>8</sup>

**Surgical Technique**

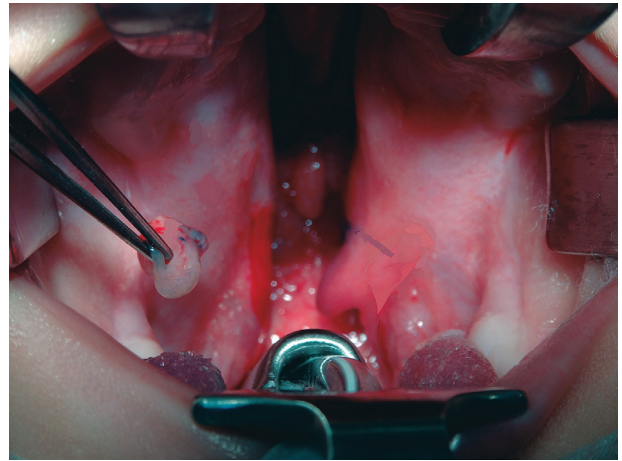
*Conventional Uvuloplasty*

For the conventional method, a full-thickness incision was made along the cleft margin of the soft palate, which goes up to the tip of the hemi-uvula on both sides. Then, 2 layers of the uvula were carefully repaired. We used 2–3 mattress sutures for better approximation of the cleft edges followed by the 2-flap technique for palatal closure and intravelar veloplasty for muscle repair (with end-to-end approximation of the muscles). The mucosa was carefully repaired with 5-0 absorbable sutures by bringing together the incisions for a border-to-border approximation.

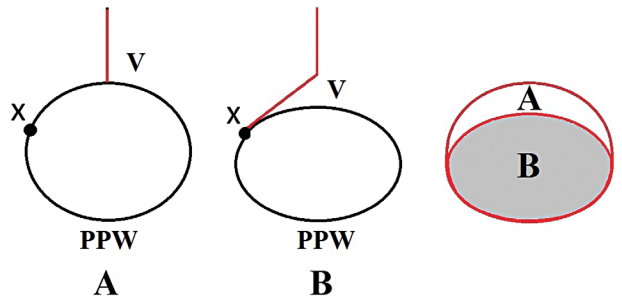
*Unilateral Uvuloplasty Procedure*

We preserved the larger hemi-uvula and excised the smaller hemi-uvula as shown in Figures 4 and 5. The incision for the excised hemi-uvula side was extended laterally to the junction between the soft palate and the top of the tonsillar pillars (point 1 in Fig. 1). This incision let us move the uvula to the central position and reduced the velopharyngeal space (Fig. 6). Then, a small triangle from the edge of the nasal mucosa was excised to avoid redundant tissue (Fig. 1, dotted line). A mucosal incision was made along the cleft margin of the soft palate and extended up to the base of the preserved hemi-uvula. Then, we turned the incision 90° for ~1 cm. The incision only included the oral mucosa. The uvularis muscle was preserved (Fig. 7). Blood was supplied to the preserved uvula by the vascular plexus of the nasal mucosa and the uvularis muscle. The

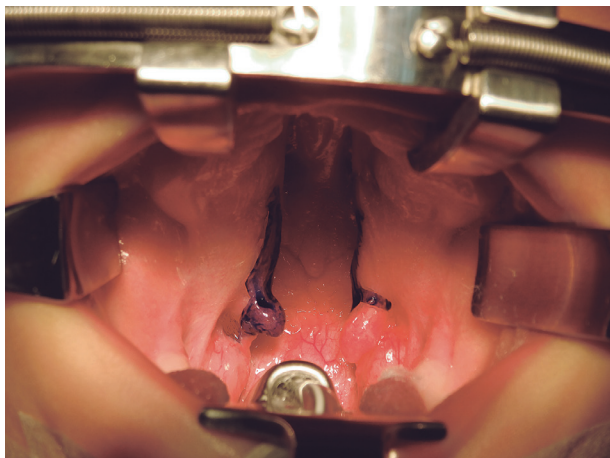
nasal and oral mucosa were carefully repaired with 5-0 absorbable sutures by bringing points 1 and 3 together and points 2 and 4 together using corner stitches for a border-to-border approximation



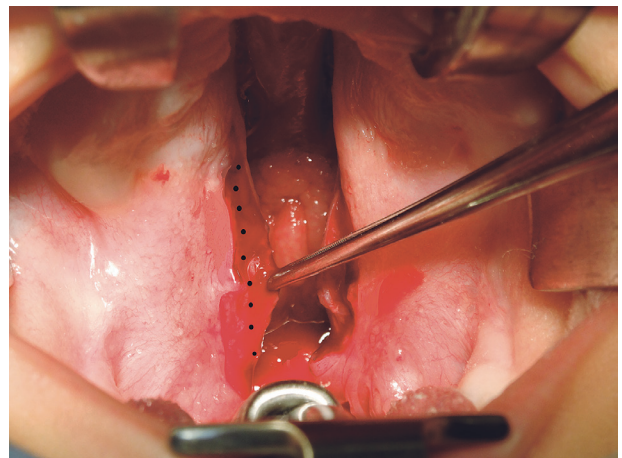
**Figure 5.** The biggest of the 2 hemi-uvulae is selected and preserved, whereas the smallest one is excised. The incision at the excised hemi-uvula side is extended laterally up to the junction between the soft palate and the top of the tonsillar pillars.



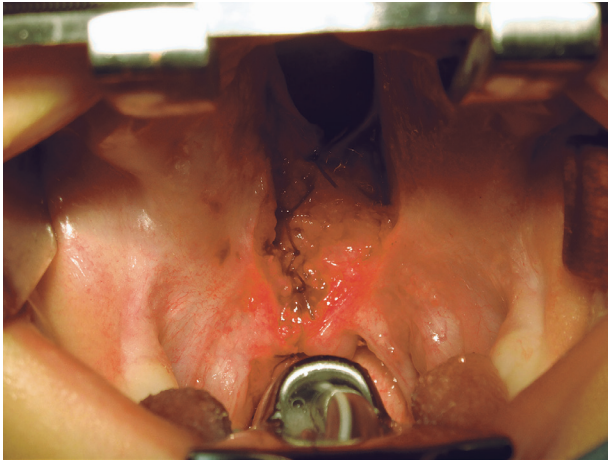
**Figure 6.** Diagram of the velopharyngeal space comparing 2 techniques of uvuloplasty. A, Conventional uvuloplasty. B, Unilateral uvuloplasty. PPW indicates posterior pharyngeal wall; V, velum; X, lateral point at the base of the excised uvula.



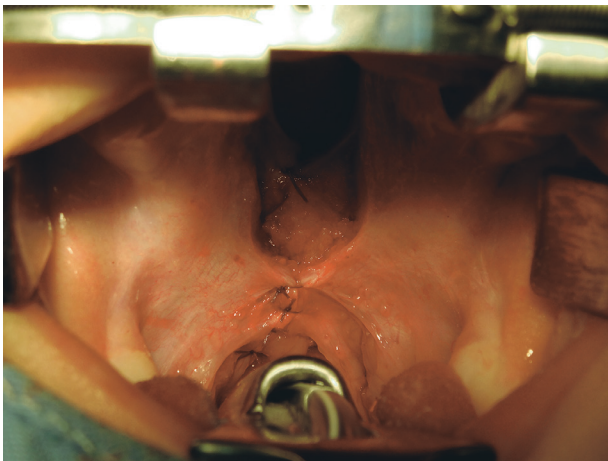
**Figure 4.** Proposed technique markings for correction of the uvula in a patient with bilateral cleft palate deformity.



**Figure 7.** A small triangle from the edge of the nasal mucosa is excised to avoid a redundancy of this tissue (dotted line).



**Figure 8.** Nasal mucosa is repaired carefully with absorbable 5-0 sutures.

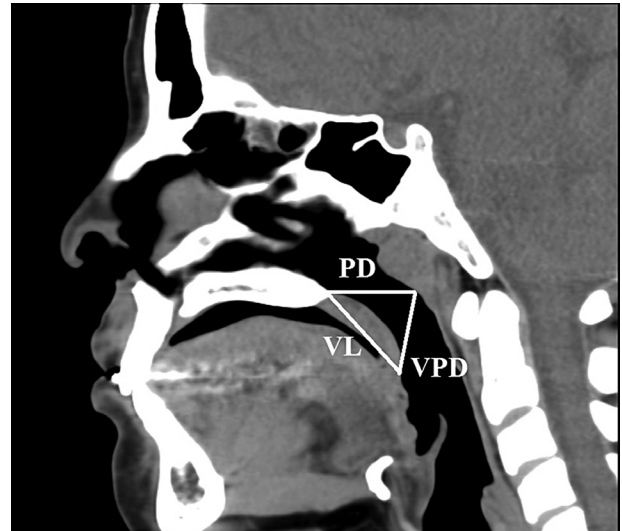


**Figure 9.** Oral mucosa is repaired with absorbable 5-0 sutures by bringing together points 1–3 and 2–4 using corner stitches, for a border-to-border approximation.

(Figs. 8 and 9). Finally, a unilimb Z-plasty was performed in which a triangle of mucosa from the excised uvula side was placed over the preserved uvula to provide additional length in the repaired palate (Figs. 1 and 9).

### Surgical Outcome Evaluation

Surgical outcomes were evaluated clinically and morphologically. A physician performed physical examinations to detect the presence or absence of fistulas to determine whether they have a role in the development of hypernasality. A palatal fistula was defined as the presence of a communication (symptomatic or not) between the nose and oral cavity in the hard or soft palate after primary palatoplasty. We excluded all anterior fistulas from our analyses because alveolar clefts are not primarily repaired under our protocol. A speech therapist evaluated velopharyngeal function (specifically the presence



**Figure 10.** Anatomical measurements of the velopharyngeal space using computed tomography. PD indicates pharyngeal depth; VL, velar length; VPD, velopharyngeal distance.

of moderate or severe postoperative hypernasality) using the parameters described by Henningsson et al.<sup>9</sup> and John et al.<sup>10</sup>

Velopharyngeal insufficiency was defined as the inability of the velopharyngeal sphincter to produce normal speech. For practical purposes, it was considered the nasal escape of air with increased resonance during speech (ie, hypernasality). Velopharyngeal function was evaluated both subjectively and objectively before 5 years of age.

A speech therapist performed perceptual voice analyses to characterize hypernasality. The perceptual speech ratings were determined during live speech samples, which included single words, sentences, and conversational speech. Hypernasality was rated on high vowels in single words and connected speech and was classified according to John et al.<sup>10</sup> The objective analysis calculated a blowing ratio by comparing soft blowing times between open-nose and closed-nose conditions.

Morphological evaluation of the velopharyngeal space was performed at rest using a computed tomography scan in a randomized sample of 40 patients from each group at 5 years of age. Using the syngo fastView software (Siemens AG Medical Solutions, Erlangen, Germany), velar length, pharyngeal depth, and velopharyngeal distance were measured by one person to eliminate interoperator errors (Fig. 10). Velar length was estimated from the tip of the posterior nasal spine to the tip of the uvula. Pharyngeal depth was estimated from the margin of the posterior pharyngeal wall at the junction of the palatal plane to the tip of the posterior nasal spine. Velopharyngeal distance was estimated from the margin

**Table 1. Characteristics of Subjects with Bilateral Cleft Palate Who Underwent Cleft Palate Surgery Stratified by Type of Uvuloplasty**

Characteristics	Group A	Group B	CL	P*
Gender, n (%)				
Male	64 (71.11)	68 (75.56)	-4444 (-17,349; 8459)	0.50
Female	26 (28.89)	22 (24.44)	4444 (-8459; 17,349)	
Total	90	90		
Cleft's severity, n (%)				
Mild	14 (15.55)	12 (12.33)	6667 (-18,354; 31,687)	0.77
Moderate	35 (38.89)	38 (42.22)	-2222 (-16,813; 12,368)	
Severe	41 (45.55)	40 (44.44)	2222 (-12,368; 16,813)	
Total	90	90		

Group A: Conventional uvuloplasty technique.

Group B: Unilateral uvuloplasty technique.

\*Chi-square test.

CL, 95%.

**Table 2. Postoperative Velopharyngeal Closure Function following 2 Types of Uvuloplasty**

	Group A	Group B	CL 95%	P*
Hypernasality, n (%)				
Moderate	10 (11.11)	4 (4.44)	5556 (-2479; 13,589)	0.24
Severe	7 (7.78)	3 (3.33)	4444 (-2217; 11,105)	
Total	17 (18.88)	7 (7.77)	-3333 (-10,881; 4214)	0.026
	Media (SD)	Media (SD)	CL 95%	P**
Blowing ratio	0.72 (0.139)	0.82 (0.088)	-0.030 (-0.065; 0.003)	0.008

Group A: Conventional uvuloplasty technique.

Group B: Unilateral uvuloplasty technique.

\*Chi-square test

\*\*Wilcoxon signed-rank test.

CL, 95%.

of the posterior pharyngeal wall at the junction of the palatal plane to the top of the nasal surface of the soft palate. Outcome assessment for each patient was performed by a blind evaluator.

### Statistical Analysis

We used the chi-square test to evaluate the statistical significance between the 2 surgical methods in relation to the characteristics of the patients and the number of cases with hypernasal speech. A Wilcoxon signed-rank test was used to assess the statistical significance of differences between the 2 groups in relation to the blowing ratio. We used the Student's *t* test to evaluate velopharyngeal space morphology between the 2 groups. An  $\alpha$  error of less than or equal to 0.05 was considered significant. All confidence intervals were described at 95%. Data were analyzed with the SPSS 15.0 software (SPSS Inc., Chicago Ill.).

## RESULTS

The characteristics of the patients are presented in Table 1. Statistically significant differences were not detected based on sex ( $P = 0.50$ ), cleft severity ( $P = 0.77$ ), or age at operation (12–14 months). We found statistically significant differences between the 2 uvuloplasty methods regarding hypernasal speech ( $P = 0.026$ ) and the blowing ratio ( $P = 0.008$ ) in favor

of group B (Table 2). We did not find differences between the 2 groups regarding the development of postoperative fistulas (8 cases in each group; a rate of 8.88%). All of the fistulas were located in the middle third of the palate. There were statistically significant differences between the 2 groups with regard to the velar length and velopharyngeal distance ( $P = 0.00001$ ) (Table 3 and Figs. 11 and 12).

## DISCUSSION

Unilateral uvuloplasty is a surgical technique that we have used since 2000 for uvular repair in patients with cleft palates.<sup>1</sup> A similar technique was initially described by Navarro and Bardales<sup>2</sup> to improve the cosmetic appearance of the uvula; however, the main limitation of their method is that the uvula is frequently lateralized. They did not describe any functional effects for their technique.

In this study, we have described a modification based on the concept proposed by Navarro and Bardales with the following improvements: (1) the preserved hemi-uvula is moved laterally up to the top of the anterior tonsillar pillar, allowing for a more central position of the uvula and reducing the velopharyngeal space (Fig. 6 and Table 3); (2) the preserved hemi-uvula is elongated using a triangular flap from the resected side (ie, oral mucosa unilimb Z-plasty);

**Table 3. Cephalometric Comparison of Postoperative Changes in Studied Groups**

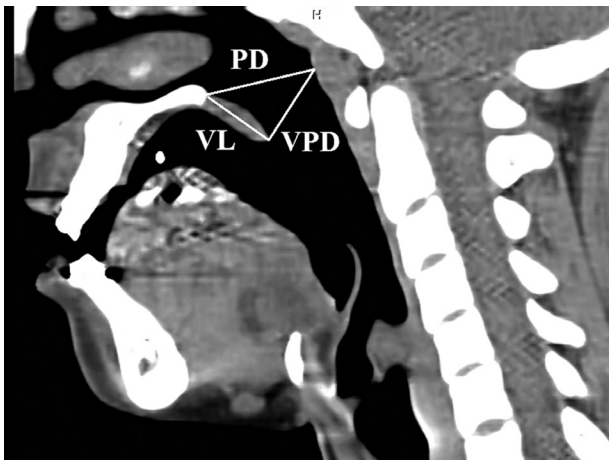
	Group A (n = 40)		Group B (n = 40)		CL 95%	P*
	Media	SD	Media	SD		
Measurements						
Velar length	36.21667	2.908381	43.11290	2.075032	-3893 (-5199; -2588)	0.00001
Pharyngeal depth	43.88333	2.200013	44.58667	2.041084	-1703 (-2800; -0607)	0.008
Velopharyngeal distance	44.85669	2.158813	35.02754	2.261736	-3837 (-4979; -2694)	0.00001

Group A: Conventional uvuloplasty technique.

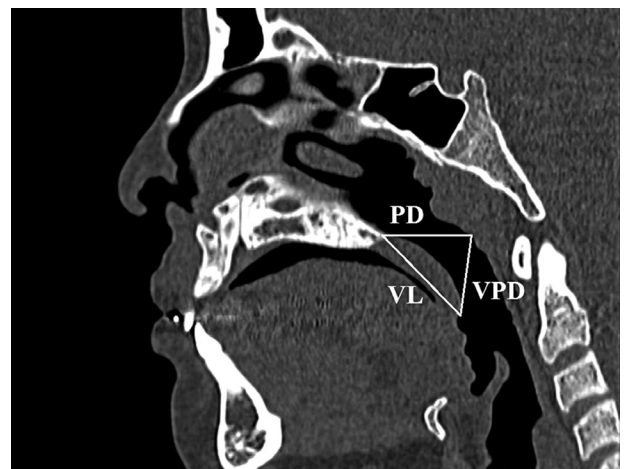
Group B: Unilateral uvuloplasty technique.

\*Student's *t* test.

CL, XXX.



**Figure 11.** Patient with diagnosis of bilateral cleft lip and palate operated on using the conventional method of uvuloplasty. Measurements: velar length (VL), 35 mm; pharyngeal depth (PD), 45 mm; velopharyngeal distance (VPD), 40 mm.



**Figure 12.** Patient with diagnosis of bilateral cleft lip and palate operated on using the unilateral uvuloplasty. Measurements: velar length (VL), 45 mm; pharyngeal depth (PD), 44 mm; velopharyngeal distance (VPD), 42 mm.

(3) a triangle of nasal mucosa is removed from the resected side to eliminate redundant tissue and to avoid continuity between the oral and nasal mucosa closure. These modifications allowed for better cosmetic outcomes, lengthening of the velum, and a reduction of the velopharyngeal space along with functional improvement<sup>1</sup> (Table 3).

In our previous study, we evaluated the cosmetic and functional benefits of unilateral uvuloplasty in a group of cleft palate patients.<sup>1</sup> At that time, we did not find functional differences (measured by the number of patients with hypernasality) between conventional uvuloplasty and unilateral uvuloplasty because of the small patient number (30 patients in each group) and a low statistical power. Therefore, the study did not establish any association between unilateral uvuloplasty and improved velopharyngeal function.

Velopharyngeal insufficiency is a rare event that requires a large number of patients for detection. Based on our clinical observations using unilateral uvuloplasty, we decided to perform a new study

using a larger number of patients with bilateral cleft palates (a type of cleft with increased rates of velopharyngeal insufficiency). Functional repair of the cleft palate should use a more physiologically sound approach for preserving normal pharyngeal structure and function. Unilateral uvuloplasty seems to increase the length of the velum and reduce the velopharyngeal space without obstructing the airway. Our clinical observations illustrated that unilateral uvuloplasty reduced the rate of velopharyngeal insufficiency (measured with perceptual voice analyses and blowing ratios). Our results showed that only 18.8% of the unilateral uvuloplasty patients had hypernasal speech. In comparison, 25.5% of the conventional uvuloplasty patients had hypernasal speech ( $P = 0.026$ ). We did not detect differences between the 2 groups when the blowing test was performed ( $P = 0.0008$ ) (Table 2). We also found that unilateral uvuloplasty significantly increased the velar length in 16.27% of the patients and decreased the velopharyngeal distance in 20.45% of the patients ( $P = 0.00001$ ) (Table 3 and Figs. 11 and 12).

Additionally, there were no significant differences between the groups in relation to the pharyngeal depth ( $P = 0.08$ ). Our findings confirm that there were no presurgical differences in velopharyngeal anatomy between the 2 groups because the surgical techniques did not change pharyngeal depth. Therefore, presurgical differences could not explain any of the other observed differences in our present study. Our findings suggest that unilateral uvuloplasty reduces the velopharyngeal gap, increases velar length, and reduces velopharyngeal distance.

There is a relationship between reducing the velopharyngeal gap and improving hypernasal speech.<sup>11,12</sup> Similar findings have been reported for the relationship between increased velar length and subsequent functional effects. The Furlow double-opposing Z-plasty is a surgical technique that addresses palatal length and muscle malposition. Numerous studies have documented the results of this technique for correcting velopharyngeal insufficiency.<sup>13–15</sup> This technique uses a double Z-plasty for velar lengthening; however, a similar outcome can be achieved using only one Z-plasty. Woo et al<sup>16</sup> has developed a technique for cleft palate repair that incorporates the concept of intravelar veloplasty and palatal lengthening using a single Z-plasty at the level of the oral mucosa. This technique compared favorably with Furlow palatoplasty in achieving velopharyngeal competence postoperatively.<sup>16</sup> Our unilateral uvuloplasty technique is working in a similar fashion using an oral mucosa unilimb Z-plasty plus intravelar veloplasty. The oral Z-plasty provides lengthening despite the fact that it is only performed on the oral mucosa layer similar to the method of Woo et al.<sup>16</sup>

A recent systematic review<sup>17</sup> observed an increased incidence of velopharyngeal insufficiency using the straight-line intravelar veloplasty repair when compared with Furlow Z-plasty.

Secondary management of velopharyngeal insufficiency includes obstructive methods such as pharyngeal flaps and pharyngoplasties, which are associated with sleep apnea because they reduce the velopharyngeal space.<sup>18–20</sup> Based on our findings, we assume that unilateral uvuloplasty reduces the development of velopharyngeal insufficiency by repairing muscle (using intravelar veloplasty), lengthening the velum, and reducing the velopharyngeal gap. Therefore, unilateral uvuloplasty should decrease the requirement for using obstructive methods.

Despite the inherent limitations of a retrospective study, our results are promising. Additional prospective studies are required to determine the relationship between unilateral uvuloplasty and the development of sleep apnea. Unilateral uvuloplasty

can be used to fix any type of cleft palate; however, the main limitation is the lateralized position of the uvula after uvular repair in wider clefts. Finally, we did not observe differences between the 2 groups regarding the presence of postoperative fistula in patients with hypernasality. As a result, we concluded that fistulas do not have a role in the development of hypernasality.

## CONCLUSIONS

We detected a reduced rate of velopharyngeal insufficiency in the unilateral uvuloplasty group when measured with perceptual voice analyses and blowing ratios. These findings correlated with the morphological evaluation of the velopharyngeal distance; the area decreased and the velar length increased in the unilateral uvuloplasty group. Therefore, we hypothesize that the functional effect of the unilateral uvuloplasty is to reduce the probability of velopharyngeal insufficiency; however, additional prospective studies are required to test this hypothesis. In conclusion, unilateral uvuloplasty is a viable alternative for primary cleft palate surgery.

*Percy Rossell-Perry, PhD, FACS*

“Outreach Surgical Center Lima Peru,”

ReSurge Int, Schell Street

No. 120 Apartment, 1503 Miraflores

Lima 18, Peru

E-mail: prosselp@usmp.pe

## ACKNOWLEDGMENT

*We thank Engineer Armando Barrientos for his assistance with biostatistics.*

## REFERENCES

- Rossell-Perry P, Navarro-Gasparetto C, Caceres-Nano E, et al. A prospective, randomized, double-blind clinical trial study to evaluate a method for uvular repair during primary palatoplasty. *J Plast Surg Hand Surg*. 2014;48:132–135.
- Navarro C, Bardales A. Atlas de Fisuras *Labiopalatinas*. Lima: MAD Corp Ed; 2000:32–38.
- Huang MH, Lee ST, Rajendran K. Structure of the musculus uvulae: functional and surgical implications of an anatomic study. *Cleft Palate Craniofac J*. 1997;34:466–474.
- Kuehn DP, Kahane JC. Histologic study of the normal human adult soft palate. *Cleft Palate J*. 1990;27:26–34; discussion 35.
- Kuehn DP, Folkins JW, Linville RN. An electromyographic study of the musculus uvulae. *Cleft Palate J*. 1988;25:348–355.
- Rossell-Perry P, Caceres Nano E, Gavino-Gutierrez AM. Association between palatal index and cleft palate repair outcomes in patients with complete unilateral cleft lip and palate. *JAMA Facial Plast Surg*. 2014;16:206–210.
- Bardach J. Two flap palatoplasty: Bardach's technique. *Oper Tech Plast Reconstr Surg*. 1995;2:211–214.
- Sommerlad B. A technique for cleft palate repair. *Plast Reconstr Surg*. 2003;112:1542–1548.

9. Henningson G, Kuehn DP, Sell D, et al; Speech Parameters Group. Universal parameters for reporting speech outcomes in individuals with cleft palate. *Cleft Palate Craniofac J.* 2008;45:1–17.
10. John A, Sell D, Sweeney T, et al. The cleft audit protocol for speech-augmented: a validated and reliable measure for auditing cleft speech. *Cleft Palate Craniofac J.* 2006;43:272–288.
11. Kummer AW, Briggs M, Lee L. The relationship between the characteristics of speech and velopharyngeal gap size. *Cleft Palate Craniofac J.* 2003;40:590–596.
12. Kummer AW, Curtis C, Wiggs M, et al. Comparison of velopharyngeal gap size in patients with hypernasality, hypernasality and nasal emission, or nasal turbulence (rustle) as the primary speech characteristic. *Cleft Palate Craniofac J.* 1992;29:152–156.
13. Perkins JA, Lewis CW, Gruss JS, et al. Furlow palatoplasty for management of velopharyngeal insufficiency: a prospective study of 148 consecutive patients. *Plast Reconstr Surg.* 2005;116:72–80; discussion 81–84.
14. Chen PK, Wu JT, Chen YR, et al. Correction of secondary velopharyngeal insufficiency in cleft palate patients with the Furlow palatoplasty. *Plast Reconstr Surg.* 1994;94:933–941; discussion 942–943.
15. Lindsey WH, Davis PT. Correction of velopharyngeal insufficiency with furlow palatoplasty. *Arch Otolaryngol Head Neck Surg.* 1996;122:881–884.
16. Woo AS, Skolnick GB, Sachanandani NS, et al. Evaluation of two palate repair techniques for the surgical management of velopharyngeal insufficiency. *Plast Reconstr Surg.* 2014;134:588e–596e.
17. Timbang MR, Gharb BB, Rampazzo A, et al. A systematic review comparing Furlow double-opposing Z-plasty and straight-line intravelar veloplasty methods of cleft palate repair. *Plast Reconstr Surg.* 2014;134:1014–1022.
18. Liao YF, Noordhoff MS, Huang CS, et al. Comparison of obstructive sleep apnea syndrome in children with cleft palate following Furlow palatoplasty or pharyngeal flap for velopharyngeal insufficiency. *Cleft Palate Craniofac J.* 2004;41:152–156.
19. Liao YF, Chuang ML, Chen PK, et al. Incidence and severity of obstructive sleep apnea following pharyngeal flap surgery in patients with cleft palate. *Cleft Palate Craniofac J.* 2002;39:312–316.
20. Peña M, Choi S, Boyajian M, et al. Perioperative airway complications following pharyngeal flap palatoplasty. *Ann Otol Rhinol Laryngol.* 2000;109:808–811.