

# Gaucher's disease diagnosed by splenectomy

Mine Adas<sup>1</sup>, Gokhan Adas<sup>2</sup>, Oguzhan Karatepe<sup>2</sup>, Merih Altioek<sup>2</sup>, Deniz Ozcan<sup>3</sup>

Departments of Endocrinology<sup>1</sup>, General Surgery<sup>2</sup> and Pathology<sup>3</sup>

Okmeydani Training Hospital, Istanbul, Turkey.

**Context:** Splenectomy continues to find common therapeutic indications for hematologic disorders. In addition, recently it is also performed in surgical clinics to assist diagnose of some illnesses. Gaucher's disease, especially Type I, is the most frequently encountered lysosomal storage disorder in man. Manifestations of it are highly variable. The most frequently found symptoms include splenomegaly with anaemia and thrombocytopenia, mostly due to hypersplenism, hepatomegaly and bone disease. **Cases:** Four patients were reported in the present study. Three of them were easily diagnosed with Gaucher's disease via bone marrow cytology, and one with Gaucher's disease was detected by pathological examination following the splenectomy. **Conclusions:** For the pouce of diagnosis of the Gaucher's disease, performing surgery is generally not necessary. However, for the cases of difficult to diagnose by classical methods, the corect diagnosis of Gaucher's disease can only be made by a special operation. (Adas M, Adas G, Karatepe O, Altioek M, Ozcan D. *North Am J Med Sci* 2009; 1: 134-136)

**Keywords:** Gaucher's disease, diagnostic splenectomy, Gaucher cells.

**Correspondence to:** Dr. Oguzhan Karatepe, Department of General Surgery, Okmeydani Training and Research Hospital, Istanbul, 34715, Turkey. Tel.: (212) 4142000, Fax: (212) 5331780. Email: drkaratepe@yahoo.com

## Introduction

Splenectomy is an established therapeutic intervention for benign hematologic disorders. Many of the hemolytic anemias and platelet disorders respond to splenectomy after failure of medical therapy. Removal of the spleen can play an important role in reducing the mortality of hematologic conditions. Diagnostic splenectomy, while there is no enough data, is still performed in the general surgery. However, there is no indication in Gaucher disease for diagnostic splenectomy. The differential diagnosis of the gaucher disease is considered in patients with unexplained organomegaly, easy bruise, bone pain, or a combination of these conditions. Bone marrow examination usually reveals the presence of Gaucher cells. All suspected diagnoses are confirmed by the determination of the acid  $\beta$ -glucosidase activity in isolated leukocytes or cultured fibroblasts.

We hereby report the four patients, three of whom were easily diagnosed Gaucher's disease with classical methods using bone marrow aspiration cytology, and one underwent teh splenectomy due to splenic mass and wasdiagnosed Gaucher's disease after pathological examination.

## Case Report

### Case 1

A 39-year-old woman who intermittently suffered from nasal bleeding lasting 3 days was admitted to our hematology department. Her vital signs on admission were as follows: blood pressure was 110/75 mmHg; pulse rate was 72 per minute; and temperature was 36.8 °C. The physical examination revealed mild hepatosplenomegaly. There was not found any palpable lymphadenomegaly. The peripheral blood count revealed a hemoglobin level of 10.5 g/dL, hematocrite value of 33.0%, white blood cell count of 7000/mm<sup>3</sup> and trombocyte count was 50,000/mm<sup>3</sup>. The liver function tests were within normal

ranges. Chest X-ray was unremarkable. Examination of the bone marrow cytology showed Gaucher cells. Upon this, we diagnosed Gaucher and supported our diagnosis with  $\beta$ -glucosidase activity in isolated leukocytes or cultured fibroblasts.

### Case 2

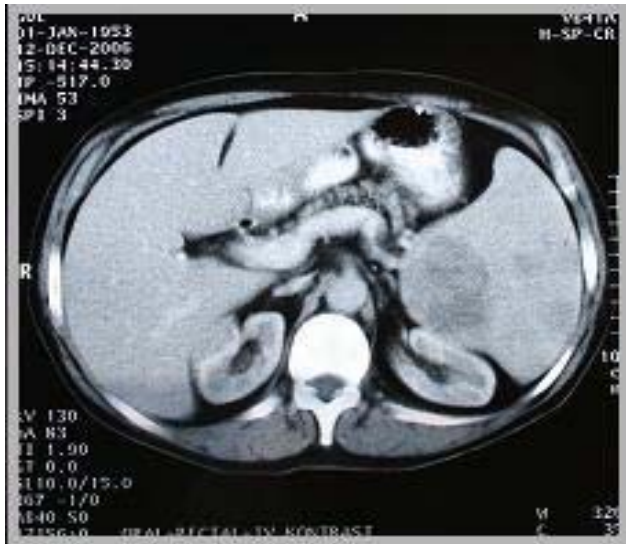A 42-year-old woman who complained of fatigue lasting 4 months was admitted to our internal medicine department. After her physical examination, we just found hepatosplenomegaly. Her laboratory examination revealed a hemoglobin level of 11.5 g/dL, a hematocrite value of 34.0%, a white blood cell count of 9000/mm<sup>3</sup> and a trombocyte count of 60,000/mm<sup>3</sup>. Therefore, we did a bone marrow examination. Then, we diagnosed Gaucher's disease.

### Case 3

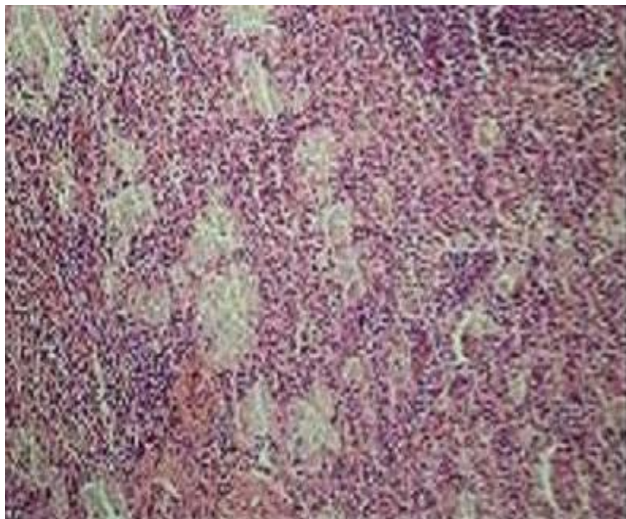
A 51-year-old man with the complaints of a 10-day history of fatigue and rectal bleeding admitted to our emergency department. After his physical examination, we found an acute hemorrhoidal disease and hepatosplenomegaly. The laboratory test revealed pancytopenia. Under the light of all these findings, we performed bone marrow examination, and Gaucher was diagnosed.

### Case 4

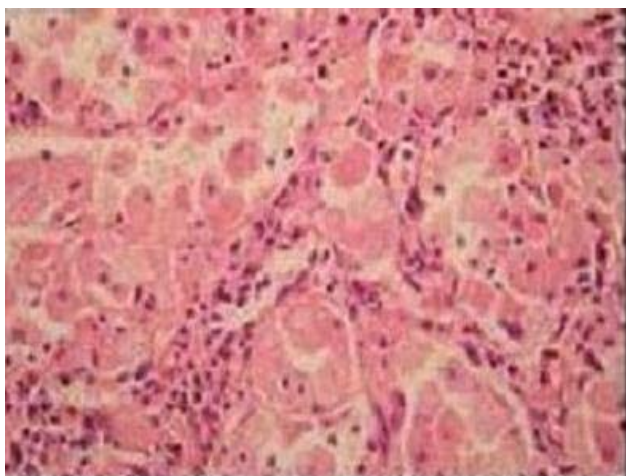
A 75-year-old man with lower back pain lasting for 2 months admitted to our orthopedic clinic. On physical examination, a slight hepatosplenomegaly was found. There were not any palpable lymphadenopathy. The laboratory tests were in normal range. The abdominal computed tomography scan (CT) showed hepatomegaly, splenomegaly of 14 cm in width and 4 cm mass at spleen (Fig. 1). The patient was referred to us for diagnostic splenectomy. Intra- and postoperative course was uneventful. Eleven samples were taken for the histopathological examination. Afterwards, we obtained findings of Gaucher's disease (Figs 2, 3).



**Fig. 1** CT scan showing splenomegaly with Gaucher's disease.



**Fig. 2** The spleen with hematoxylin and Eosin stain. Clusters of Gaucher cells with lipid deposits.



**Fig. 3** Bone marrow aspirate with hematoxylin and eosin stain, showing the curtain like macrophages known as Gaucher's cells.

## Discussion

There is not enough data in the literature about diagnostic splenectomy, however in some unclear conditions (especially in hematologic disorders) many surgeons have to perform this procedure throughout their lives (1, 2). On the other hand, therapeutic splenectomy today is performed in various cases.

Gaucher is a rare disease seen in surgical clinics. Although splenectomy does not alter the course of a patient with Gaucher's disease, it is the procedure of choice if there are signs of hypersplenism. After splenectomy, the thrombocytopenia improves (3). Some authors have proposed performing a partial splenectomy for hypersplenism in Gaucher's disease to limit the hypersplenism while preserving some splenic functions (4).

There are three different recognized types of Gaucher's disease, which are differentiated from each other depending on the presence or absence of neurological symptoms (4-5). The first symptom occurs before 10 years of age in more than 50% of the patients. Early onset of the clinical symptoms and signs predispose patients to severe phenotype and irreversible complications. The most prevalent variant of the disease is the non-neuronopathic form (type 1 Gaucher's disease, or the so-called 'adult form'). Patients in this group usually bruise easily and experience fatigue due to anemia and low blood platelets. They also have an enlarged liver and spleen, skeletal disorders, and, in some instances, lung and kidney impairment. Hepatosplenomegaly sometimes results in abdominal discomfort, and painful infarctions may occur. There are no signs of brain involvement. Symptoms can appear at any age. In type 2 Gaucher's disease, liver and spleen enlargement are apparent by 3 months of age. Patients have extensive and progressive brain damage and usually die by 2 years of age. In the third category, called type 3, liver and spleen enlargement is variable, and signs of brain involvement such as seizures gradually become apparent.

Most morbidities result from bone disease. Atypical bone pain, pathological fractures, avascular necrosis and extremely painful bone crises have a great impact on the quality of lives of many. In addition to clinical suspicion, some morphologic, hematologic and biochemical indicators can help establish the diagnosis (6). In a study conducted, the proportion of correct diagnosis (and treatment) of Gaucher patients in Germany is only between 10 to 20% (7).

The history of treatment of Gaucher's disease started with splenectomy and continued with bone marrow transplantation, before the recent introduction of safe and effective enzyme replacement therapy. Intravenous administration of the enzyme results in the breakdown of accumulated glycolipids and, subsequently, in reversal of the manifestations of the disease. In Gaucher disease today, splenectomy alleviates hematologic abnormalities in patients with hypersplenism, but it does not correct the underlying disease process. Pollock et al., showed that even after a successful open splenectomy procedure,

morbidity was about 21% and mortality was 2% (8). The morbidity and mortality increase especially in patients with the spleen of extremely great size.

## Conclusions

In accordance with “*primum non nocere*” concept, the diagnosis of Gaucher disease should be made with less invasive methods than surgery. If the surgeon decided to perform splenectomy due to splenomegaly or splenic mass, the Gaucher disease should be considered.

## References

1. Katkhouda N, Hurwitz MB, Rivera RT, et al. Laparoscopic splenectomy: outcome and efficacy in 103 consecutive patients. *Ann Surg*. 1998;228:568–578.
2. Schlachta CM, Poulin EC, Mamazza J. Laparoscopic splenectomy for hematologic malignancies. *SAGES Ann Meet Abst Book*. 1998:48.
3. Charrow J, Esplin JA, Gribble TJ, et al. Gaucher disease: recommendations on diagnosis, evaluation, and monitoring. *Arch Intern Med* 1998;158: 1754–1760.
4. Schwartz SI. Role of splenectomy in hematologic disorders. *World J Surg*. 1996;20:1156–1159.
5. Gielchinsky Y, Elstein D, Hadas-Halpern I, Lahad A, Abrahamov A, Zimran A. Is there a correlation between degree of splenomegaly, symptoms and hypersplenism? A study of 218 patients with Gaucher disease. *Br J Haematol* 1999;106: 812–816.
6. Aerts JM, Hollak CE. Plasma and metabolic abnormalities in Gaucher’s disease. *Baillieres Clin Haematol* 1997;10: 691–709.
7. Niederau C, Rolfs A, vom Dahl S, Haussinger D, Poll LW, Mengel E, Beck M. Diagnosis and therapy of Gaucher disease. Current recommendations of German therapy centers in the year 2000. *Med Klin (Munich)*. 2001; 96:32-39.
8. Pollock RE, Hohn DC. Splenectomy. In: Roh MS, Ames FC, eds. *Advanced Oncologic Surgery*. London: Mosby-Year Book Europe; 1994, p.989.