

Adaptive optics imaging of the retina

Rajani Battu, Supriya Dabir, Anjani Khanna, Anupama Kiran Kumar, Abhijit Sinha Roy

Adaptive optics is a relatively new tool that is available to ophthalmologists for study of cellular level details. In addition to the axial resolution provided by the spectral-domain optical coherence tomography, adaptive optics provides an excellent lateral resolution, enabling visualization of the photoreceptors, blood vessels and details of the optic nerve head. We attempt a mini review of the current role of adaptive optics in retinal imaging. PubMed search was performed with key words Adaptive optics OR Retina OR Retinal imaging. Conference abstracts were searched from the Association for Research in Vision and Ophthalmology (ARVO) and American Academy of Ophthalmology (AAO) meetings. In total, 261 relevant publications and 389 conference abstracts were identified.

Key words: Adaptive optics, cone count, cone spacing, retinal imaging

Access this article online

Website:

www.ijo.in

DOI:

10.4103/0301-4738.126185

Quick Response Code:



The invention of the direct ophthalmoscope gave a boost to the study of retinal diseases, with the knowledge of reversibility of rays and paraxial viewing. A further development was the indirect ophthalmoscope, which allowed rays to form real images using the same system that converged the light into the eye. Unlike imaging of everyday objects, imaging of the retina is limited by the size of the entrance pupil, and the outgoing rays being imaged are restricted by the size of the same exit pupil.^[1,2]

The ability to retrieve these outgoing rays and form an image was possible with the development of the fundus camera. Although limited initially by the film, its resolution and image characteristics were significantly enhanced with charge-coupled devices (CCD cameras) producing a digital image.^[3]

The Scanning Laser Ophthalmoscopy (SLO) marked a change in photographic capture technique which utilized the principle of illuminating only a small spot of the retina with collimated laser light directed through the very centre of the pupil and capturing the reflections from its entire surrounds within the pupil confines.^[4] This reversed the optics of entrance and exit imaging and allowed usage of much lower levels of light energy with better images. However, the small spot imaged at each instant of time necessitated a scanning system to allow a large area of the fundus to be scanned and produce an image after collating the scans with appropriate software; this was done with a series of rotating polygonal mirrors and galvanometric mirrors to produce a 'raster scan'. This resulted in two effects on the viewing of the image. Axial resolution was further addressed by using a simple, but ingenious principle of 'confocal scanning' where a pinhole of a sufficient diameter interposed before the photo detector system allowed scattered

light in front of and behind 'the plane of focus' to be reflected off and only the 'confocal rays' finding their way through the pinhole and onto the photo detector. This allowed micrometer precision axial resolution at an image 'plane' combined with the lateral resolution offered by the SLO.

Optical Coherence tomography (OCT) added a new dimension to retinal imaging with the ability to develop cross sectional images of retinal tissue to a submicron axial resolution and millimeter penetration using a low coherence interference technique combined with a broadband light source.^[5] Time domain initially and later Fourier domain OCT techniques have further improved axial resolution of tissue cross-section.

Despite technological advancements, imaging of the retina was limited by the 'optical aberrations' of the eye, also expressed as 'wave aberrations'. Wave front distortions of incoming light limit the eye's cones' resolution capacity. Conversely, wave front distortions of light emerging from the eye, limit the capacity of optical systems' lateral resolution.

Wave front aberrations may be Low order (LOA - defocus or astigmatism) or High order (HOA-coma, trefoil and spherical aberration).^[6] The LOA aberrations constitute about 90% of all aberrations of the human eye and have been addressed effectively in many optical imaging devices including the fundus camera. However, HOAs still pose a limit to the lateral resolution capability, as they are non stable; recognition and correction have to be continuous to allow for excellent resolution.

Adaptive optics (AO) technology aims to correct these ocular aberrations and enhance performance of the optical systems. AO was first used in astronomical telescopes to allow for correction of atmospheric aberrations on wave fronts entering telescopes leading to significant loss of resolution and contrast.^[7]

The three principal components of such an AO system include a wave front sensor (typically Hartman-Shack), a

Narayana Nethralaya, Bangalore, Karnataka, India

Correspondence to: Dr. Rajani Battu, Department of Vitreoretina, Narayana Nethralaya, 121/C, Chord Road, Rajajinagar, 1st 'R' Block, Bangalore - 560 010, Karnataka, India E-mail: rajanibattu@gmail.com

Manuscript received: 15.11.13; **Revision accepted:** 05.01.14

deformable mirror and software to control the interaction between these two components. The wave front sensor measures the native aberrations of the eye *in vivo*. The deformable mirror uses a complex system of actuators to adjust several small mirrors to compensate for the aberrations measured. The interaction between the two is controlled by specialized software [Fig. 1].^[6,8]

Adaptive optics in retinal imaging could be used with flood illumination or combined with both the SLO and the OCT to produce high quality images whose lateral resolution permits cone discrimination and also allows the study of blood vessels and cells.^[9,10] By compensating for the aberrations caused by irregularities of the optics of the eye, lateral (transverse) resolutions to the order of 2 μm can be achieved, thereby allowing for the visualization of individual cone photoreceptors.^[11]

With the rapidly increasing potential for adaptive optics imaging, we herein provide a mini-review of the current status of AO in retinal imaging.

Applications

AO system allows direct visualization of individual rod and cone photoreceptor cells, retinal pigment epithelial (RPE) cells, red and white blood cells, lamina cribrosa and retinal blood vessels. Cone photoreceptors are easily imaged owing to their unique wave-guiding properties, and most of the research published to date is focused on this.^[12-16] Imaging rods is more tedious given their small diameter ($\sim 2 \mu\text{m}$), and their significantly reduced wave-guiding properties compared to cones.^[17]

AO imaging in normal subjects

Data from the AO imaged in healthy eyes is necessary in establishing a baseline of the cone characteristics *in vivo*, to enable detection of retinal diseases at a very early stage.

One of the AO prototypes (rtx 1, Imagine Eyes, Orsay,

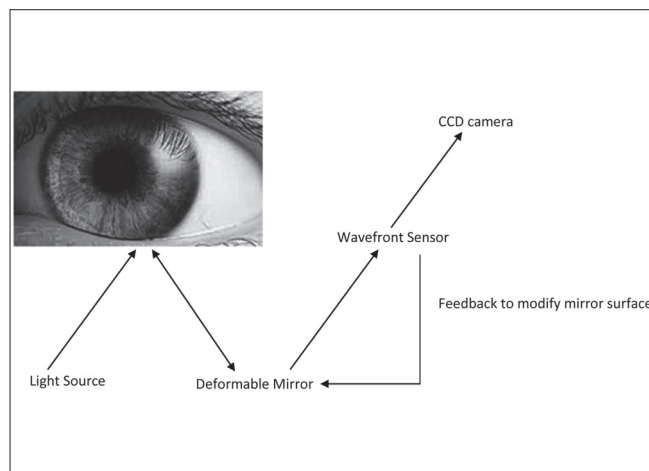


Figure 1: Schematic outline of adaptive optics imaging system. A beam of light enters the eye, and a small amount is reflected back out of the eye and into the optical system. Reflected light is altered by the deformable mirror for optical aberrations based on measurements made by the wave-front sensor. Information about the aberrations of the wave front is processed by the control system that provides feedback to the deformable mirror

France) operates at a wavelength of 750 nm to measure and correct aberrations while maintaining focus at different retinal layers. Another light source of 850 nm is used to illuminate the retina and capture an image of $4^0 \times 4^0$. For fixation, the device has a yellow cross, which can be moved by the investigator. A sequence of 40 frames (frame rate, 9.5 fps) is acquired on overlapping regions of the posterior pole [Fig. 2].

After acquisition, a program provided by the manufacturer is used to produce a final image with enhanced signal-to-noise ratio. Frames exhibiting large motion artifacts owing to eye movement or blinking are manually removed before processing. Before analysis, the retinal magnification factor is calculated in each eye using the Gullstrand schematic eye as a model.

Image analysis of the acquired image is then performed using Image J (version 1.45a, NIH, Bethesda, MD). Once the region of interest (ROI) is selected, analysis of the region provides three parameters mainly- cone packing density, cone spacing and the Voronoi analysis. The Voronoi analysis assesses the regularity of the photoreceptors and the percentage of hexagonal polygons. The ROI can be selected as specific areas in the posterior pole, for comparison with various structural pathologies. The possible range of spherical correction on the rtx 1 is -12DS to +6DS. Some AO systems are unable to resolve the central foveal cones due to the high foveal cone packing density [Figs. 3-5].

In a study by Chui *et al.*, cone densities ranged from approximately 40,000 cones/ mm^2 at 1^0 to 10,000 cones/ mm^2 at 7^0 from the fovea. They also indicated that the human cone photoreceptors are arranged hexagonally near the fovea with the cones becoming more irregular as the retinal eccentricity increases, perhaps due to rod intrusion.^[18] A study by Park *et al.*, using a Canon prototype AO-SLO showed a cone density of 32,200 cells/ mm^2 at 0.5 mm from the fovea, which decreased to 11,600 cells/ mm^2 at 1.5 mm from the fovea.^[19] They did not find demographic and clinical factors, such as gender, ocular dominance, and race/ethnicity to be determinants of cone packing density. Only retinal eccentricity and axial length were significantly associated with measured cone packing density.

Lombardo *et al.*, using the rtx 1 AO observed that with




Figure 2: Raw image before analysis from the rtx 1 (from a normal subject). Note the multiple white dots corresponding to the cones

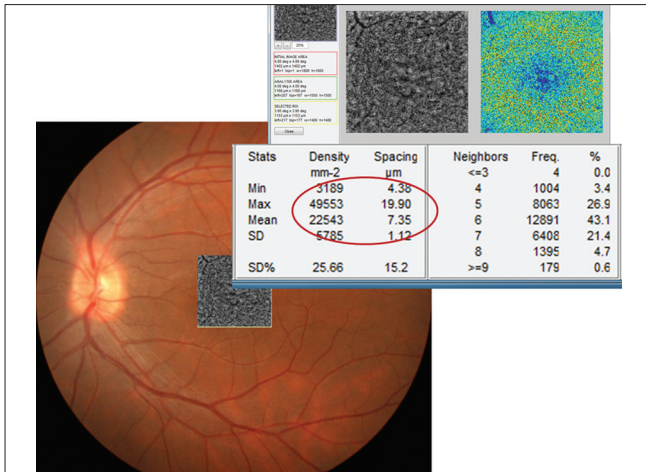


Figure 3: Cone packing density in a normal subject on the rx 1. The encircled area shows the mean and Standard Deviation (SD) of cone density and cone spacing in the central 4° X 4°

the exception of the central fovea (<160 μ), the photoreceptor structure was well resolved in most of the eyes. The inter-individual variation in cone density was 16%, between 260 μ m and 600 μ m eccentricity from the foveal center.^[8] Song *et al.*, reported that cone-packing density in the living human retina decreased as a function of age.^[20]

AO in myopia

Axial length (AL) measurements are an important consideration in the analysis of cone packing density. Although the mechanisms are not completely understood, it has been shown that the eye continues to grow into early adulthood, while the cones reach their final number early in development.^[21] It therefore stands to reason that cone density varies across eyes with varying axial lengths.

In a population of 18 eyes of 18 healthy subjects (age range 23 to 43 years, AL range 22.86 to 28.31 mm), Li *et al.*, found that cone density decreased significantly with increasing

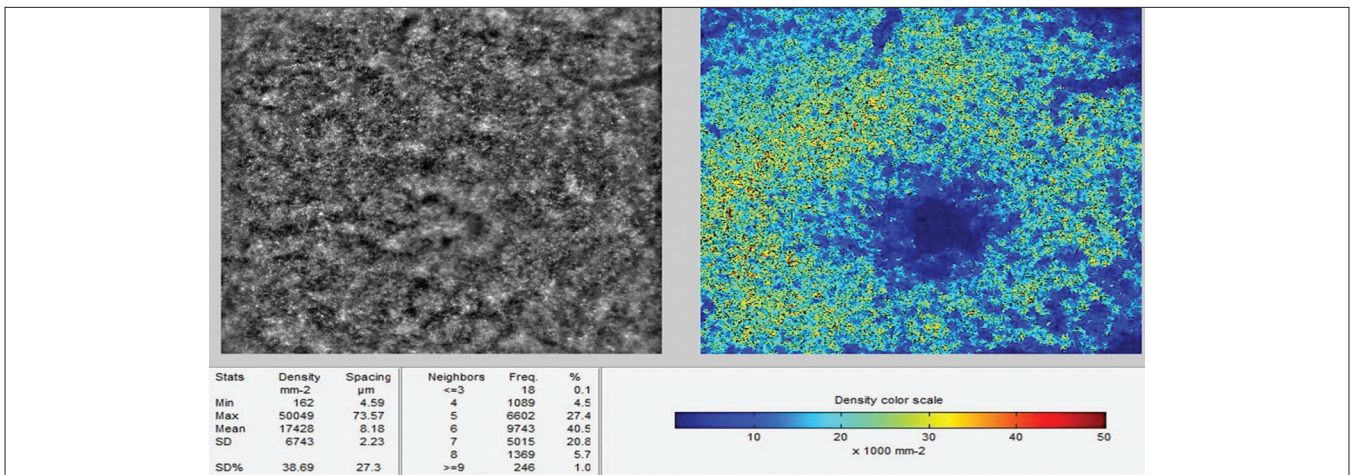


Figure 4: Voronoi tessellation of photoreceptors (cones) in a normal subject on the rx 1. The colour scale shows the packing density in the central 4° X 4°. The apparent low cone density depicted in the foveal centre is due to a lack of adequate resolution of the device in that region. In this patient, the mean cone count was 17428 \pm 6743/mm²

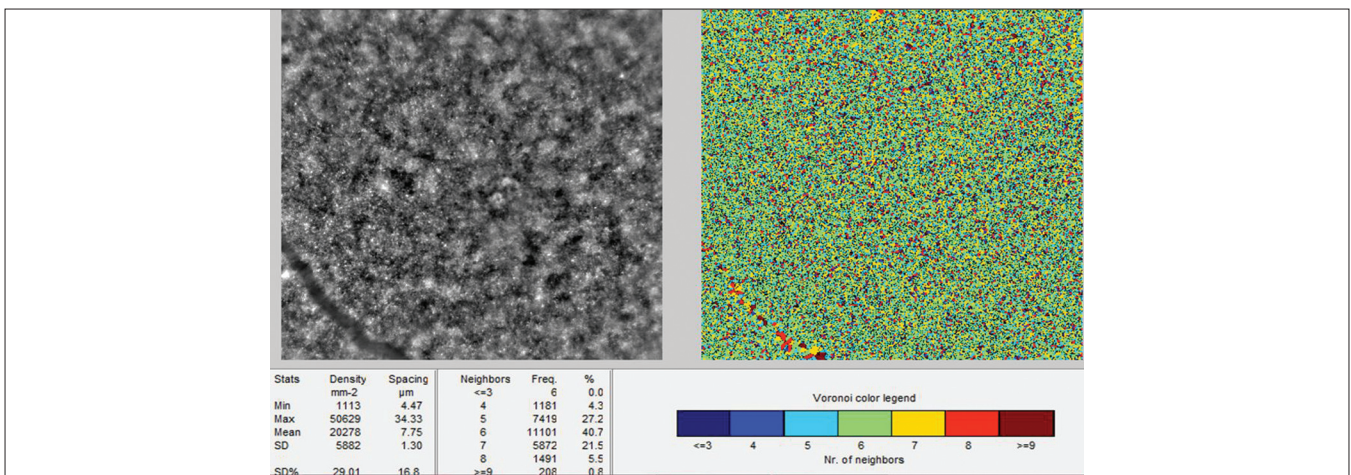


Figure 5: Voronoi tessellation of cones in a 4° X 4° square of a normal subject. The color scale shows the Voronoi legend

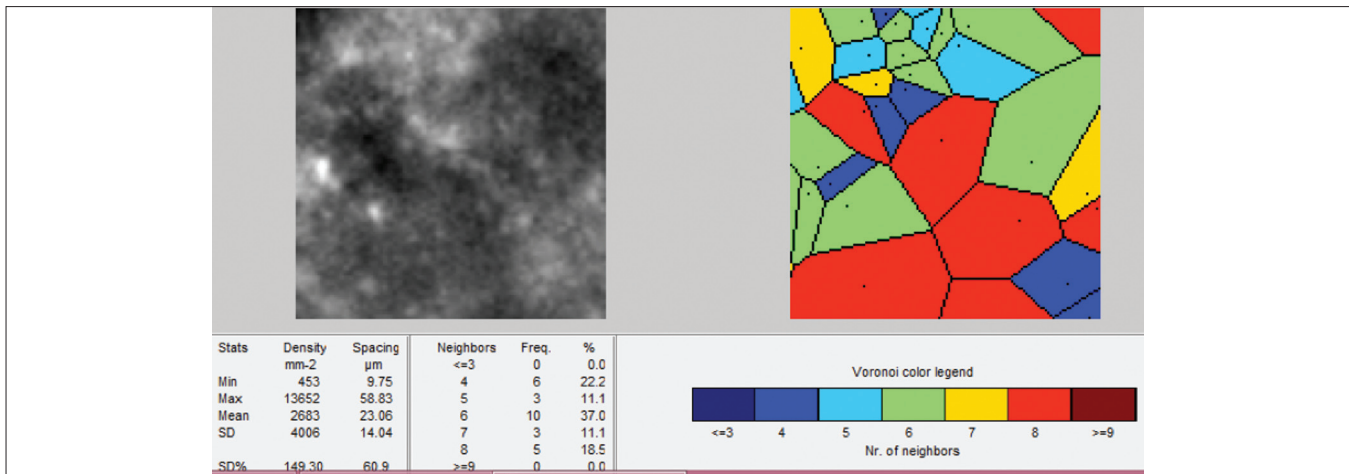


Figure 6: Voronoi tessellation of photoreceptors (cones) in a patient with rod-cone dystrophy on the rtx 1. The colour scale shows the packing density in the superior 100 μ×100 μ (0.34° X 0.34°). In this patient, the mean cone count was 2683 ± 4006/mm²

AL at eccentricities between 100 μ and 300 μ from the foveal center.^[22]

Chui *et al.*, reported cone packing density variations with refractive error; they found that the cone packing density was lower in highly myopic eyes than in emmetropic eyes at both 1.0 mm and 2.0 mm eccentricity from the foveal center.^[18] They also compared differences between eyes based on simple angular density of the cones—that is, using the visual angle rather than retinal size, which required correcting the data for the axial length of the eye. They found that the cone packing density was much more constant with axial length when expressed in cells per square degree of visual sub tense than when expressed as cells per mm² of retinal surface area.^[18]

Park *et al.*, also found a statistically significant negative correlation between axial length and cone packing density (decrease of 341 cell/mm² per 1 mm increase in axial length).^[19] Lombardo *et al.*, also detected a higher amount of intraocular higher order aberrations in myopic eyes. The retinal stretching resulting from the increased AL in the eye has been postulated to cause the lower cone density estimated in myopic eyes.^[18]

Inherited retinal diseases

Inherited retinal degenerations affect about 1:2000 to 1:7000 people worldwide.^[23] These are a group of disorders like Retinitis Pigmentosa (RP), Stargardt disease, Usher's syndrome and Cone-rod dystrophies which are characterized by slow progressive death of rod and cone photoreceptors and relentless vision loss.^[24] There is presently no definitive treatment for most of these; several therapeutic trials that are underway include stem cells, gene therapy, neuroprotective drugs and retinal prosthesis.^[25-27] One limitation to the development of these modalities has been lack of sensitive outcome measures of disease progression and response to therapy. Tests of visual function cannot be used as outcome measures as significant photoreceptor loss must have occurred before reliable significant differences are measurable in visual function. Objective sensitive measures of photoreceptor survival may reduce the time to identify a treatment effect of an experimental therapy; studying surviving photoreceptors using the adaptive optics may be one step in this direction. It

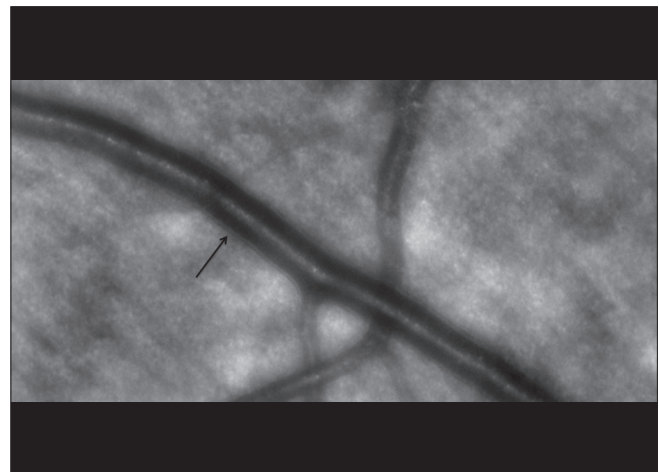


Figure 7: High resolution image of the venule and arteriole. The black arrow points to the vessel wall (venule). Note the defocused retinal nerve fibre layer in the background

is therefore not surprising that the majority of scientific work on the AO is dedicated to the study of photoreceptors, mostly cones [Fig. 6].

AO has been used in the following instances in the study of photoreceptors:

1. To study photoreceptor density and structure in patients with inherited retinal degenerations:

Various groups have studied the cone photoreceptor structure and their functional correlation in inherited retinal disorders. Chen *et al.*, used AO-SLO, SD-OCT and fundus guided microperimetry to study macular cone structure, lipofuscin deposition and visual function in patients with Stargardt disease and found a correlation with abnormal autofluorescence and abnormalities of cone morphology and packing on AO with corresponding impaired function.^[28] Tojo *et al.*, found a correlation between AO images, OCT and fundus autofluorescence (FAF) images in 2 patients with RP. They demonstrated that the edge of the high density FAF ring (that corresponded to the border of external limiting membrane and inner segment- outer segment (IS-OS) line

on OCT) showed blurring of cone photoreceptors at the ring as compared to controls on AO. They attributed this to loss of photoreceptor outer segments in patients with RP.^[29]

Other studies have demonstrated the correlation of cone parameters on AO images with measures of central visual function including visual acuity, foveal threshold and multifocal electroretinogram (ERG) in patients with RP and cone-rod dysfunction. Cone spacing measures were also seen to be reproducible suggesting that these can be useful in monitoring disease progression and response to treatment.^[30,31]

Rod photoreceptors have also recently been imaged with AO-SLO and the emergence of first rods has been demonstrated at 190 μ from foveal centre as demonstrated by histopathological studies.^[32] The rod mosaic best focus has been seen to be located 10 μ shallower than cones at retinal eccentricities >8°. This can open new insights into the study of rod disorders.

2. Assessment of photoreceptor function:

Variations in photoreceptor reflectivity have been observed in different disease states. Photoreceptor reflectivity in AO appears to represent an optical biomarker of photoreceptor integrity. In patients with In patients with achromatopsia, the remaining cones are sparse and have been shown to have reduced reflectivity. Similar cone phenotype is also seen in patients with opsin mutations, acute macular neuroretinopathy (AMN) and closed globe blunt ocular trauma.^[33]

Rod and cone photoreceptors have also been shown to vary in intensity over time and by developing methods to quantify this temporal variability, more insight into the health of photoreceptors may be available.^[34]

3. To decide which patients will benefit the most from treatment:

AO imaging of achromatopsia has revealed varying degrees of retained cone structure. Studying the structure and function of retained cones can set a baseline to assess those patients who may benefit from gene therapy (as has been successful in dog and mouse models) and to anticipate the degree of functional improvement that can be expected based on the patient's baseline cone count.^[14] Hence, it can help prioritize those patients who can undergo trial of gene therapy (*i.e* those with certain number of retained cones) over patients who may not benefit from therapy (those with absent cones).

4. Monitoring response to treatment:

In a study by Talcott *et al.*, AOSLO was used to longitudinally study the cone spacing and density in 3 patients implanted with Ciliary Neurotrophic Factor (CNTF) encapsulated implant.^[35] While other modalities like visual field sensitivity and electroretinography responses did not show significant changes at 24 months, AOSLO images showed significantly reduced rates of cone loss in CNTF treated eyes. Longitudinal imaging and monitoring of individual cones was also done and they concluded that AOSLO provided a sensitive measure of disease progression and treatment responses in patients with retinal degenerations.

Vascular analysis on AO

Imaging and analysis of the retinal vasculature can be a surrogate marker for systemic vascular health. Correlations between vascular abnormalities in the retina and elsewhere

in the body have been demonstrated in a diverse array of conditions including diabetes, hypertension, stroke and migraine. The earliest change in disease begins at the level of the microvasculature; however, current imaging methods lack the lateral resolution to track blood flow at the capillary level.^[36] Imaging retinal capillaries is difficult because of their small size, low contrast, and arrangement in multiple planes of varying retinal depth.

Due to its high-magnification, resolution, and real time visualization it is possible to observe details of vascular wall and contents using AO [Fig. 7]. Lombardo *et al.*, used an AO flood-illumination retinal camera and described a characteristic pattern of the lumen of a blood vessel, consisting of a central high-intensity channel and two peripheral darker channels. They attributed this difference in intensity to the curvature of the vessel wall and the different shear rate of erythrocytes.^[37] In a subset of diabetics, they showed the capillary lumen caliber to be significantly narrower in eyes with non-proliferative diabetic retinopathy than age matched controls.^[34]

Martin and Roorda imaged parafoveal capillary leukocyte movement and measured their velocity without contrast dyes. A follow up study investigated the possible role of the cardiac cycle on capillary leukocyte velocity by directly measuring capillary leukocyte pulsatility.^[38]

The detection of preclinical abnormalities of retinal microcirculation may potentially represent an additional advantage of AO retinal imaging in patients with diabetes and cardiovascular diseases. Tam *et al.*, evaluated the parafoveal capillary network in patients with Type 2 diabetes. They showed a capillary dropout and a higher tortuosity of the arteriovenous channels in patients with no retinopathy compared to healthy controls.^[39] Popovic *et al.*, imaged the foveal capillary networks of five healthy subjects with no previous history of ocular or neurologic disease or surgery with a novel high-resolution, wide-field dual-conjugate adaptive optics (DCAO) imaging instrument.^[39] Their results showed a mean foveal avascular zone (FAZ) area of 0.302 ± 0.100 mm² and mean equivalent diameter of 612 ± 106 μ m.^[40]

Clinical limitations and future prospects of adaptive optics

As adaptive optics imaging finds more clinical applications, normative databases need to be developed for different populations as a reference for disease states. Universally acceptable standards and protocols need to be defined for image acquisition and analysis to ensure reproducibility and comparability worldwide. Acquisition of AO images of sufficient quality to perform quantitative cone spacing measures is difficult in patients with unstable fixation, dense cataracts and other media opacities. The use of AO may be limited owing to costs and lack of expertise.

In summary, AO is an innovative new tool in the extensive armamentarium of ophthalmologists to explore the cellular details of the retina. It may help us understand the pathogenesis of diseases at a subclinical stage, thus paving way for the exciting possibility of early treatment for these diseases. It is possible that as more detailing of cellular structures becomes possible, we may need to develop better analytical tools. As treatment paradigms for inherited retinal diseases evolve, it is likely that AO systems will play a major role in early diagnosis and monitoring therapies.

References

- Colenbrander A. Principles of ophthalmology. In: Tasman W, Jaeger EA, editors. *Duane's Ophthalmology* 2013 ed 2012, vol. 1, chap 63.
- Miller D TE, Atebara NH. Ophthalmic instrumentation. In: Yanoff M, Duker JS, editors *Ophthalmology* 2008, chap 2.10.
- Meyer-Schwickerath GR. Ophthalmology and photography. *Am J Ophthalmol* 1968;66:1011-9.
- Mainster MA, Timberlake GT, Webb RH, Hughes GW. Scanning laser ophthalmology. Clinical applications. *Ophthalmology* 1982;89:852-7.
- Puliafito CA, Hee MR, Lin CP, Reichel E, Schuman JS, Duker JS, *et al.* Imaging of macular diseases with optical coherence tomography. *Ophthalmology* 1995;102:217-29.
- Lombardo M, Lombardo G. Wave aberration of human eyes and new descriptors of image optical quality and visual performance. *J Cataract Refract Surg* 2010;36:313-31.
- Babcock HW. Adaptive optics revisited. *Science* 1990;249:253-7.
- Lombardo M, Serrao S, Ducoli P, Lombardo G. Eccentricity dependent changes of density, spacing and packing arrangement of parafoveal cones. *Ophthalmic Physiol Opt* 2013;33:516-26.
- Duncan JL, Zhang Y, Gandhi J, Nakanishi C, Othman M, Branham KE, *et al.* High-resolution imaging with adaptive optics in patients with inherited retinal degeneration. *Invest Ophthalmol Vis Sci* 2007;48:3283-91.
- Torti C, Povazay B, Hofer B, Unterhuber A, Carroll J, Ahnelt PK, *et al.* Adaptive optics optical coherence tomography at 120,000 depth scans/s for non-invasive cellular phenotyping of the living human retina. *Opt Express* 2009;17:19382-400.
- Zhang Y, Roorda A. Evaluating the lateral resolution of the adaptive optics scanning laser ophthalmoscope. *J Biomed Opt* 2006;11:014002.
- Godara P, Dubis AM, Roorda A, Duncan JL, Carroll J. Adaptive optics retinal imaging: emerging clinical applications. *Optom Vis Sci* 2010;87:930-41.
- Lombardo M, Lombardo G, Ducoli P, Serrao S. Adaptive optics photoreceptor imaging. *Ophthalmology* 2012;119:1498-e2.
- Carroll J, Kay DB, Scoles D, Dubra A, Lombardo M. Adaptive optics retinal imaging--clinical opportunities and challenges. *Curr Eye Res* 2013;38:709-21.
- Kim JE, Chung M. Adaptive optics for retinal imaging: current status. *Retina* 2013;33:1483-6.
- Lombardo M, Serrao S, Devaney N, Parravano M, Lombardo G. Adaptive optics technology for high-resolution retinal imaging. *Sensors (Basel)* 2013;13:334-66.
- Alpern M, Ching CC, Kitahara K. The directional sensitivity of retinal rods. *J Physiol* 1983;343:577-92.
- Chui TY, Song H, Burns SA. Adaptive-optics imaging of human cone photoreceptor distribution. *J Opt Soc Am A Opt Image Sci Vis* 2008;25:3021-9.
- Park SP, Chung JK, Greenstein V, Tsang SH, Chang S. A study of factors affecting the human cone photoreceptor density measured by adaptive optics scanning laser ophthalmoscope. *Exp Eye Res* 2013;108:1-9.
- Song H, Chui TY, Zhong Z, Elsner AE, Burns SA. Variation of cone photoreceptor packing density with retinal eccentricity and age. *Invest Ophthalmol Vis Sci* 2011;52:7376-84.
- Grosvenor T, Scott R. Role of the axial length/corneal radius ratio in determining the refractive state of the eye. *Optom Vis Sci* 1994;71:573-9.
- Li KY, Tiruveedhula P, Roorda A. Intersubject variability of foveal cone photoreceptor density in relation to eye length. *Invest Ophthalmol Vis Sci* 2010;51:6858-67.
- Fasiuddin A. Inherited retinal degenerations. *Int Ophthalmol Clin* 2010;50:45-56.
- Hartong DT, Berson EL, Dryja TP. Retinitis pigmentosa. *Lancet* 2006;368:1795-809.
- Stone EM. Progress toward effective treatments for human photoreceptor degenerations. *Curr Opin Genet Dev* 2009;19:283-9.
- Huang Y, Enzmann V, Ildstad ST. Stem cell-based therapeutic applications in retinal degenerative diseases. *Stem Cell Rev* 2011;7:434-45.
- Farrar GJ, Millington-Ward S, Chadderton N, Humphries P, Kenna PF. Gene-based therapies for dominantly inherited retinopathies. *Gene Ther* 2012;19:137-44.
- Chen Y, Ratnam K, Sundquist SM, Lujan B, Ayyagari R, Gudiseva VH, *et al.* Cone photoreceptor abnormalities correlate with vision loss in patients with Stargardt disease. *Invest Ophthalmol Vis Sci* 2011;52:3281-92.
- Tojo N, Nakamura T, Fuchizawa C, Oiwake T, Hayashi A. Adaptive optics fundus images of cone photoreceptors in the macula of patients with retinitis pigmentosa. *Clin Ophthalmol* 2013;7:203-10.
- Wolfgang JI, Chung M, Carroll J, Roorda A, Williams DR. High-resolution retinal imaging of cone-rod dystrophy. *Ophthalmology* 2006;113:1019.e1.
- Choi SS, Doble N, Hardy JL, Jones SM, Keltner JL, Olivier SS, *et al.* *In vivo* imaging of the photoreceptor mosaic in retinal dystrophies and correlations with visual function. *Invest Ophthalmol Vis Sci* 2006;47:2080-92.
- Dubra A, Sulai Y, Norris JL, Cooper RF, Dubis AM, Williams DR, *et al.* Noninvasive imaging of the human rod photoreceptor mosaic using a confocal adaptive optics scanning ophthalmoscope. *Biomed Opt Express* 2011;2:1864-76.
- Genead MA, Fishman GA, Rha J, Dubis AM, Bonci DM, Dubra A, *et al.* Photoreceptor structure and function in patients with congenital achromatopsia. *Invest Ophthalmol Vis Sci* 2011;52:7298-308.
- Cooper RF, Dubis AM, Pavaskar A, Rha J, Dubra A, Carroll J. Spatial and temporal variation of rod photoreceptor reflectance in the human retina. *Biomed Opt Express* 2011;2:2577-89.
- Talcott KE, Ratnam K, Sundquist SM, Lucero AS, Lujan BJ, Tao W, *et al.* Longitudinal study of cone photoreceptors during retinal degeneration and in response to ciliary neurotrophic factor treatment. *Invest Ophthalmol Vis Sci* 2011;52:2219-26.
- Bedggood P, Metha A. Direct visualization and characterization of erythrocyte flow in human retinal capillaries. *Biomed Opt Express* 2012;3:3264-77.
- Lombardo M, Parravano M, Serrao S, Ducoli P, Stirpe M, Lombardo G. Analysis of retinal capillaries in patients with type 1 diabetes and nonproliferative diabetic retinopathy using adaptive optics imaging. *Retina* 2013;33:1630-9.
- Martin JA, Roorda A. Direct and noninvasive assessment of parafoveal capillary leukocyte velocity. *Ophthalmology* 2005;112:2219-24.
- Tam J, Martin JA, Roorda A. Noninvasive visualization and analysis of parafoveal capillaries in humans. *Invest Ophthalmol Vis Sci* 2010;51:1691-8.
- Popovic Z, Knutsson P, Thaug J, Owner-Petersen M, Sjostrand J. Noninvasive imaging of human foveal capillary network using dual-conjugate adaptive optics. *Invest Ophthalmol Vis Sci* 2011;52:2649-55.

Cite this article as: Battu R, Dabir S, Khanna A, Kumar AK, Roy AS. Adaptive optics imaging of the retina. *Indian J Ophthalmol* 2014;62:60-5.

Source of Support: Nil. **Conflict of Interest:** None declared.