



## Original Article

# Morphometric and Ultrastructure studies of Primordial Follicles and Expression of Estrogen-dependent Genes in the Ovaries of Domestic Cats



Odenheimer Ariel<sup>a</sup>, Shaomian Yao<sup>a</sup>, Michael T. Kearney<sup>b</sup>, Scott D. Joudrey<sup>c</sup>, Fakhri Al-Bagdadi<sup>a,\*</sup>

<sup>a</sup> Department of Comparative Biomedical Sciences, School of Veterinary Medicine, Louisiana State University, Baton Rouge, LA 70803, USA

<sup>b</sup> Department of Pathobiological Sciences, School of Veterinary Medicine, Louisiana State University, Baton Rouge, LA 70803, USA

<sup>c</sup> Veterinary Specialty and Emergency Center, 301 Veterans Highway, Levittown, PA 19056, USA

## ARTICLE INFO

*Article history:*

Received 19 August 2015

Received in revised form 5 October 2015

Accepted 11 October 2015

Available online 17 October 2015

*Keywords:*

Ovary

Primordial follicles

Histology

Ultrastructure

Cat

Gene expression

## ABSTRACT

The aim of this study was to compare and estimate the population of the primordial follicle morphometrically and ultrastructurally in the left and right side ovaries of 10 ovariectomized healthy domestic shorthair cats. The ovaries were processed for light microscopy, electron microscopy, and estrogen-dependent gene expression for assessments. A total of 15,092 primordial follicles with and without a nucleus were examined and counted. A total of 6842 primordial follicles with a nucleus were examined and counted. The light-microscopy numerical data were collected from two histological sections per ovary for a total of 20 sections from the left ovary and 20 sections from the right ovary. The average surface area of the histological sections was 645.99 mm<sup>2</sup>. The number of tertiary follicles was found to be higher in the left ovaries than in the right ovaries. The primordial follicles are under the tunica albuginea at various levels. Some are crowded or scattered in one or two rows, although at times, there were areas without any primordial follicles. The primordial follicles varied in size, and were surrounded by 4–10 squamous granulosa cells. Some primordial follicles shared their ooplasm with one or two neighboring primordial follicles, forming a giant primordial follicle with two or three nuclei. The ultrastructure of the primordial follicles showed rounded nuclei with distinct nucleoli, rounded and elongated mitochondria, and a considerably thick basement membrane under the granulosa cells. The squamous granulosa cells showed well-developed microvilli intermingled with the microvilli of the oocyte oolemma. Elongated mitochondria, coated pits, multicystoplasmic vesicles, ribosomes, and Golgi apparatuses were obvious in the oocyte ooplasm. Large vesicles contain small multivesicles and some scattered lipid globules in the ooplasm. There were estrogen-dependent gene-expression differences between the right and left ovaries. Further gene research is in the plan, using a larger pool of cats, with a focus on age differences.

© 2016 Published by Elsevier Ltd. on behalf of Saudi Society of Microscopes.

## 1. Introduction

Over the last 20 years, reproductive biotechniques have greatly improved, especially in species that have economical applications or species at risk of extinction. The

\* Corresponding author.

E-mail address: [albagdadi@vetmed.lsu.edu](mailto:albagdadi@vetmed.lsu.edu) (F. Al-Bagdadi).

first target of studies on reproductive biology involved the sperm and embryos. The cryopreservation of animal oocytes holds an enormous potential for use with other applied reproductive biotechnologies [1]. Attempts to cryopreserve oocytes of many mammalian species have been reported [2], but the subsequent fertility and developmental rates using cryopreserved oocytes have been much lower than those for fresh oocytes [3,4].

Studies of the female gamete have received more interest during the last 20 years [5–11]. The morphometric and ultrastructure characterizations of feline follicles need further investigation. It has been stated that early degenerative changes are detected only by the electron microscope [12,13]. This is due to the light-microscope-resolution limitation. Moreover, many reports are now using ultrastructure studies as tools to evaluate the damage or changes caused by assisted reproductive techniques, especially for the cryopreservation of fully grown oocytes [1,14]. The ultrastructure changes of the ovarian follicles have been examined in cattle [15,16], ewes [17,18], goats [19], and camels [20]. The primordial follicles represent more than 90% of all follicles in the ovaries, and are found in ovaries independent of age or stage of the estrous cycle [21–23]. After reviewing the literature, it is clear that there is an interest in the primordial-follicle changes in relation to age, species, and count variations of primordial follicles in the left and right ovaries.

The objective of the present study was to analyze the morphometric parameters of the primordial follicles from the right and left ovaries of domestic shorthair cats. The results of this study are to provide useful data for electron microscopists, histologists, and professionals in the area of animal reproduction, and to increase the knowledge of reproduction biology on the domestic shorthair cats.

We identified the intra-individual sides and age differences in primordial follicles, as well as estimated the population morphometrically and ultrastructurally. In humans, the follicle quantity and quality decline with age by atresia. In the present study, we aimed to describe the quantity and quality of the primordial-follicle pool through a morphometric and ultrastructure investigation. We anticipate our statistical study to determine the relationship between primordial follicles in relation to the age of the cat and between its left and right ovary. In addition, another objective was to determine the expression of selected estrogen-dependent genes in domestic shorthair cat ovaries and differential expression of these genes in the left- and right-side ovaries.

## 2. Materials and methods

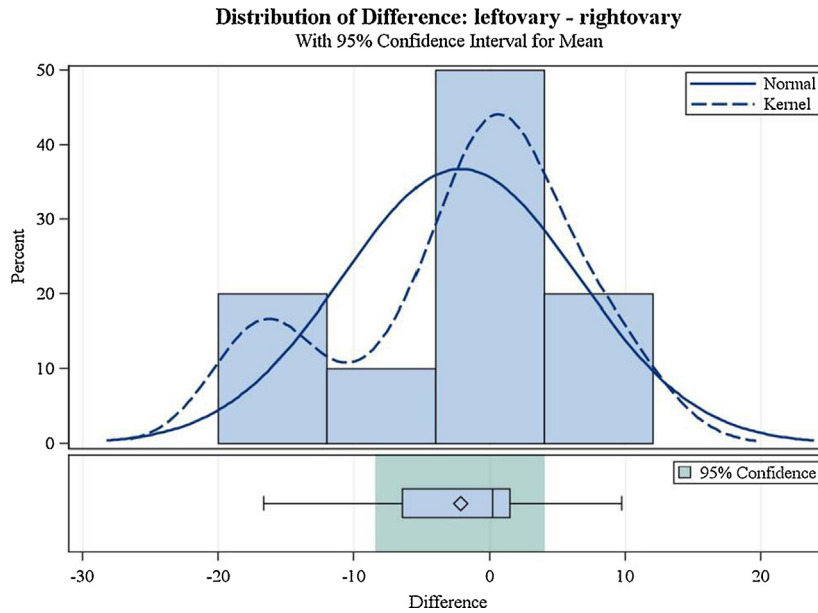
For the histological and ultrastructural studies, ovaries were obtained from 10 domestic shorthair cats of ages 5–24 months. These cats were examined health-wise, and then an ovariohysterectomy was conducted by the Louisiana veterinary clinicians at the College of Veterinary Medicine, Louisiana State University. Upon ovariohysterectomy, the ovaries were removed, measured, sliced, and immediately placed in 10% buffered formalin. They were later processed and stained with hematoxylin and eosin, and were viewed and examined through a light microscope.

Small pieces of each ovary prior to fixing in buffered formalin were minced into 1-mm<sup>2</sup> pieces in primary fixative (2% paraformaldehyde, 2.5% glutaraldehyde, 0.03% CaCl<sub>2</sub> in 0.05 M cacodylate buffer, pH 7.4), and then transferred to a fresh portion of the same fixative for 2 hours at room temperature. The samples were then washed three times in 0.1 M cacodylate buffer supplemented with 5% sucrose, and then postfixed in 1% osmium tetroxide for 1 hour, washed three times in water, and in-block stained with 2% uranyl acetate in 0.2 M sodium-acetate buffer, pH 3.5. The specimens were dehydrated in an ascending ethanol series and treated with propylene oxide, and embedded in Epon-Araldite. Blocks were sectioned with the Ultramicrotome Leica EM UC7 (Ultramicrotome Leica EM uc7/Fc7-8/09 Leica Mikrosystem, GmbH, Vienna, Austria). Thick sections (0.5–1 μm) were stained with methylene blue for primordial-follicle location and orientation. Thin (70–80 nm) sections were impregnated with lead citrate and uranyl acetate for 5 minutes, and examined with the JEOL JEM 1011 microscope (JEOL LTD, 1-2 Musashino, 3-Chome, Akishima, Tokyo 196, Japan) at 80 kV, with the attached Hamamatsu ORCA-HR digital camera (Advanced Microscopy Techniques Corp. 3 Electronics Ave. Danvers, MA 01923, USA). Random ultrastructure digital pictures were taken and saved on USB, and then posted on the computer monitor for morphological study and numerical data collection for analysis.

The light-microscopy study of the primordial follicles of the cats, as well as their ultrastructures, was morphometrically assessed, characterized, and evaluated. The morphometric variables were statistically analyzed to demonstrate correlations between variables in age, side, ovary surface area, and primordial follicles with and without a nucleus. Six-micron-thick sections of the cats' ovaries were stained with hematoxylin and eosin.

The primordial and tertiary follicles were examined by an Olympus light microscope (Olympus light microscope Model CX 31RBSFA T5 SN 9 B03935 Olympus Corporation, Tokyo, Japan, Made in Philippines) using 10× and 20× objectives, and counted using Bluecell Blue Color Handheld Tally Counter 4 Digit Display (Bluecell Sold and shipped by actionfly). The counting was performed by using two random histological sections of each ovary. The primordial-follicle-count procedure was conducted by starting at the ovarian ligament at one side as a landmark, and ended at the ovarian ligament on the other side of the ovary. The surface area of each ovary's histological section used in the count was computed using either  $\pi r_1 r_2$  for elliptical sections, or  $\pi r^2$  for circular sections, and subsequently related to its number of follicles. Also, the primordial follicles with a nucleus and without a nucleus were related to each other statistically.

To analyze gene expression, total RNA was extracted from the left and right ovaries of three cats using Direct-zol RNA kit (Zymo Research Corp., Irvine, CA, USA). The RNA samples were treated with DNase I to remove possible genomic DNA. Total RNA was quantitated with a NanoDrop spectrophotometer (Wilmington, DE, USA). A total RNA of 1 μg was reverse transcribed into the complementary DNA. Next, polymerase chain reaction (PCR) was conducted with gene-specific primers to determine



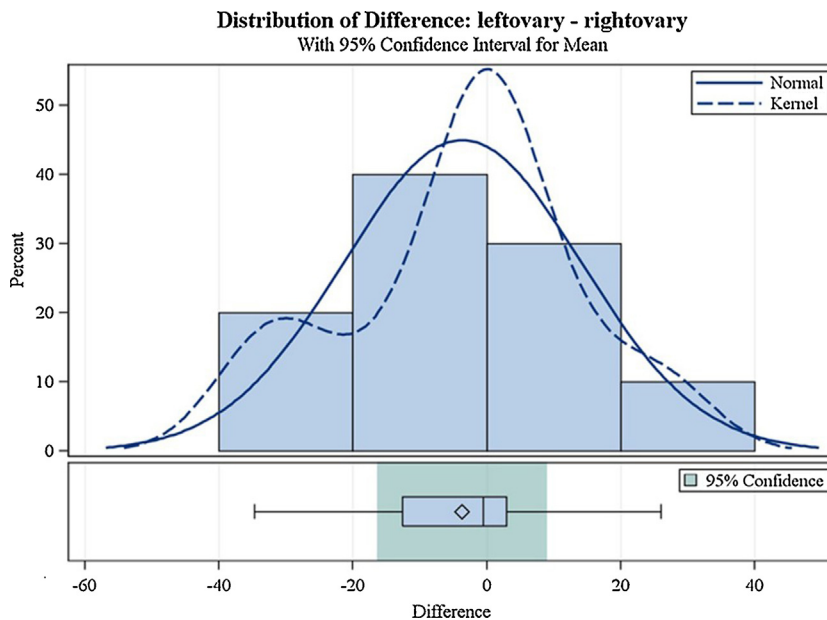
**Figure 1.** No difference in the distribution for the average follicles with nucleus per surface area between the left ovary and the right ovary.

the expression of five estrogen-dependent genes, including blood-vessel epicardial substance, Claudine 11, WAP four-disulfide core domain protein 2 (Wfdc2), transmembrane protein 45b, and complement component 3. The house-keeping gene actin was used as endogenous control in the reverse transcription-PCR analysis.

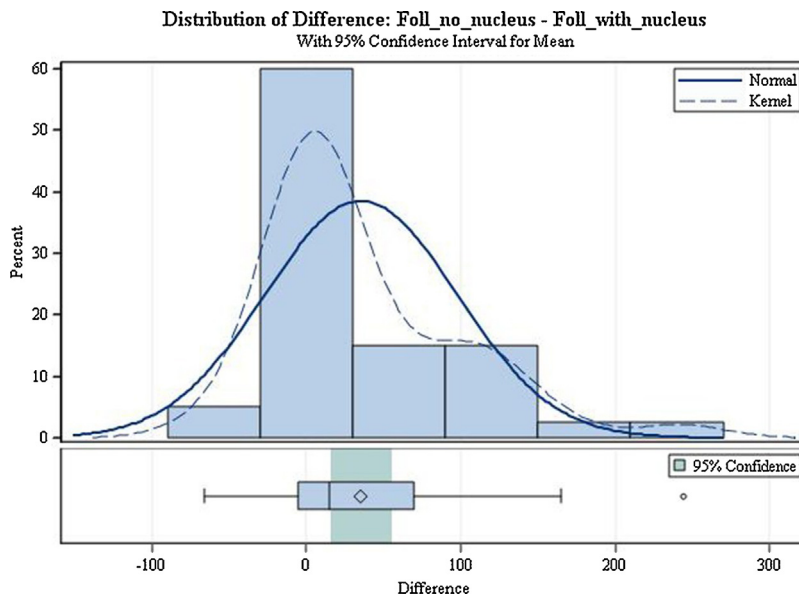
**3. Statistical methodology**

All data were analyzed with SAS (version 9.4; SAS Institute, Cary, NC, USA). The initial analysis was a comparison

of the left and right ovaries with regard to the average follicle counts, both with and without nuclei, in a mixed-effects model. The cats were included as a random effect, and age was used as a covariate in the model. Since ovary side and age were nonsignificant, and since the differences between the type of follicle were not normally distributed, the data were reanalyzed as a Wilcoxon signed-rank test (blocking on animal) to compare follicles without nuclei to nucleated follicles. All differences were considered significant at  $p \leq 0.05$ . (Figures 1–3).



**Figure 2.** No difference in the distribution for the total follicles per surface area between the left ovary and the right ovary.

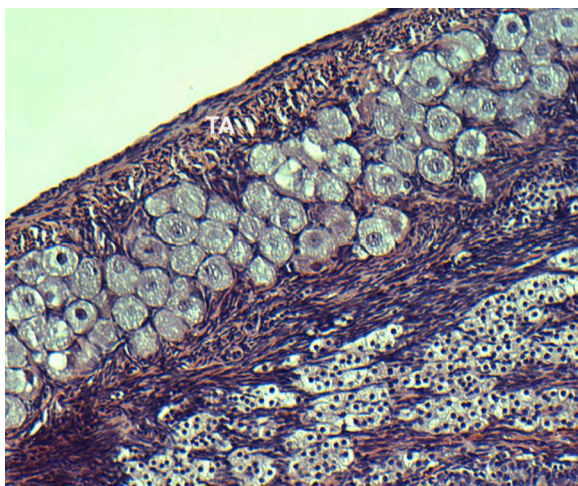


**Figure 3.** A significant difference in the distribution for the follicles with nucleus and the follicles without nucleus. Foll = follicle.

## 4. Results

### 4.1. Light microscopy

The primordial follicles contained oocyte surrounded by a single layer of flattened granulosa cells (Figure 4). The total numbers of 10 cats' left and right ovaries' primordial follicles and tertiary follicles were counted in this study (Tables 1 and 2). The two total numbers of the primordial follicles with and without nuclei were 15,092, and with nuclei only were 6842. The average of the total number of two counts with and without nuclei was 7546, while the average of primordial follicles with nuclei was 3421.



**Figure 4.** Histological section of the cat ovary. It shows crowded primordial follicles under the ovary's tunica albuginea. The location of their nuclei is central, and some are eccentric. Stained with hematoxylin and eosin; 100 $\times$ .

The left ovaries of the 10 cats contained 2601 primordial follicles, and their right ovaries contained 2028 primordial follicles. The right ovary of a 5-month-old cat had a higher number of primordial follicles in the right ovary than in the left ovary. The statistical analysis shows no difference in the distribution for the average follicles with nuclei per surface area between the left and right ovaries (Figure 1). There is no difference in the distribution for the total follicles with nuclei per surface area between the left and right ovaries (Figure 2). There was a difference in the distribution for the total follicles with a nucleus and the total follicles without a nucleus per surface area between the left ovary and the right ovary (Figure 3). The primordial follicles were overcrowded in a large nest format at the periphery of the ovary under the tunica albuginea (Figure 4). Some of these primordial follicles were arranged in a single-or double-row arrangement under the tunica albuginea. In the primordial follicles, the oocytes were surrounded by a single layer of flattened granulosa cells (Figures 4 and 5). The nuclei of some primordial follicles were off-center with some centrally located nuclei. There were some nested or grouped primordial follicles. Simple squamous granulosa cells surrounded each primordial follicle. The number of squamous granulosa cells was between 4 and 10. The primordial follicles varied in size in histological sections with nuclei and without nuclei. Some primordial follicles shared their ooplasm with neighboring primordial follicles, causing two or three nuclei to share the same ooplasm forming a giant primordial follicle (Figure 5).

The number of the primordial follicles with nuclei was more than the number of primordial follicles without nuclei. The highest number of primordial follicles was 694 in the right ovary of an 8-month-old cat. The lowest number of primordial follicles was in the ovary sections of a 2-year-old cat. The highest number of tertiary follicles was in the ovaries of the 2-year-old cat.

**Table 1**

Follicular count and surface areas of the right and left ovarian sections of domestic shorthair cats.

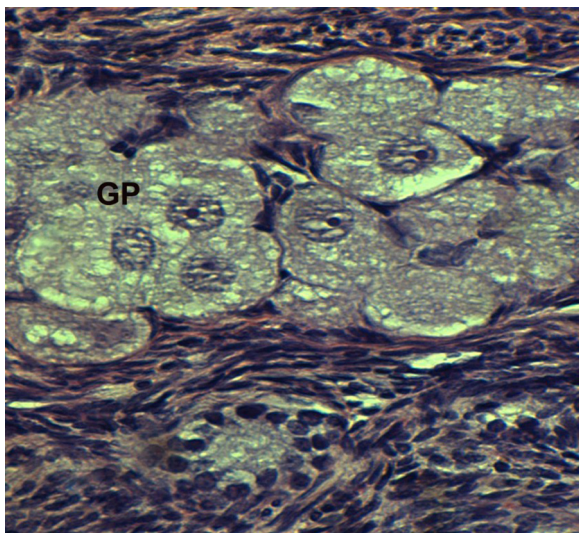
Cat	Ovary	All primordial follicles		Primordial with nucleus		Tertiary follicles		Surface area (mm <sup>2</sup> )	
		Count 1	Count 2	Count 1	Count 2	Count 1	Count 2	Count 1	Count 2
1	Right	198	223	93	112	4	3	22	16.49
1	Left	204	228	102	109	4	5	11	14.14
2	Right	193	554	107	235	2	4	14.14	14.14
2	Left	693	723	292	296	3	3	11.78	15.71
3	Right	273	199	143	102	9	7	18.85	7.85
3	Left	200	147	109	77	10	9	28.27	19.63
4	Right	582	598	247	271	5	7	19.63	19.63
4	Left	514	643	266	305	6	9	19.63	19.63
5	Right	782	812	330	351	1	5	12.57	7.07
5	Left	694	525	225	180	3	2	19.63	11.78
6	Right	309	210	129	97	7	2	19.63	19.63
6	Left	296	264	85	85	6	8	18.85	15.71
7	Right	335	362	173	198	7	7	14.14	18.85
7	Left	382	506	224	245	7	9	14.14	12.57
8	Right	435	628	212	306	6	4	38.48	25.53
8	Left	501	367	258	177	7	7	20.42	25.53
9	Right	454	358	221	160	2	3	9.62	8.25
9	Left	72	145	39	62	1	2	12.57	9.42
10	Right	115	165	58	73	5	7	9.62	11
10	Left	92	111	39	48	8	3	12.57	5.89

**Table 2**

List of domestic shorthair cats studied, including age, weight, and status.

Cat	Age (mo)	Weight (kg)	Breed	Status of cat
1	12	2.3	DSH	Pregnant
2	8	2.5	DSH	
3	24	3.5	DSH	
4	12	3.5	DSH	
5	8	1.8	DSH	
6	18	3.1	DSH	
7	12	2.6	DSH	Pregnant
8	24	3.4	DSH	
9	18	3.1	DSH	Pyometra
10	5	1.96	Tom kinase	

DSH = domestic shorthair.

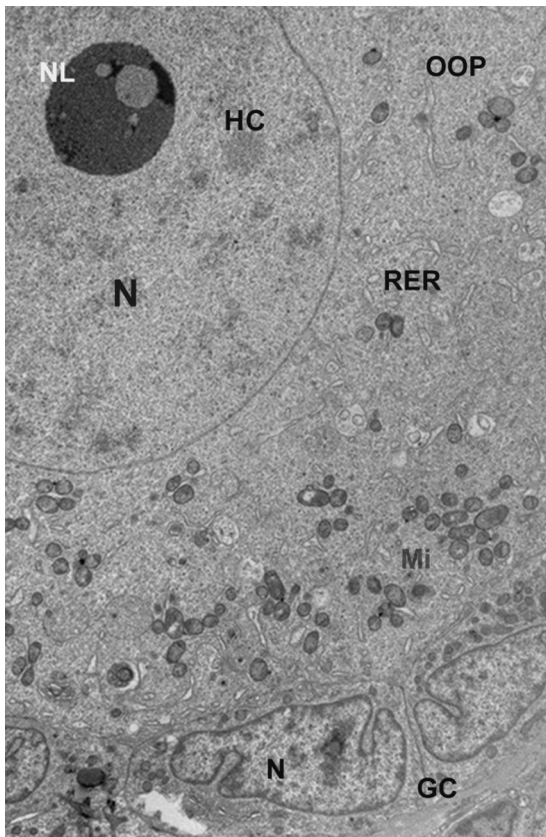


**Figure 5.** Histological section of the cat ovary. It shows several primordial follicles joining their ooplasm with neighboring primordial follicle's ooplasm, forming a giant primordial follicle. Stained with hematoxylin and eosin; 400 $\times$ .

GP = giant primordial.

#### 4.2. Ultrastructure

The quiescent oocytes of the primordial follicles were mainly spherical, with a homogeneous ooplasm and a large rounded nucleus (Figure 6). The nuclear euchromatin and the patches of heterochromatin were uncondensed. The nuclei with an eccentric fibrogranular nucleolus were often observed. The organelles were homogeneously distributed throughout the ooplasm (Figures 6 and 7). The mitochondria were rounded to elongate in shape, the elongated mitochondria being more abundant in some of the primordial follicles (Figure 8). There were two types of round mitochondria, either with low electron density and few peripheral cristae, or with high electron density and many cristae (Figures 8 and 9). Few rough endoplasmic-reticulum profiles were scattered in the ooplasm between the vesicles and the mitochondria (Figures 9 and 10). Well-developed cisternae of the Golgi apparatuses were observed (Figures 7 and 10). Dark and dense granular vesicles were sometimes abundant in number throughout the ooplasm (Figures 7–9). The cellular membranes of the oocyte and granulosa cells were in close connection with the intermingling cytoplasmic microvilli processes (Figures 7 and 9). The microvilli extended between the oolemma of the primordial-follicle oocytes and the plasmalemma of the squamous granulosa cells (Figures 7 and 9). There was also a fuzzy relationship between the microvilli and a fibrous granular gap (Figure 8). Some of the granulosa cells showed cell junctions (Figure 9). The squamous granulosa cells were flattened and elongated, with an obvious large nuclear:cytoplasmic ratio. Their nuclei followed the shape of the cell, and presented narrow nuclear heterochromatin margination and some scattered heterochromatin (Figures 6–10). The granulosa cells presented irregular nuclei, scattered mitochondria, ribosomes, and profiles of rough endoplasmic reticulum. The granulosa cells were always underlined by basal lamina of considerable



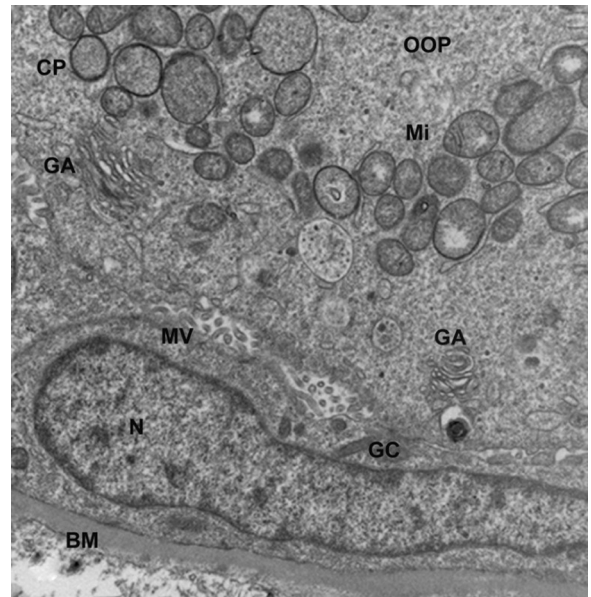
**Figure 6.** Ultrastructure of cat ovary primordial follicle. The ooplasm contains distinct eccentric nucleolus; large nucleus has mainly euchromatin with several patches of light heterochromatin; electron-dense vesicles, rough endoplasmic reticulum, and mostly rounded mitochondria. Bordered by simple squamous granulosa cells, their nuclei contain hetero and euchromatin. Stained with lead citrate and uranyl acetate; 5000 $\times$ . Scale bar: 2  $\mu$ m. GC=granulosa cell; HC=heterochromatin; Mi=mitochondria; N=nucleus; NL=nucleolus; OOP=ooplasm; RER=rough endoplasmic reticulum.

thickness (Figures 7 and 10). Multiple coated pits were scattered in the oocyte oolemma (Figures 8 and 10).

The results of the real-time reverse transcription-PCR showed differential expression of the estrogen-related genes in the left and right ovaries. Of the five genes tested, Claudine 11, transmembrane protein 45b, and complement component 3 were expressed higher in the left ovary than in the right ovary, as seen in Figure 11. However, large variations were observed among those cats, as indicated by the large error bars. In contrast, the expression of blood-vessel epicardial substance and Wfdc2 was higher in the right ovary than in the left ovary. The statistical analysis indicated that the expression of Wfdc2 was significantly different at  $p < 0.05$  (Figure 11).

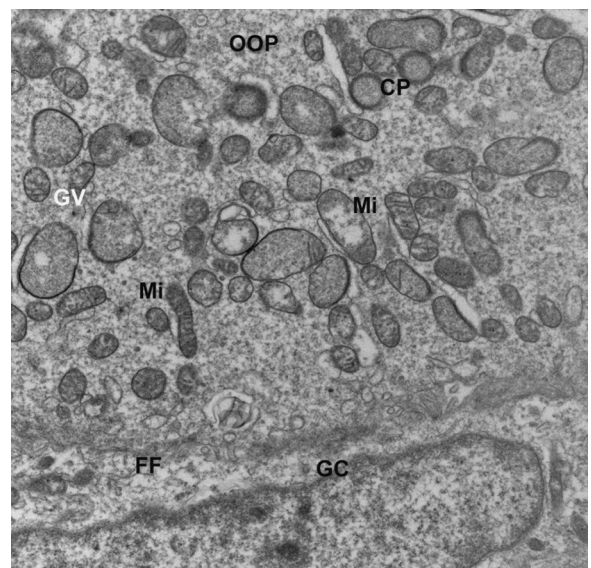
## 5. Discussion

The conclusion of this investigation is to define the ultrastructure and morphology of the domestic shorthair cat primordial follicles. The ultrastructural evaluation is important because early degenerative changes are only



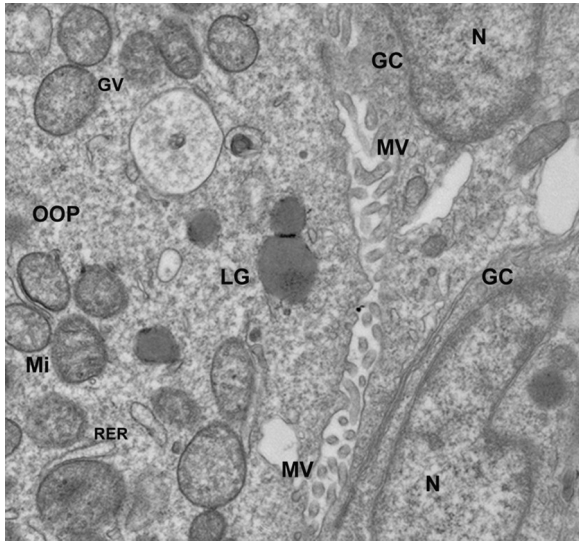
**Figure 7.** Ultrastructure of part of cat ovary primordial follicle. It shows the ooplasm containing various sizes of mitochondria and electron-dense granulated vesicles. Distinct Golgi apparatus. Cytoplasmic microvilli from both the granulosa plasmalemma and the oocyte oolemma. Granulosa-cell nucleus contains both heterochromatin and euchromatin. Distinct thick basement membrane under the granulosa cell. Stained with lead citrate and uranyl acetate; 15,000 $\times$ . Scale bar: 500 nm.

BM=basement membrane; GA=Golgi apparatus; GC=granulosa cell; GV=granulated vesicle; Mi=mitochondria; MV=microvilli; N=nucleus; OOP=ooplasm.



**Figure 8.** Ultrastructure of part of the cat ovary primordial-follicle ooplasm. It shows various sizes of elongated mitochondria, various granulated vesicles, and coated pits. Irregular oolemma border studded with small vesicles faces the granulosa cell and fused with the granulosa plasmalemma in a fussy fibrous format. Stained with lead citrate and uranyl acetate; 15,000 $\times$ . Scale bar: 500 nm.

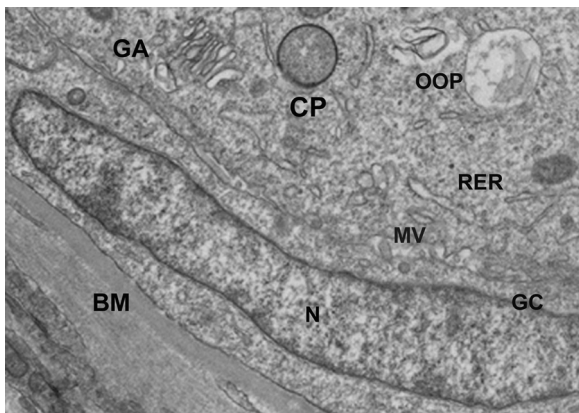
CP=coated pit; FF=fussy fibrous; GC=granulosa cell; GV=granulated vesicle; Mi=mitochondria; OOP=ooplasm.



**Figure 9.** Ultrastructure of part of the cat ovary primordial-follicle ooplasm. It shows the oolemma facing granulosa-cell plasmalemma in intermingled microvilli, from both. The ooplasm contains various sizes of granulated vesicles, mitochondria, rough endoplasmic reticulum, and lipid globules. The granulosa-cell nuclei have both heterochromatin and euchromatin. Stained with lead citrate and uranyl acetate; 15,000 $\times$ . Scale bar: 500 nm.

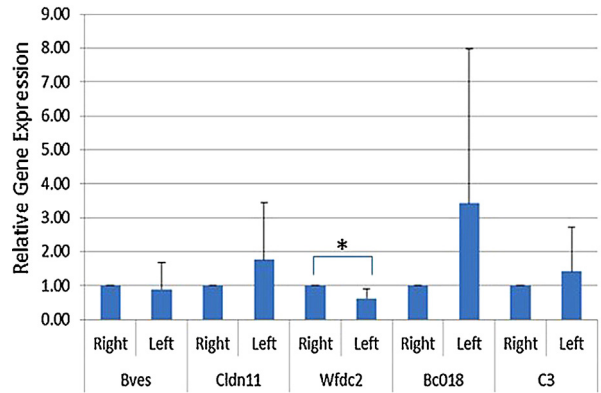
GC=granulosa cell; GV=granulated vesicle; LG=lipid globule; Mi=mitochondria; MV=microvilli; N=nucleus; OOP=ooplasm; RER=rough endoplasmic reticulum.

detected by an electron microscope [12,13]. Early degenerative changes are not detectable by a light microscope's limited resolution power. The primordial follicles are the so-called resting follicles that constitute the follicular reserve of the fertility potential of a female [24]. In humans



**Figure 10.** Ultrastructure of part of the cat ovary primordial-follicle ooplasm. It shows the oolemma facing granulosa-cell plasmalemma fused at various places and several intermingled microvilli from both. The ooplasm contains granular material, large vacuole, rough-endoplasmic-reticulum profiles, coated pit, and Golgi apparatus. The squamous granulosa-cell nucleus has both heterochromatin and euchromatin. It is underlined by a thick basement membrane. Stained with lead citrate and uranyl acetate; 15,000 $\times$ . Scale bar: 500  $\mu$ m.

BM=basement membrane; CP=coated pit; GA=Golgi apparatus; GC=granulosa cell; MV=microvilli; N=nucleus; OOP=ooplasm; RER=rough endoplasmic reticulum.



**Figure 11.** Differential expression of estrogen-related genes in the left and right cat ovaries, as determined by real-time reverse transcription–polymerase chain reaction.

\* Significantly different at  $p < 0.05$ .

Bc018 = transmembrane protein 45b; Bves = blood-vessel epicardial substance; Cldn11 = Claudine 11; C3 = complement component 3; Wfdc2 = WAP four-disulfide core domain protein 2.

and animals, the primordial-follicle formation is initiated during fetal life and is completed at birth. Before birth, some primordial follicles leave the resting pool and are continuously formed until the primordial pool is exhausted at menopause [25]. The factors that control the onset of primordial-follicle growth are unknown [7].

The histology of the current study showed that the primordial follicles were located under the tunica albuginea of the periphery of the ovary, and forming crowded nests of single or double or more lines. Some areas under the tunica albuginea lacked or showed several scattered primordial follicles. A single layer of epithelial cells surrounded each of the primordial follicles. The single layers of granulosa cells in this study were all flattened squamous. They are flattened or flattened cuboidal in the buffalo primordial follicles [26]. The nuclei of the granulosa cells in the examined cat primordial follicles were irregular with deep indentions or fissures containing patches and a narrow rim of heterochromatin, which was also reported in porcine [11]. The cats' primordial follicles in this study varied in sizes, and some shared their ooplasm with the ooplasm of two or three neighboring primordial follicles. This has not yet been reported in the literature.

One or two nuclei were frequently observed in bovine primordial follicles [27]. Only one nucleus was seen in the majority of the examined domestic shorthair cats' primordial follicles in this study. Some of these minimum ultrastructural and morphological criteria could be related to quiescent primordial follicles housing the quiescent oocyte. The presence of few mitochondria in the domestic shorthair cats' primordial follicles in this study is evidence of resting primordial follicles. We anticipate that the few mitochondria indicate less amount of adenosine triphosphate being produced or needed. All the primordial follicles were surrounded by a layer of thick basal lamina around the granulosa cells. This thick basal lamina controls and limits the nutrient diffusion needed by inactive quiescent oocyte. This might be the reason that the granulosa cells at this stage contain only small numbers of organelles. This

was also reported in sheep and cattle ovaries [28]. Based on our evaluation of a total of 23,934 primordial follicles and 209 tertiary follicles, the largest number of primordial follicles was in the 5-month-old cat. This was anticipated in the ovaries of the youngest cat examined in this study. It was reported that some of the primordial follicles are surrounded by cuboidal granulosa cells in porcine [11]. The primordial follicles in the examined domestic shorthair cats were surrounded only by simple squamous granulosa cells. The primordial follicles examined in this study were surrounded by 4–10 flattened squamous granulosa cells. This is different from the five to eight in bovine [16], six to eight in camels [20], and four to eight in buffalo [26]. The examined ovaries showed one layer of flattened granulosa cells, which was also reported in cats as one layer of flattened or flattened/cuboidal granulosa cells [5]. None of the primordial follicles in this study showed any amount of zona pellucida, which was reported to be present in sheep [29]. The primordial-follicle nuclei in the examined cats varied between central and eccentric in location. According to the current literature, they are central in bovine [30], and located peripherally in pig oocytes [31]. The organelle locations in the domestic shorthair cats' primordial follicles' oocyte were peripheral. They are pronuclear in the pig primordial follicles [31], and they are all over in bovine [32]. The examined primordial follicles showed microvilli extending from the oocyte oolema and the plasmalemma of the flat granulosa cells, thus filling the gap between them. It has been reported that a limited number of microvilli are present at the interface of the oocyte and pregranulosa cells of bovine [27] and sheep [28], humans [33,34], rats [35], and guinea pigs [36]. Microvilli were abundant in the current study, and extended between the oolemma of the primordial-follicle oocyte and the plasmalemma of the granulosa cells' microvilli, which was also reported in the bovine primordial follicles [16].

The scarce mitochondria are consistent with primordial follicles containing a quiescent oocyte that does not require a large amount of energy [5]. The ultrastructure and morphology of the granulosa cells in this study were simple squamous epithelium. Our results were not in line with the statement that elongated mitochondria are mostly observed in secondary follicles [16,19,37]. Our findings are in agreement with previous reports of round and elongated mitochondria in queens [5]. Similar observations were described in buffalo prenatal follicles [26]. The basal lamina of the examined primordial follicles showed considerable thickness, which was not reported for other species in the literature. We presume our basement observation is an expected evidence of resting primordial-follicle status, and the thick basal lamina is anticipated to limit nutrition by diffusion. In some areas, the spaces between the granulosa cells and the oocytes in this study were empty, which was reported in buffalo ovaries [26].

Studies of the female gamete formation are an important subject in reproduction biology. The ovary is a critical organ responsible for female gamete production. The ovary is often found in pairs as part of the vertebrate female reproductive system. Some studies revealed that the ovulation from the two ovaries is not the same. For example, the right-sided ovulation was reported to favor pregnancy

more than the left-sided ovulation in humans [38]. However, what causes the difference of ovulation in the two ovaries is not fully understood. In this study, we found that the two ovaries differentially express estrogen-dependent genes. Because estrogen is an important female hormone, the differential expression of the estrogen-dependent genes in the two ovaries may explain the difference in ovulation seen in the left and right ovaries.

## 6. Conclusion

Primordial follicles are not evenly distributed under the ovaries' tunica albuginea. They varied from crowded nests to scattered lines of follicles to none. They varied in size, and some shared their ooplasm with neighboring primordial follicles, forming a giant primordial follicle with three nuclei. Each primordial follicle was surrounded by 4–10 granulosa cells. The ultrastructure of the primordial follicles showed centrally and eccentrically located nuclei with mainly euchromatin and distinct dark nucleoli. The subcellular organelles were mainly vesicles of various densities. Round to multiple elongated mitochondria, ribosomes, rough endoplasmic reticulum, coated pits, and well-developed Golgi apparatuses were observed. The granulosa cells' microvilli intermingled with the oocyte's plasmalemma microvilli. The granulosa cells were underlined by thick basal lamina in all of the examined primordial follicles.

Our preliminary study indicated that the right and left ovaries differentially express estrogen-related genes. This is a novel finding, although asymmetrical gene expression in ovaries has been reported in other species [39]. This may partially explain why ovulation from the right and left ovaries has different progeny success rate.

## Conflicts of interest

The authors declare no conflicts of interest.

## Acknowledgments

This research was funded by the Department of Comparative Biomedical Sciences, School of Veterinary Medicine, Louisiana State University, Baton Rouge, LA, USA.

## References

- [1] Wu C, Rui R, Dai J, Zhang C, Ju S, Xie B, et al. Effects of cryopreservation on the developmental competence, ultrastructure and cytoskeletal structure of porcine oocytes. *Mol Reprod Dev* 2006;73:1454–62.
- [2] Coticchio G, Bonu MA, Borini A, Flamigni C. Oocyte cryopreservation: a biological perspective. *Eur J Obstet Gynecol Reprod Biol* 2004;115(Suppl 1):S2–7.
- [3] Carroll J, Depypere H, Matthews CD. Freeze–thaw-induced changes of the zona pellucida explains decreased rates of fertilization in frozen–thawed mouse oocytes. *J Reprod Fertil* 1990;90(2):547–53.
- [4] Hyttel P, Vajta G, Callesen H. Vitrification of bovine oocytes with the open pulled straw method: ultrastructural consequences. *Mol Reprod Dev* 2000;56(1):80–8.
- [5] Carrizo Jr OA, Marinho AP, Campos AA, Amorim CA, Bao SN, Lucci CM. Morphometry, estimation and ultrastructure of ovarian preantral follicle population in queens. *Cells Tissues Organs* 2010;191(2):152–60.
- [6] Jewgenow K, Göritz F. The recovery of preantral follicles from ovaries of domestic cats and their characterization before and after culture. *Anim Reprod Sci* 1995;39:285–97.



- [7] Wandji SA, Srsen V, Voss AK, Eppig JJ, Fortune JE. Initiation *in vitro* of growth of bovine primordial follicles. *Biol Reprod* 1996;55(5):942–8.
- [8] Lucci CM, Kacinskis MA, Lopes LH, Rumpf R, Bao SN. Effect of different cryoprotectants on the structural preservation of follicles in frozen zebu bovine (*Bos indicus*) ovarian tissue. *Theriogenology* 2004;61(6):1101–4.
- [9] Lima AK, Silva AR, Santos RR, Sales DM, Evangelista AF, Figueiredo JR, et al. Cryopreservation of preantral ovarian follicles *in situ* from domestic cats (*Felis catus*) using different cryoprotective agents. *Theriogenology* 2006;66(6–7):1664–6.
- [10] Santos RR, Tharasanit T, Van Haeften T, Figueiredo JR, Silva JR, Van den Hurk R. Vitrification of goat preantral follicles enclosed in ovarian tissue by using conventional and solid-surface vitrification methods. *Cell Tissue Res* 2007;327(1):167–76.
- [11] Silva RC, Bao SN, Jivago JL, Lucci CM. Ultrastructural characterization of porcine oocytes and adjacent follicular cells during follicle development: lipid component evolution. *Theriogenology* 2011;76(9):1647–57.
- [12] Silva JR, Bao SN, Lucci CM, Carvalho FC, Andrade ER, Ferreira MA, et al. Morphological and ultrastructural changes occurring during degeneration of goat preantral follicles preserved *in vitro*. *Anim Reprod Sci* 2001;66(3–4):209–23.
- [13] Carvalho FC, Lucci CM, Silva JR, Andrade ER, Bao SN, Figueiredo JR. Effect of Braun–Collins and saline solutions at different temperatures and incubation times on the quality of goat preantral follicles preserved *in situ*. *Anim Reprod Sci* 2001;66(3–4):195–208.
- [14] Zhou GB, Li N. Cryopreservation of porcine oocytes: recent advances. *Mol Hum Reprod* 2009;15(5):279–85.
- [15] De Loos F, van Maurik P, van Beneden T, Kruij TA. Structural aspects of bovine oocyte maturation *in vitro*. *Mol Reprod Dev* 1992;31(3):208–14.
- [16] Fair T, Hulshof SC, Hyttel P, Greve T, Boland M. Oocyte ultrastructure in bovine primordial to early tertiary follicles. *Anat Embryol (Berl)* 1997;195(4):327–36.
- [17] Brand A, de Jong WH. Qualitative and quantitative micromorphological investigations of the tertiary follicle population during the oestrous cycle in sheep. *J Reprod Fertil* 1973;33(3):431–9.
- [18] Cran DG, Moor RM, Hay MF. Fine structure of the sheep oocyte during antral follicle development. *J Reprod Fertil* 1980;59(1):125–32.
- [19] Lucci CM, Silva RV, Carvalho CA, Figueiredo R, Bao N. Light microscopical and ultrastructural characterization of goat preantral follicles. *Small Rumin Res* 2001;41(1):61–9.
- [20] Davoodian N, Mesbah F, Kafi M. Oocyte ultrastructural characteristics in camel (*Camelus dromedarius*) primordial to large antral follicles. *Anat Histol Embryol* 2011;40(2):120–7.
- [21] Shaw JM, Oranratnachai A, Trounson AO. Fundamental cryobiology of mammalian oocytes and ovarian tissue. *Theriogenology* 2000;53(1):59–72.
- [22] Gutierrez CG, Ralph JH, Telfer EE, Wilmut I, Webb R. Growth and antrum formation of bovine preantral follicles in long-term culture *in vitro*. *Biol Reprod* 2000;62(5):1322–8.
- [23] Hashimoto S, Ohsumi K, Tsuji Y, Harauma N, Miyata Y, Fukuda A, et al. Growing porcine oocyte–granulosa cell complexes acquired meiotic competence during *in vitro* culture. *J Reprod Dev* 2007;53(2):379–84.
- [24] Westergaard CG, Byskov AG, Andersen CY. Morphometric characteristics of the primordial to primary follicle transition in the human ovary in relation to age. *Hum Reprod* 2007;22(8):2225–31.
- [25] Peters H, Byskov AG, Himelstein-Braw R, Faber M. Follicular growth: the basic event in the mouse and human ovary. *J Reprod Fertil* 1975;45(3):559–66.
- [26] Mondadori RG. Folliculogenesis nuclear and cytoplasmatic maturation of buffalo oocytes—a structural analysis [PhD thesis]. Brasilia: University of Brasilia; 2012, 110.
- [27] Van Wezel IL, Rodgers RJ. Morphological characterization of bovine primordial follicles and their environment *in vivo*. *Biol Reprod* 1996;55(5):1003–11.
- [28] Russe I. Oogenesis in cattle and sheep. *Bibl Anat* 1983;24:77–92.
- [29] Matos MH, Andrade ER, Lucci CM, Bao SN, Silva JR, Santos RR, et al. Morphological and ultrastructural analysis of sheep primordial follicles preserved in 0.9% saline solution and TCM 199. *Theriogenology* 2004;62(1–2):65–80.
- [30] Assey RJ, Hyttel P, Greve T, Purwantara B. Oocyte morphology in dominant and subordinate follicles. *Mol Reprod Dev* 1994;37(3):335–44.
- [31] Christmann L, Jung T, Moor RM. MPF components and meiotic competence in growing pig oocytes. *Mol Reprod Dev* 1994;38(1):85–90.
- [32] Dunbar BS, Avery S, Lee V, Prasad S, Schwahn D, Schwoebel E, et al. The mammalian zona pellucida: its biochemistry, immunochemistry, molecular biology, and developmental expression. *Reprod Fertil Dev* 1994;6(3):331–47.
- [33] Baca M, Zamboni L. The fine structure of human follicular oocytes. *J Ultrastruct Res* 1967;19(3):354–81.
- [34] Makabe S, Naguro T, Nottola SA, Pereda J, Motta PM. Migration of germ cells, development of the ovary, and folliculogenesis. In: Familiari G, Makabe S, Motta PM, editors. *Ultrastructure of the ovary*. Kluwer Academic Publishers; Springer US; 1991. p. 1–27.
- [35] Odor DL. Electron microscopic studies on ovarian oocytes and unfertilized tubal ova in the rat. *J Biophys Biochem Cytol* 1960;7:567–74.
- [36] Blanchette EJ. A study of the fine structure of the rabbit primary oocyte. *J Ultrastructure Res* 1961;5:349–63.
- [37] Kacinskis MA, Lucci CM, Luque MC, Bao SN. Morphometric and ultrastructural characterization of *Bos indicus* preantral follicles. *Anim Reprod Sci* 2005;87(1–2):45–57.
- [38] Fukuda M, Fukuda K, Andersen CY, Byskov AG. Right-sided ovulation favours pregnancy more than left-sided ovulation. *Hum Reprod* 2000 Sep;15(9):1921–6.
- [39] Carre GA, Couty I, Hennequet-Antier C, Govoroun MS. Gene expression profiling reveals new potential players of gonad differentiation in the chicken embryo. *PLoS One* 2011;6(9):12.