

Hyperreactio luteinalis and hypothyroidism: A case report

Alejandro Pérez Chaverri^{a,c,*}, Beatriz Elizabeth Aguilar Solís^a,
Félix Domínguez Paulín^a, José Eugenio Guerra Cárdenas^b

^a Department of Obstetrics and Gynecology, Universidad Autónoma de Tamaulipas, Tampico, Tamaulipas, Mexico

^b Research Committee, "Dr. Alberto Romo Caballero" School of Medicine, Universidad Autónoma de Tamaulipas, Tampico, Tamaulipas, Mexico

^c Department of Obstetrics and Gynecology, "Dr. Carlos Canseco" General Hospital of Tampico, Tampico, Tamaulipas, Mexico

ARTICLE INFO

Keywords:

Hyperreactio Luteinalis
Hypothyroidism
Pregnancy

ABSTRACT

We report a case of hyperreactio luteinalis (HL) and hypothyroidism diagnosed at 13 weeks of pregnancy. A 29-year-old woman with a spontaneous 13-week singleton pregnancy presented with hirsutism and a pelvic mass. Ultrasound showed a viable pregnancy compatible with the gestational age and multiple cystic lesions on both ovaries. Her TSH levels were markedly elevated and diagnostic of hypothyroidism, for which she was treated. Two days after presentation, she had a spontaneous abortion. The products of conception were histologically normal. Follow-up at 3 months showed resolution of the ovarian cysts, and the previously elevated androgen levels were in the normal range. Hyperreactio luteinalis was diagnosed. Her elevated TSH levels may have contributed to hyperreactio luteinalis through the activation of the hCG receptor.

© 2018 The Authors. Published by Elsevier B.V. This is an open access article under the CC BY-NC-ND license (<http://creativecommons.org/licenses/by-nc-nd/4.0/>).

1. Introduction

Hyperreactio luteinalis (HL) is a rare condition characterized by the enlargement of both ovaries due to the formation of a benign complex of theca lutein cysts, which may vary in size, with the presence of interstitial edema [1]. Women affected by this condition may present with a variety of symptoms, including hirsutism, acne, alopecia, clitoromegaly, and deepening of the voice. It can be diagnosed at any time during pregnancy [2]. It is diagnosed during the third trimester in 54% of cases, in 16% during childbirth, and in 16% during the first trimester. Approximately 37% of cases are diagnosed during cesarean section [1]. The average age at diagnosis is 28 years [3]. Overall, 78% of cases present in single pregnancies and 22% in multiple pregnancies [3].

Ovarian hyperstimulation syndrome (OHSS) is a potentially fatal disorder associated with fertility treatments [1]. Presentation is similar to HL, but the ovarian expansion with fluid extravasation leading to ascites and pleural effusion is typically faster with OHSS [1]. In both conditions the bilateral cluster of giant simple or hemorrhagic luteinized ovarian cysts with minimal stroma are seen, giving a 'spoke wheel' appearance [4].

Diagnostic ultrasound allows identification of the "spoke-wheel" pattern with many thin-walled small simple cysts. Combined with

biochemical markers and clinical data, it helps to differentiate HL from other types of ovarian tumors [3].

We report a 29-year-old patient in the first trimester of pregnancy with bilateral adnexal masses occupying the entire abdomen. The uniqueness of this case is that she was also hypothyroid.

2. Clinical Case

A 29-year-old woman G3P1011 presented at 13.5 weeks of gestation. She was referred to a local clinic due to a uterine size inconsistent with the gestational age. She had no significant personal or family medical history. She complained of constipation and light pain in her lower abdominal area. During physical examination, her uterine fundus could not be evaluated due the presence of a mass occupying the whole abdominal area. She was also hirsute, with android-type hair distribution. Ultrasound examination revealed a normal singleton pregnancy corresponding to the gestational age by amenorrhea and multiple cystic lesions on the ovaries (Fig. 1). The patient was hospitalized and her hormonal and biochemical profiles were assessed. Tumor markers, cancer antigen 125 (CA-125), and alpha-fetoprotein were normal. Evaluation of β -hCG revealed levels of 55,654 UI/mL, corresponding with the gestational age. Her serum hormonal profile revealed free testosterone and estradiol levels that were markedly elevated and TSH > 100 mU/mL (Table 1).

Two days after admission, she had a spontaneous incomplete abortion. The patient underwent curettage; histopathological examination of the products of conception were normal and ruled out gestational trophoblastic disease. A chest X-ray, performed because of concerns

* Corresponding author at: Department of Obstetrics and Gynecology, Universidad Autónoma de Tamaulipas, Tampico, Tamaulipas, Mexico.
E-mail address: peca8907@gmail.com (A.P. Chaverri).

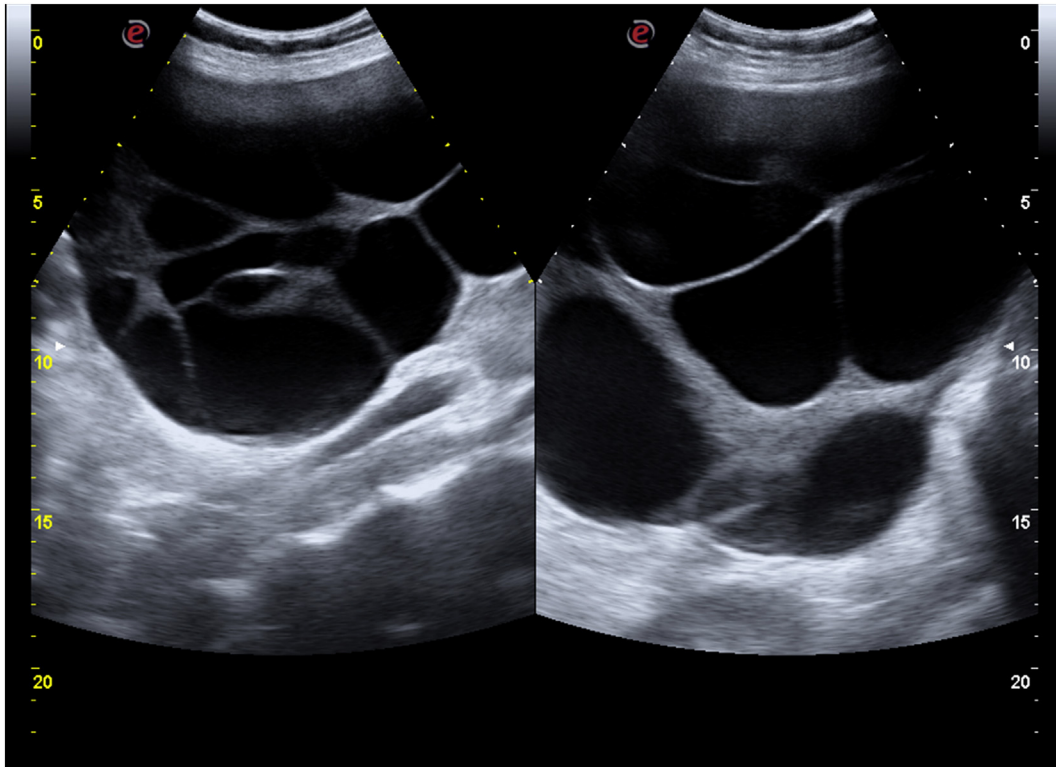


Fig. 1. Transabdominal ultrasound at 13.5 weeks of gestation of the right ovary (a) and left ovary (b). Multiple theca lutein cysts forming an apparent “spoke wheel”.

about OHSS, was normal. Computerized axial tomography was conducted to study the adnexal masses to establish a diagnosis. It revealed a right ovary measuring 125 mm × 161 mm × 156 mm, a left ovary measuring 143 mm × 181 mm × 216 mm, and a uterus without abnormalities (Fig. 2). The diagnosis of HL during pregnancy and primary hypothyroidism was made and treatment with levothyroxine was initiated. Follow-up was performed at 6, 8, and 12 weeks to check TSH levels: levothyroxine dose was gradually increased until TSH levels were below 2.5 mU/L. Thyroid peroxidase and thyroglobulin antibodies were assessed, and were positive for the latter. Three months after presentation, biochemistry evaluation showed the following levels: β -hCG 6.69 UI/mL, estradiol 38.21 pg/mL, alpha-fetoprotein 1.37 ng/mL, CA-125 1.57 UI/mL, total testosterone 1.21 nmol/L (reference range 0.5 to 2.6), and TSH 1.4 mU/mL. Pelvic ultrasound showed resolution of the cysts on both ovaries.

3. Discussion

The etiology of HL is unknown, but is believed to be related either to increased levels of β -hCG or to an abnormal ovarian response to normal levels [1,5] HL is frequently clinically asymptomatic, although it can cause pain due to rupture, ovarian torsion, or hemorrhage [6]. The incidence of ovarian tumors during pregnancy is 1 in 1000 [7].

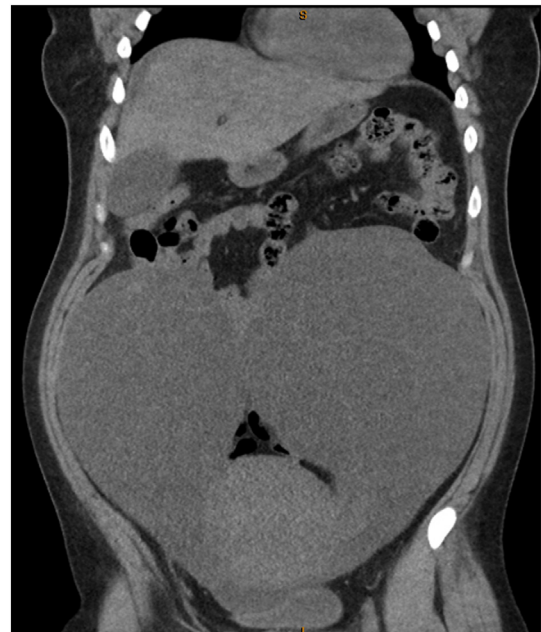

Fig. 2. Computerized axial tomography after uterine curettage. Coronal cut confirming the increase in the size of both ovaries.

Table 1
The patient's test results during hospitalization.

Test	Value	Reference range
Cancer antigen CA-125 (UI/mL)	25.8	0–35
Alpha-fetoprotein (ng/mL)	1.5	<3.0
Human chorionic gonadotrophin (hCG) (UI/mL)	55,654	13,300–254,000 at 13–16 weeks gestation
Basal insulin (UI/mL)	9.3	8.78 ± 3.20
Free testosterone (nmol/L)	41.20	<1.5
Estradiol pg/mL (pg/mL)	7421.9	<50
Total T4 (μ g/dL)	2.07	5.4–11.7
T3 free (pg/mL)	1.94	2.4–4.2
T4 free (ng/dL)	0.13	0.7–1.24
TSH (mU/mL)	>100 μ	0.1–2.5
Thyroglobulin antibody (TgAb) (UI/mL)	49.42	<20
Thyroid peroxidase antibody (TPOAb) (UI/mL)	17.92	<35

When bilateral adnexal masses occur during pregnancy, differentiating between benign and malignant pathologies is key to avoiding unnecessary surgical approaches [3]. A common ultrasound appearance is the formation of a “spoke wheel.” [8].

TSH, FSH, and their receptors have a structural relationship. Extremely high concentrations of TSH in hypothyroidism can be sufficient to cause the activation of FSH receptors, therefore generating effective follicular stimulation [9]. Other data suggest that high levels of TSH can act on FSH receptors and cause gonadal stimulation [10]. The increase of TSH in hypothyroidism can stimulate gonadal cells through LH/hCG [11]. Elevated TSH levels can increase ovarian sensitivity to gonadotrophins [12].

Hypothyroidism is associated with multiple conditions, including abortion. Animal models have shown that hypothyroidism exerts an adverse effect on pregnancy associated with a higher rate of spontaneous abortion [13]. The cause of abortion in this patient may have been associated with hypothyroidism. In addition, the elevated TSH levels may have contributed to the HL.

In conclusion, the natural evolution of HL is by means of postpartum regression. Therefore, treatment should be conservative and surgery avoided.

Contributors

All of the authors contributed equally to the preparation of this case report, and read and approved the final manuscript.

Conflict of Interest

The authors declare that they have no conflicts of interest regarding the publication of this case report.

Funding

No funding was sought or secured in relation to this case report.

Patient Consent

Informed written consent was obtained from the patient.

Provenance and Peer Review

This case report was peer reviewed.

References

- [1] R.A. Foulk, M.C. Martin, G.L. Jerkins, R.K. Laros, Hyperreactio luteinalis differentiated from severe ovarian hyperstimulation syndrome in a spontaneously conceived pregnancy, *Am. J. Obstet. Gynecol.* 176 (1997) 1300–1302.
- [2] S. Angioni, E. Portoghese, F. Milano, G.B. Melis, A.M. Fulghesu, Hirsutism and hyperandrogenism associated with hyperreaction luteinalis in a singleton pregnancy: a case report, *Gynecol. Endocrinol.* 23 (5) (2007 May) 248–251.
- [3] P. Cavoretto, V. Giorgione, C. Sigismondi, G. Mangili, A. Serafini, C. Dallagiovanna, et al., Hyperreactio luteinalis: timely diagnosis minimizes the risk of oophorectomy and alerts clinicians to the associated risk of the placental insufficiency, *Eur. J. Obstet. Gynecol. Reprod. Biol.* 176 (2014 May) 10–16.
- [4] J.A. Schnorr, H. Miller, J.R. Davis, K. Hatch, J. Seeds, Hyperreactioluteinalis associated with pregnancy: a case report and review of the literature, *Am. J. Obstet. Gynecol.* 13 (1996) 95–97.
- [5] K.D. Bradshaw, R. Santos-Ramos, S.C. Rawlins, P.C. MacDonald, C.R. Parker, Endocrine studies in a pregnancy complicated by ovarian theca lutein cysts and hyperreactio luteinalis, *Obstet. Gynecol.* 67 (1986) 66–95.
- [6] M. García-Sánchez, I. González Blanco, J.T. de Gonzalo, Hiperreacción luteínica en el curso de una gestación normal, *Clin. Invest. Ginecol. Obstet.* 28 (2001) 81–83.
- [7] M.A. Bidus, A. Ries, E.F. Magan, J.N. Martin, Markedly elevated beta-hCG levels in a normal singleton gestation with hyperreaction luteinalis, *Obstet. Gynecol.* 99 (5) (2002 May) 958–961 Pt 2.
- [8] C. Amoah, A. Yassin, E. Cockayne, A. Bird, Hyperreactio luteinalis in pregnancy, *Fertil. Steril.* 95 (7) (2011 Jun) 2429.
- [9] J. Shu, L. Xing, L. Zhang, S. Fang, H. Huang, Ignored adult primary hypothyroidism presenting chiefly with persistent ovarian cysts: a need for increased awareness, *Reprod. Biol. Endocrinol.* 9 (Aug 23, 2011) 119.
- [10] J.N. Anasti, M.R. Flack, J. Froehlich, L.M. Nelson, B.C. Nisula, A potential novel mechanism for precocious puberty in juvenile hypothyroidism, *J. Clin. Endocrinol. Metab.* 80 (1) (1995) 276–279.
- [11] H. Hidaka, T. Minegishi, Kohn L. Thyrotropin, Like luteinizing hormone (LH) and chorionic gonadotropin (CG), increases cAMP and inositol phosphate levels in cells with recombinant human LH/CG receptor, *Biochem. Biophys. Res. Commun.* 196 (1) (1993 Oct 15) 187–195.
- [12] O. Dobozy, G. Csaba, G. Hetényi, M. Shahin, Investigation of gonadotropin-thyrotropin overlapping and hormonal imprinting in the rat testis, *Acta Physiol. Hung.* 66 (2) (1985) 169–175.
- [13] J. Sun, C. Hui, T. Xia, M. Xu, D. Deng, F. Pan, et al., Effect of hypothyroidism on the hypothalamic-pituitary-ovarian axis and reproductive function of pregnant rats, *BMC Endocr. Disord.* 18 (2018) 30.