



## Case Report

## Severe microcytosis in a hemoglobin E/B-thalassemia patient with signs of iron deficiency: A case report

Laurensia Goretti<sup>a</sup>, Christophorus Oetama Adiatmaja<sup>a</sup>, Hartono Kahar<sup>b,\*</sup><sup>a</sup> Study Program of Clinical Pathology, Department of Clinical Pathology, Faculty of Medicine, Universitas Airlangga, Surabaya, Indonesia<sup>b</sup> Department of Clinical Pathology, Faculty of Medicine, Universitas Airlangga – Dr Soetomo General Academic Hospital, Surabaya, Indonesia

## ARTICLE INFO

## Keywords:

Anemia  
β-Thalassemia  
Iron deficiency  
Microcytosis

## ABSTRACT

**Background:** β-thalassemia is a hereditary disorder characterized by a decrease in the synthesis of β-globin chains that decreases hemoglobin in erythrocytes, low erythrocyte production, and anemia.**Case presentation:** A 6-year-old girl came with complaints of paleness for one week. Physical examination showed vital signs within normal limits, conjunctival anemia, and hepatomegaly. Investigations: HGB 5.4 g/dL, MCV 44.5 fL, MCH 15.5 pg, MCHC 34.8 g/dL, RDW-CV 29.2%, WBC 4,770/μL, PLT 2,728,000/μL, Serum iron 29 g/dL, TIBC 217 g/dL and transferrin saturation of 13.36%. Peripheral blood smears showed target cells, teardrop cells, ovalocytes, fragmentocytes, cigar cells, and pseudothrombocytosis by automated hematology tools caused by the misinterpretation of small erythrocytes as platelets. Hemoglobin electrophoresis showed a decrease in HbA (4.9%), as well as an increase in HbF (18.3%), HbE (70.5%), and HbA2 (6.3%). The patient was diagnosed with β-thalassemia.**Discussion:** Thalassemia with severe microcytosis suggests possible coexistence with iron deficiency. A complete iron profile examination is required in these patients to ensure appropriate and comprehensive medical management.**Conclusion:** Iron profile examination plays an essential role in the management and diagnosis of β-thalassemia patients.

## 1. Introduction

Microcytic anemia is the most common anemia in children and adults. Microcytic anemia in children is generally caused by iron deficiency and thalassemia, while it is caused by bleeding and chronic disease in adults [1,2]. β-Thalassemia is a hereditary disorder characterized by a decrease in the synthesis of β-globin chains that decreases hemoglobin in erythrocytes, low erythrocyte production, and anemia. β-thalassemia is common in Mediterranean countries, the Middle East, Central Asia, India, South China, Southeast Asia, the north coast of Africa, and South America [3,4].

Hemoglobin E (HbE) is a structural variant of hemoglobin commonly found in Asia. The coexistence of HbE with β-thalassemia, namely HbE-thalassemia, is the most severe manifestation of β-thalassemia in Asia, and it represents 50% of all patients with severe β-thalassemia [5]. A common complication in thalassemia patients is iron overload, so it has long been believed that iron deficiency is not found in thalassemia

patients. Several studies have refuted this claim and proved the presence of iron deficiency in some patients with β-thalassemia [6,7]. Based on this description, we are interested in reporting a child with hemoglobin β-thalassemia who developed severe microcytosis. We write based on surgery case report (SCARE) guideline 2020 [8].

## 2. Case presentation

A 6-year-old girl with complaints of paleness since one week before admission to the hospital. The patient was referred from another hospital with a diagnosis of anemia gravis. The patient's general condition was weak with a GCS of 15, blood pressure of 100/60 mmHg, pulse rate of 102 × /minute, respiratory rate of 32 × /minute, and axillary temperature of 37.1 °C. Bodyweight of 14.5 kg, the height of 110 cm, with an ideal body weight of 18 kg. The patient's body weight percentage was 80% of the perfect body weight. Examination of the head/neck revealed anemia, no icterus, no cyanosis, and no dyspnea. Thoracic investigation

\* Corresponding author. Department of Clinical Pathology, Faculty of Medicine, Universitas Airlangga – Dr. Soetomo General Academic Hospital, Jl. Mayjend Prof Dr. Moestopo No. 6-8, Airlangga, Gubeng, Surabaya, East Java 60286, Indonesia.

E-mail address: [hartono.kahar0322@gmail.com](mailto:hartono.kahar0322@gmail.com) (H. Kahar).

<https://doi.org/10.1016/j.amsu.2022.103826>

Received 20 March 2022; Received in revised form 15 May 2022; Accepted 16 May 2022

Available online 18 May 2022

2049-0801/© 2022 The Authors. Published by Elsevier Ltd on behalf of IJS Publishing Group Ltd. This is an open access article under the CC BY-NC-ND license (<http://creativecommons.org/licenses/by-nc-nd/4.0/>).

revealed a symmetrical chest shape and no chest wall retraction. Single S1 S2 heart sound, no gallops or heart murmurs. Vesicular breath sounds, no crackles, and wheezing. Abdominal examination showed normal bowel sounds, supple, hepatomegaly size of 4 × 3 × 2 cm, and impalpable spleen. Analysis of the extremities revealed palpable fingertips, dryness, and no oedema. There was no family with thalassemia.

Complete blood count showed anemia and thrombocytosis (Table 1). A peripheral blood smear examination revealed thalassemia and pseudothrombocytosis (Fig. 1). Clinical chemistry examination showed a reduction in serum iron, TIBC, and calcium. Hemoglobin electrophoresis examination showed a decrease in HbA and an increase in HbF, HbE, and HbA2 (Fig. 2). Based on the examination result, the patient was diagnosed with β-thalassemia. This patient received fluid therapy during treatment. For the anemia treatment, she has been given iron intake in ferric syrup of 7.5 mL for 8 hours, folic acid tablets of 1 × 5 mg, and vitamin C of 400 mg for 24 hours. It was also planned for 1 × packed red cell (PRC) transfusion of 140 mL with a target Hb of 7 d/gL.

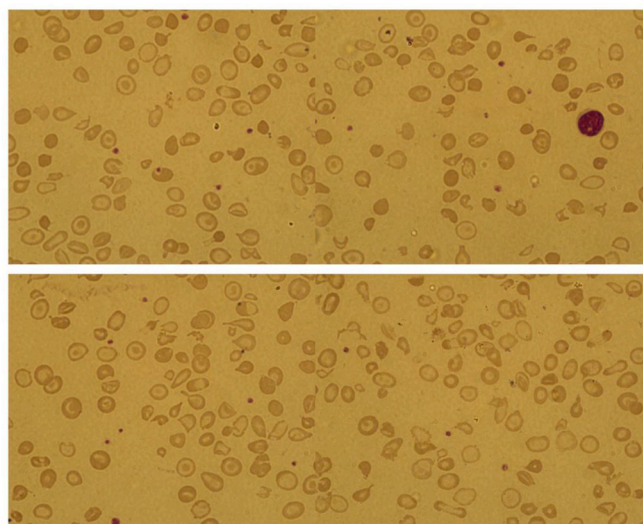
Patient and family are recommended to do a blood examination once a month or if the patient has signs of anemia such as paleness. If Hb shows a decrease, PRC will be carried out again. The uniqueness of our case is -thalassemia with iron deficiency.

### 3. Discussion

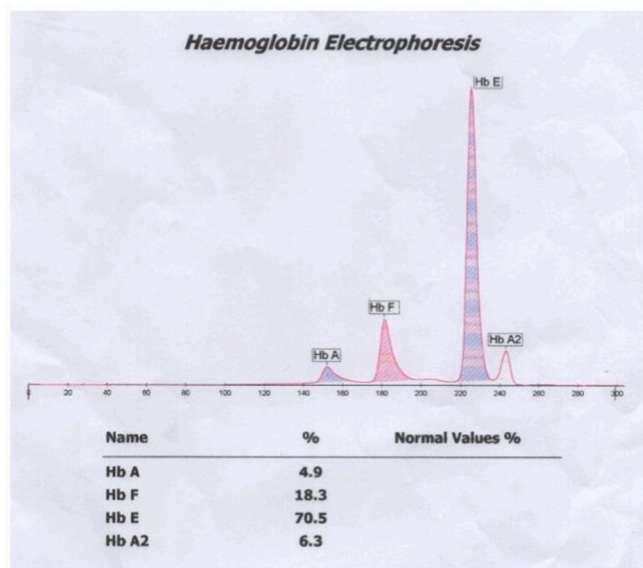
Thalassemia and iron deficiency anemia are the most common causes of microcytic anemia encountered by pediatricians. Differentiating thalassemia from iron deficiency anemia has essential implications because each disease has a different reason, prognosis, and treatment. Many investigators use the hematological index of complete blood counts to differentiate thalassemia from iron deficiency anemia. These indices include Mentzer index, RDWI, Shine and Lalm, Srivastava, Green and King, Sirdah, Ehsani, England and Fraser, Ricerca, Mean Density of Hb/Liter of blood (MDHL), and Mean Cell Hemoglobin Density (MCHD). The Mentzer index gives the best performance in differentiating thalassemia from iron deficiency anemia [9]. This conclusion is supported by previous studies, stating that the Mentzer index was calculated by the

**Table 1**  
Hematology laboratory results.

Examination	First day	Second day
<b>Hematology</b>		
Hemoglobin (g/dL)	5.4	4.8
Red blood count (10 <sup>6</sup> /μL)	3.48	3.08
Hematocrit (%)	15.5	14.0
Mean corpuscular volume (fL)	44.5	45.5
Mean corpuscular hemoglobin (pg)	15.5	15.6
Mean corpuscular hemoglobin concentration (g/L)	34.8	34.3
Red cell distribution width (%)	29.2	29.5
White blood cell count (10 <sup>3</sup> /μL)	4.77	5.75
Eosinophil (%)	0.0	0.2
Basophil (%)	0.2	0.0
Neutrophil (%)	26.8	30.8
Lymphocyte (%)	65.0	60.5
Monocyte (%)	8.0	8.5
Platelet (10 <sup>3</sup> /μL)	2728	2173
<b>Coagulation Function</b>		
Plasma prothrombin time (s)	9.9	–
Active plasma prothrombin time (s)	35.6	–
<b>Clinical Chemical</b>		
Iron serum (μg/dL)	29	–
Total iron-binding capacity (μg/dL)	217	–
Blood urea nitrogen (mg/dL)	5	–
Creatinine (mg/dL)	0.25	–
Albumin (g/dL)	4.4	–
Alanine aminotransferase (U/L)	21	–
Aspartate aminotransferase (U/L)	11	–
Sodium (mmol/L)	137	–
Potassium (mmol/L)	3.7	–
Chloride (mmol/L)	100	–
Calcium (mg/dL)	7.7	–



**Fig. 1.** Peripheral blood smear analysis.



**Fig. 2.** Hemoglobin electrophoresis.

MCV/RBC formula [10]. Patients have thalassemia if the Mentzer index is < 13 and iron deficiency anemia if the Mentzer index is > 13 [9,11].

The patient reported in this case had a Mentzer index value of 12.8 when calculated using the first complete blood count and a Mentzer index value of 14.8 when computed using the second total blood count. The Mentzer index does not provide consistent values in this patient. This condition is supported by a statement that the hematological index to distinguish thalassemia and iron deficiency anemia can give an error if there is a coexistence between the two [12]. Most patients with thalassemia have iron overload, so it has long been believed that iron deficiency is not found in thalassemia patients. Lower baseline hemoglobin level that improves after iron therapy [13]. Thalassaemic patients with iron deficiency have lower hemoglobin levels compared to thalassemia patients without iron deficiency [7]. The management of children with iron deficiency anemia can be in the form of iron preparations at a dose of 4–6 mg/Kg/day, supervising the response to an increase in Hb of 2 g/dL or more. Blood transfusions in the PRC can also be given in severe anemia conditions with Hb levels <4 g/dL components [14].

Hemoglobin electrophoresis has confirmed the presence of

$\beta$ -thalassemia in this patient. The results of the clinical chemistry examination showed low serum iron. Transferrin saturation in this patient was calculated using the formula of  $SI/TIBC \times 100\%$ , offering 13.36%. According to WHO criteria, iron deficiency is defined as Ferritin  $<15$  g/L, transferrin saturation  $<16\%$ , or hemoglobin increase of 1 g/dL after two months of iron supplementation (varies with pregnancy and ethnic differences) [15]. The most common causes of iron deficiency in children are nutritional imbalances and excessive cow milk consumption. Physiological anemia develops in the postnatal period, and iron stores are sufficient to meet the erythropoiesis needs of the first six months in the absence of significant blood loss. In children with low birth weight and perinatal blood loss, iron stores are depleted more rapidly. Excessive cow milk consumption can also cause iron deficiency because calcium and casein phosphopeptide in cow milk can block iron absorption. If the child is given a low-iron diet after six months of age, iron deficiency will develop quickly when the child's iron stores are depleted [11].

The limitation in this case report is the lack of a complete iron profile examination which includes ferritin and Prussian blue staining of bone marrow aspirates. Microscopic examination of the Prussian blue aspirate of bone marrow remains the gold standard for diagnosing iron deficiency [16]. However, this examination is too invasive to be performed on this patient. Clinicians did not check Ferritin in this patient for efficiency because transferrin saturation had already met the WHO criteria for iron deficiency. Children with  $\beta$ -thalassemia must have iron in their blood because events like our case have occurred in other patients. Because an iron deficiency in children interferes with the growth and development of children [17].

#### 4. Conclusion

A 6-year-old girl with complaints of paleness since one week before admission to the hospital. Patients are diagnosed with thalassemia, in which thalassemia with severe microcytosis suggests possible coexistence with iron deficiency. A complete iron profile examination is required for this patient to ensure appropriate and comprehensive medical management.

#### Ethical approval

Not applicable.

#### Sources of funding

None.

#### Author contribution

All authors contributed toward data analysis, drafting and revising the paper, gave final approval of the version to be published and agree to be accountable for all aspects of the work.

#### Consent

Written informed consent was obtained from the patient's parent/guardian for publication of this case report and accompanying images. A copy of the written consent is available for review by the Editor-in-Chief of this journal on request.

#### Registration of research studies

1. Name of the registry: -.
2. Unique Identifying number or registration ID: -.

3. Hyperlink to your specific registration (must be publicly accessible and will be checked): -.

#### Guarantor

Hartono Kahar.

#### Provenance and peer review

Not commissioned, externally peer-reviewed.

#### Declaration of competing interest

Laurensia Goretti, Christophorus Oetama Adiatmaja, and Hartono Kahar declare that they have no conflict of interest.

#### Acknowledgement

We want to thank our editor "Fis Citra Ariyanto".

#### References

- [1] A. Iolascon, L. De Falco, C. Beaumont, Molecular basis of inherited microcytic anemia due to defects in iron acquisition or heme synthesis, *Haematologica* 94 (3) (2009) 395–408, <https://doi.org/10.3324/haematol.13619>.
- [2] T.G. DeLoughery, Microcytic anemia, *N. Engl. J. Med.* 371 (14) (2014) 1324–1331, <https://doi.org/10.1056/NEJMra1215361>.
- [3] R. Galanello, R. Origa, Beta-thalassemia, *Orphanet J. Rare Dis.* 5 (2010) 11, <https://doi.org/10.1186/1750-1172-5-11>.
- [4] A. Cao, R. Galanello, Beta-thalassemia, *Genet. Med. : Off J. Am. Coll. Med. Genet.* 12 (2) (2010) 61–76, <https://doi.org/10.1097/GIM.0b013e3181cd68ed>.
- [5] S. Fucharoen, D.J. Weatherall, The hemoglobin E thalassemias, *Cold Spring Harbor Perspect. Med.* 2 (8) (2012), <https://doi.org/10.1101/cshperspect.a011734>.
- [6] S. Verma, R. Gupta, M. Kudesia, A. Mathur, G. Krishan, S. Singh, Coexisting iron deficiency anemia and Beta thalassemia trait: effect of iron therapy on red cell parameters and hemoglobin subtypes, *ISRN hematology* 2014 (2014) 293216, <https://doi.org/10.1155/2014/293216>.
- [7] C.K. Lin, L.P. Chen, H.L. Chang, Y.C. Sung, Underestimation of the coexistence of iron deficiencies and thalassemia minors: a single institution experience in Taiwan, *Kaohsiung J. Med. Sci.* 30 (8) (2014) 409–414, <https://doi.org/10.1016/j.kjms.2014.03.010>.
- [8] R.A. Agha, T. Franchi, C. Sohrabi, G. Mathew, A. Kerwan, The SCARE 2020 guideline: updating consensus surgical CAse REport (SCARE) guidelines, *Int. J. Surg.* 84 (2020) 226–230, <https://doi.org/10.1016/j.ijsu.2020.10.034>.
- [9] A. Vehapoglu, G. Ozgurhan, A.D. Demir, S. Uzuner, M.A. Nursoy, S. Turkmen, et al., Hematological indices for differential diagnosis of Beta thalassemia trait and iron deficiency anemia, *Anemia* 2014 (2014) 576738, <https://doi.org/10.1155/2014/576738>.
- [10] C.A. Sahli, A. Bibi, F. Ouali, S.H. Fredj, B. Dakhlaoui, R. Othmani, et al., Red cell indices: differentiation between  $\beta$ -thalassemia trait and iron deficiency anemia and application to sickle-cell disease and sickle-cell thalassemia, *Clin. Chem. Lab. Med.* 51 (11) (2013) 2115–2124, <https://doi.org/10.1515/cclm-2013-0354>.
- [11] N. Özdemir, Iron deficiency anemia from diagnosis to treatment in children, *Turk pediatri arsi* 50 (1) (2015) 11–19, <https://doi.org/10.5152/tpa.2015.2337>.
- [12] R.F. Hinchliffe, J.S. Lilleyman, Frequency of coincident iron deficiency and beta-thalassaemia trait in British Asian children, *J. Clin. Pathol.* 48 (6) (1995) 594–595, <https://doi.org/10.1136/jcp.48.6.594>.
- [13] A. Pansuwan, G. Fucharoen, S. Fucharoen, B. Himakhun, S. Dangwiboon, Anemia, iron deficiency and thalassemia among adolescents in Northeast Thailand: results from two independent surveys, *Acta Haematol.* 125 (4) (2011) 186–192, <https://doi.org/10.1159/000322666>.
- [14] P. Koppaarthi, A.H. Kelkar, K. Aggarwal, S. De Filippis, B. Fletcher, Red blood cell exchange in a patient with extramedullary hematopoiesis and cor pulmonale secondary to beta thalassemia, *Cureus* 13 (3) (2021), e13638, <https://doi.org/10.7759/cureus.13638>.
- [15] A.U. Kelly, S.T. McSorley, P. Patel, D. Talwar, Interpreting iron studies, *BMJ (Clinical research ed)* 357 (2017) j2513, <https://doi.org/10.1136/bmj.j2513>.
- [16] K.S. Phiri, J.C. Calis, D. Kachala, E. Borgstein, J. Waluza, I. Bates, et al., Improved method for assessing iron stores in the bone marrow, *J. Clin. Pathol.* 62 (8) (2009) 685–689, <https://doi.org/10.1136/jcp.2009.064451>.
- [17] B. Lozoff, Iron deficiency and child development, *Food Nutr. Bull.* 28 (4 Suppl) (2007) S560–S571, <https://doi.org/10.1177/15648265070284s409>.