

## PRIMARY NON-HODGKIN LYMPHOMA OF THE ORBIT PRESENTING WITH MASSIVE BILATERAL PERIORBITAL TUMORS

TÜNDE TÓRÓK-VISTAI<sup>1</sup>, ANCA BOJAN<sup>1</sup>,  
ANDREI CUCUIANU<sup>1</sup>, ANDREA ZSOLDOS<sup>1</sup>

<sup>1</sup>Department of Hematology, Iuliu Hatieganu University of Medicine and Pharmacy, Cluj-Napoca, Romania

### Abstract

*Extranodal onset can be seen in approximately 25-40% of the cases of non-Hodgkin lymphomas and diagnosis is often difficult due to nonspecific symptoms. Orbital lymphomas represent approximately 50% of the orbital malignancies. Common symptoms and signs at presentation are: palpable tumor, exophthalmia, diplopia and decreased vision. Diagnosis can be made only by biopsy and early treatment is important in order to increase the chance of cure. We present the case of a patient whose diagnosis and treatment were delayed due to refusal of biopsy and, although complete remission of lymphoma was obtained, the vision loss was permanent because of prolonged compression on the optic nerves. A particularity of this case is the presence of massive periorbital tumors on admission to the hospital, incorporating the eye globes completely and causing impressive facial deformity.*

**Keywords:** non-Hodgkin's lymphoma, orbital tumors, vision loss

### Introduction

Non-Hodgkin's lymphomas are neoplastic diseases of the lymphatic system, usually involving the lymph nodes, but almost 25-40% of the cases have extranodal onset [1]. Orbital lymphomas represent about 2% of all lymphomas, 5-15% of extranodal lymphomas and approximately 50% of all primary malignant tumors of the orbit [2]. An association between Chlamydia psittaci infection and orbital adnexal lymphoma has been described, and also, thyroid eye disease is considered to be a predisposing factor [3].

Orbital lymphoma can arise from the eyelid, orbit, lacrimal glands or conjunctiva. Clinical signs and symptoms are nonspecific, often delaying the diagnosis. In 25% of the cases the conjunctiva is involved and the patients present with salmon red patches or swollen conjunctiva. In the rest of the patients, presentation is with orbital mass [2]. Common signs at presentation are: palpable mass, pain, exophthalmia, ptosis, diplopia, decreased vision and abnormal ocular movement [4,5]. In approximately 10-17% of cases the lymphoma appears bilaterally, simultaneously in both orbits in 80% of cases and subsequently in 20% of cases. Between 20-40% of the patients have extraorbital lymphoma at onset, especially those with aggressive histology [6,7].

The majority of orbital lymphomas are of low-grade histology (84%), the minority (16%) being aggressive lymphomas [8]. The commonest sub-type of orbital lymphoma is extranodal marginal-zone lymphoma. Other

histological types are: follicular, lymphocytic, mantle cell and diffuse large B-cell lymphomas [9,10].

Diagnosis is based on biopsy and staging procedures should include imaging investigations: computed tomography (CT), or magnetic resonance imaging (MRI) to evaluate local extension but also systemic lymphomatous involvement. Differential diagnosis should include other malignant tumors and inflammatory pseudo-tumors of the orbit and thyroid associated orbit disease [1].

The prognosis of ocular lymphoma depends on the histological type, age, localization and stage of disease. Favorable prognostic factors are: low-grade histology, younger age, conjunctival localization and early stage at presentation [11].

Treatment depends on the stage: in localized orbital lymphoma, radiotherapy is highly effective, while in patients with high grade histology or disseminated lymphoma, systemic chemotherapy should be used. In some localized cases, antibiotic therapy against Chlamydia results in complete remission [12,13].

### Case report

A case of bilateral orbital lymphoma is presented below, having the approval of the Ethical Committee of the Hospital and the written consent of the patient for publishing his pictures.

A 50 years old male patient referred first to the Ophthalmology Clinic in april 2012 for bilateral exophthalmos and palpebral ptosis. Physical examination revealed bilateral orbital tumors. Biopsy was refused by the patient. In November 2012, he was admitted at the Maxillofacial

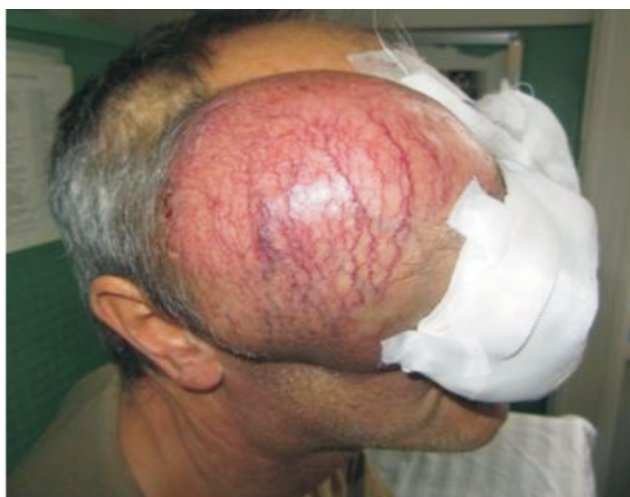Manuscript received: 06.11.2013

Received in revised form: 05.12.2013

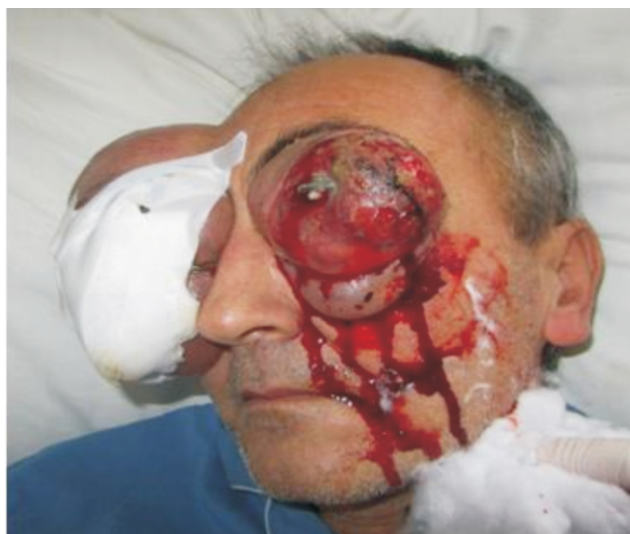Accepted: 12.12.2013

Address for correspondence: tunde.torok@yahoo.com

Surgery Clinic for bleeding from the periorbital tumors. A biopsy was performed and diffuse large B-cell lymphoma was diagnosed. On admission to the Hematology Clinic the patient presented bilateral periorbital tumors (12 cm in the right and 8 cm in the left side), involving the eyelids and incorporating the eye globes (fig.1 and 2). The patient also complained of complete loss of vision and constitutional symptoms (night sweats and weight loss).



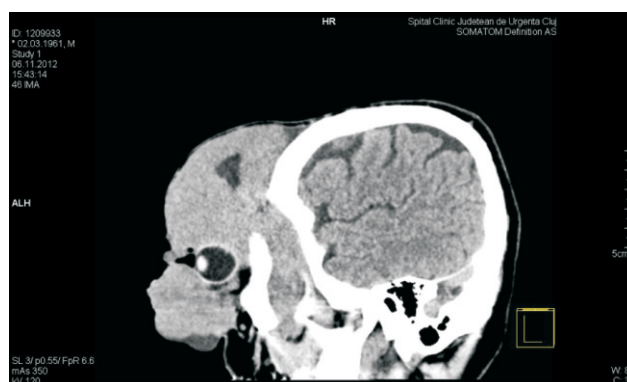
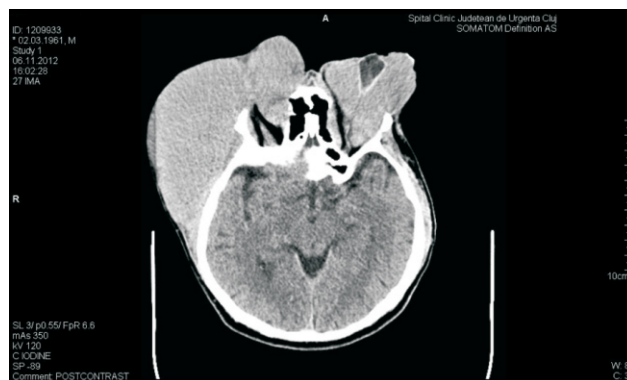**Figure 1.** Massive right orbital tumor



**Figure 2.** Left orbital tumor with spontaneous bleeding

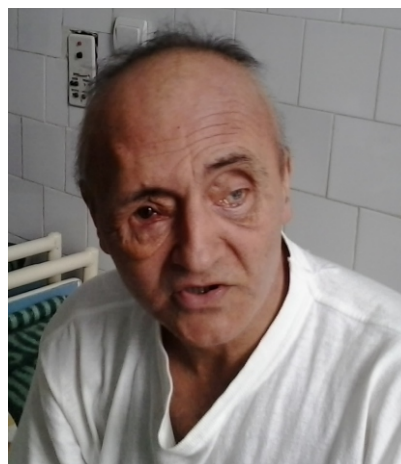Laboratory tests revealed leucocytosis (13000/microliter) with 55% atypical lymphocytes in the peripheral blood smear, anemia (hemoglobin=10g/dl), elevated erythrocyte sedimentation rate and decreased level of IgG and IgA. Serological tests for Chlamydia, HIV and hepatitis viruses (B and C) were negative. Bone marrow biopsy showed lymphomatous involvement. Cranio-orbital CT revealed bilateral orbital tumors (14/8/11 cm in the right with 2.7 cm ptosis of the right eye and 7.8/5.6/6.5 cm in the left with 2 cm ptosis of the left eye), without invasion of the eye globes, bones, paranasal sinuses or of the cerebral parenchyma (fig.3 and 4). Cervical and thoraco-

abdominal CT showed enlarged latero-cervical and retroperitoneal lymph nodes.



**Figures 3 and 4.** Cranio-orbital CT images before therapy

The patient was diagnosed with stage IVB diffuse large B-cell primary orbital lymphoma and R-CHOP (Rituximab + Cyclophosphamide, Adriablastin, Vincristin and Prednison) chemotherapy was started, which produced a rapid response. After 2 months, the patient presented with relapse. R-ICE (Rituximab + Iphosphamide, Carboplatin and Etoposide) second-line chemotherapy was started and complete remission was obtained after 4 cycles (fig. 5). However, the patient did not regain his vision due to optic nerve atrophy. He did not return for completion of the chemotherapy cycles, nor for follow-up.



**Figure 5.** Resorption of the orbital tumors after chemotherapy

### Discussion

Primary orbital lymphoma is a rare disease, diagnosis being difficult due to nonspecific symptoms at presentation. Patients usually present with unilateral orbital tumors, only 10-17% of the cases having bilateral orbital involvement at onset. Ocular lymphomas have low-grade histology in the majority of the cases and prognosis is good if diagnosis is made in early stages. However, permanent loss of vision can be seen due to optical nerve atrophy, even in patients with a complete remission of the lymphoma.

Treatment consists of radiotherapy in localized disease but if systemic involvement is present, chemotherapy should be used. The particularity of this case is the presence of massive orbital tumors, due to delayed diagnosis. Long-term prognosis of this patient is unfavorable, due to the advanced stage of the disease at presentation and early relapse after an initial good response to chemotherapy.

### References

1. Ürün Y, Can E, Baris E, Akbulut H, Utkan G, Icli F. Primary extranodal non-Hodgkin's lymphoma presenting as painful gingival swelling. *Exp Oncol*, 2012; 34(2):134-135.
2. Weerakkody Y, Gaillard F. Orbital lymphoma. Available from: URL: <http://radiopaedia.org/articles/orbital-lymphoma>
3. Woolf DK, Ahmed M, Plowman PN. Primary lymphoma of the ocular adnexa (orbital lymphoma) and primary intraocular lymphoma. *Clin Oncol*, 2012; 24(5):339-344.
4. Rey-Porca C, Perez-Encinas M, Gonzales F. Orbital lymphomas. Presentation of nine cases. *Arch Soc Esp Oftalmol*, 2008; 83:95-104.
5. Eckart AM, Lemound J, Rana M, Gellrich NC. Orbital lymphoma: diagnostic approach and treatment outcome. *World J Surg Oncol*, 2013; 11:73. Available from URL: <http://http://www.ncbi.nlm.nih.gov/pubmed/23506357>
6. Gedik S, Gur S, Maral T, Akova YA, Demirhan B. Bilateral synchronous primary orbital lymphoma. *Advances in therapy*, 2006; 23(3):433-438.
7. Meulenbeld HJ, Peters V. Binocular proptosis in orbital lymphoma. *N Engl J Med*, 2008; 359(19):23.
8. Yadav BS, Sharma SC. Orbital lymphoma: role of radiation. *Indian J Ophthalmol*, 2009; 57(2):91-97.
9. Essadi I, Tazi EM, Allam W, Sbitti Y, Ichou M and Errhani H. Primary non-Hodgkin's lymphoma of the orbit: a case report. *Medical case studies*, 2011; 2(2):19-21.
10. Nutting CM, Jenkins CD, Norton AJ, Cree I, Rose GE and Plowman PN. Primary orbital lymphomas. *The Hematology Journal*, 2002; 3:14-16.
11. Martinet S, Ozsahin M, Belkacemi Y et al. Outcome and prognostic factors in orbital lymphoma: a rare cancer network study on 90 consecutive patients treated with radiotherapy. *Int J Radial Oncol Biol Phys*, 2003; 55(4):892-898.
12. Schick U, Iermeo O, Unsold R, Hassler W. Treatment of primary orbital lymphomas. *Eur J Haematol*, 2004; 72(3):186-192.
13. Bhatla S, Paulino AC, Buatii JM, Mayr NA, Wen BC. Curative radiotherapy for primary orbital lymphoma. *Int J Radial Oncol Biol Phys*, 2002; 54(3):818-823.