

The ideal patient positioning in spine surgery: a preventive strategy

Paulo Diogo Cunha¹, Tiago P Barbosa¹, Guilherme Correia¹, Rafaela Silva², Nuno Cruz Oliveira¹, Pedro Varanda^{1,3} and Bruno Direito-Santos^{1,3}

¹Orthopedic Surgery Department, Hospital de Braga, Portugal

²Anesthesiology Department, Hospital de Braga, Portugal

³Life and Health Science Research Institute, University of Minho, Portugal

Correspondence should be addressed to P D Cunha

Email

paulo.cunha@hb.min-saude.pt

- Patient positioning on the surgical table is a critical step in every spine surgery. The most common surgical positions in spine surgery are supine, prone and lateral decubitus.
- There are countless lesions that can occur during spine surgery due to patient mispositioning. Ulnar nerve and brachial plexus injuries are the most common nerve lesions seen in malpositioned patients. Devastating complications due to increased intraocular pressure or excessive abdominal pressure can also occur in prone decubitus and are real concerns that the surgical team must be aware of.
- All members of the surgical team (including surgeons, anesthesiologists and nurses) should know how to correctly position the patient, identify possible positioning errors and know how to avoid them in order to prevent postoperative morbidity.
- This work pretends to do a review of the most common positions during spine surgery, alert to errors that can happen during the procedure and how to avoid them.

Keywords

- ▶ spine surgery
- ▶ patient positioning
- ▶ perioperative visual loss
- ▶ compressive neuropathies

EFORT Open Reviews (2023) 8, 63–72

Introduction

Patient positioning on the surgical table is a critical step in any spine surgery. It is important to achieve optimal exposure not only to perform the aimed procedure but also to minimize the risk of secondary injuries avoiding any postoperative morbidity (1, 2, 3).

The most common surgical positions in spine surgery are prone and supine positions. Each of them has multiple complications associated with hemodynamic changes, peripheral nerve compressions and body pressure points (1).

It is important for the safety of the patient that the entire surgical team knows how to best position the patient on the surgical table and recognize perioperative signs of complications.

Although rare, perioperative visual loss is a devastating complication of patient positioning in spine surgery. In a study performed by Shen and colleagues in 2009, the incidence of postoperative visual loss was 3.09/10,000 (0.03%) (4). Peripheral nerve injuries have an incidence of 0.03–0.1%, with the ulnar nerve and brachial plexus injuries being the most common (5). In a review, Uribe *et al.* identified that 17 out of 517 patients experienced postoperative brachial plexopathy when in the prone

position and 44 after surgery in supine or lateral position (6).

This article aims to describe the common positions in spine surgery, providing the details required to avoid positioning complications.

Supine position

Supine position in cervical spine surgery (pathologies and position)

The supine or dorsal decubitus position is easily achievable and offers good exposure to the anterior aspect of the neck, allowing access to the anterior cervical spine.

The anterior approach of the cervical spine is used to perform anterior discectomy and intervertebral fusion, intervertebral arthroplasty and vertebral corpectomy. The osseous vertebral anatomy is widely accessed through a natural corridor, allowing for the longitudinal manipulation from C1 to C7 in the treatment of degenerative disc diseases, vertebral body tumors or metastasis and vertebral body fractures (7, 8).

There are some methods to address the most common anterior cervical pathologies: the anterolateral approach (*Smith-Robinson* approach) and the transoral approach

(9). In both, the patient lies in supine position. The anterolateral approach is the most widely used approach to treat subaxial cervical spine pathology. It was first described by R.A. Robinson and G. W. Smith in 1958 for the treatment of cervical disorders by anterior removal of the intervertebral disc and interbody fusion. It was later modified by Southwick (9, 10). An oblique skin incision is made from the medial border of sternocleidomastoid muscle to the midline. Through a plane between the sternocleidomastoid and the *longus colli* muscles, the surgeon can access two or three cervical levels and perform internal fixation of odontoid fractures or discectomy and interbody fusion.

The transoral approach, which is made through a longitudinal incision of the dorsal wall of the pharynx, provides access to the craniovertebral junction and is useful to treat occipitocervical trauma (C1–C2 dislocation, atlas or odontoid fractures) or to decompress the spinal cord in rheumatoid disease (7, 9, 11).

In an anterior approach of the cervical spine, the patient is placed in supine position, at a radiolucent table. Adequate head and neck control is mandatory to prevent damage to the spinal cord.

To facilitate the exposure, the neck should be put into slight hyperextension. This position allows for a larger working area and opens up the intervertebral disc spaces anteriorly. A shoulder roll is placed between shoulder blades, under the cervicothoracic junction. In the anterolateral approach, the neck should be rotated to the left or to the right, depending on the choice of the surgeon. This position can be achieved by elevating the ipsilateral shoulder with a rolled blanket or a pillow (1) (Fig. 1).

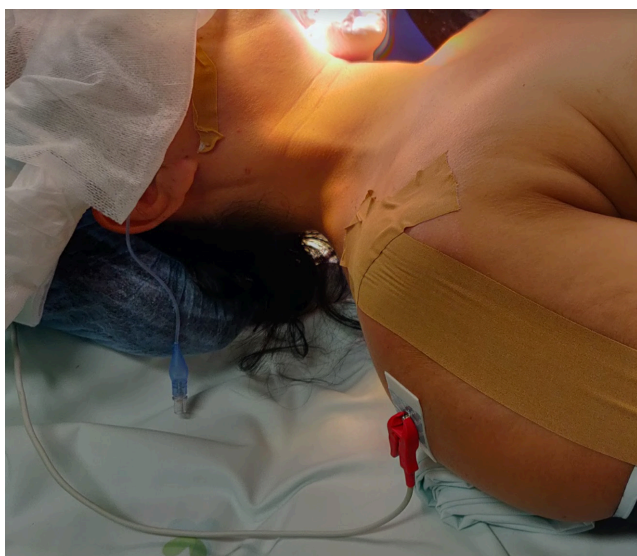

Figure 1
Neck position for anterior approach of the cervical spine.

Usually, the neck and head are stabilized by a well-padded head cushion. When traction is needed, the head is fixed neutrally or in light flexion with a Mayfield head holder or, alternatively, resorting to Gardner–Wells tongs, lining the head of the patient with the body (7, 9, 12, 13).

The arms are placed either on an arm board or maintained at the body sides of the patient. The shoulders must be pulled down with adhesive tape to depress them, in order to obtain a good lateral x-ray film (14, 15) (Fig. 2).

To decrease pressure on the lower part of the back, hips and knees can be flexed (with 15° angulation). A foam roll should be placed behind the knees (2, 16, 17) (Fig. 3).

Supine position in lumbar spine surgery (pathologies and position)

The main surgical pathologies of the lumbar spine result from traumatic and degenerative disorders such as vertebral fractures disc herniations, tumors/metastatic disease, spondylodiscitis, sagittal or coronal malalignment and imbalance.

In order to access the anterior elements of the lumbar spine, mainly the vertebral bodies and intervertebral discs, anterior or anterolateral approaches are described. The anterior transperitoneal and the anterolateral retroperitoneal are common classic approaches to perform intervertebral arthrodesis or corpectomy. For the last few decades, some new minimally invasive approaches have been developed and have become standard procedures to treat lumbar spine pathologies. The most commonly used are the anterolateral approach, applied in anterolateral interbody fusion (ALIF), the mini-open midline approach and the pararectal approach (7, 15, 18, 19).

ALIF or total disc replacement surgery by anterior access (retro- or transperitoneal approach) is best carried out with the patient in standard supine position or in Da Vinci position (for L5–S1 level). In standard supine position, the patient is placed in dorsal decubitus, with the head on a pillow and the neck in neutral position, the arms abducted to a 90° angle on well-padded arm boards. No bolstering is used under the lumbar spine to prevent hyperlordosis, which could hinder adequate discectomy (Fig. 4).

For access to L5–S1, the patient could be positioned in Da Vinci position, like the Vitruvian man. Head, neck and arms are placed as described above. In this position, the legs are spread apart (approximately 30° from the midline) and secured in well-cushioned leg holder, with the surgeon standing between them. The knees are slightly flexed and the feet should have a gel pad under them (7, 15, 20) (Fig. 5).

Complications of supine position

Complications due to patient positioning are rare in supine position when compared to prone position (1). Most

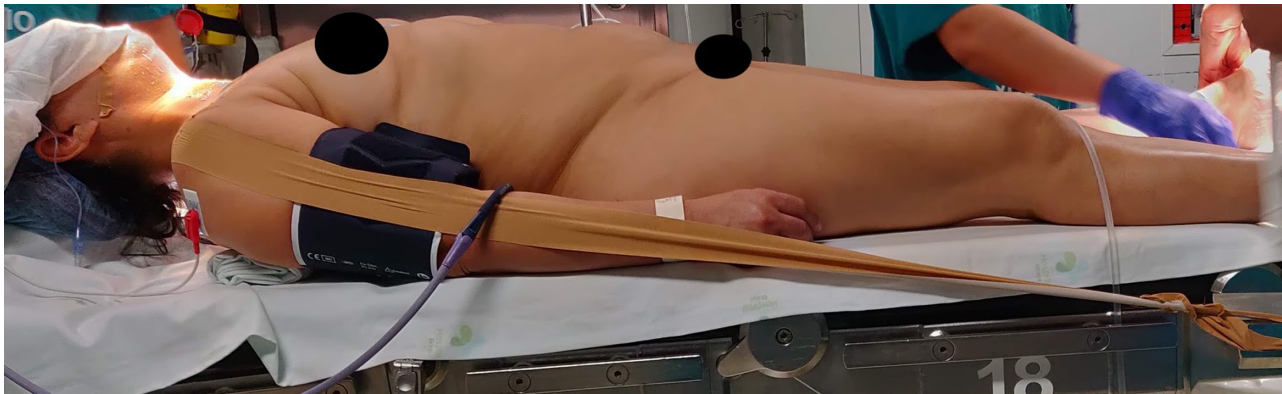

Figure 2
Supine position for anterior approach of the cervical spine.

of them are related to the neck position (lateral flexion or hyperextension). Peripheral neuropathies (especially affecting the ulnar nerve) result from poor padding of pressure points (1).

It is important to pay special attention to head, neck and upper limbs position, as well as to pressure points at the elbow, shoulder, knees and ankles.

In anterior cervical surgery, the head and the neck of the patient should rest on a foam pillow or on padded headrest, in neutral or slightly extended position, avoiding hyperflexion, hyperextension and excessive lateral rotations. Hyperflexion of the neck can compromise blood flow in vertebral and carotid arteries, causing brain and spinal ischemia, especially in patients with osteophytes, arthritis or vascular atherosclerosis. Hyperflexion can cause obstruction of venous and lymphatic drainage from the head, which can result in tongue and face swelling. Hyperflexion of the neck may also cause airway compromise from kinking of the endotracheal tube (16). At least a distance of 2–3 finger should separate mandibular protuberance and the manubrium (1, 21). Neck hyperextension should also be avoided since it can cause narrowing of the cervical spinal canal due to buckling of the *ligamentum flavum* (12, 15). Patients with cervical spondylosis may suffer spinal compression between the

ligamentum flavum and the posterior vertebral body osteophyte with an exaggerated neck extension (12, 15).

Of all neuropathies, ulnar nerve and brachial plexus injuries are the most common and the main mechanisms are compression and stretching. Ulnar nerve neuropathy is the most common nerve injury in the perioperative setting. Signs and symptoms can range from loss of sensation in the fourth and fifth fingers and weakness in the opposition and abduction of the fifth finger to a claw-like hand due to atrophy of the intrinsic muscles (5, 22, 23). Forearm position is a significant factor in determining pressure on the ulnar nerve. Flexion of the elbow and pronation of the forearm may lead to excessive pressure on ulnar nerve. To prevent ulnar neuropathy, proper padding of the elbow is important to prevent compression of the nerve against the medial epicondyle but forearm in neutral position and flexion under 90° angle are also important to avoid stretching of the ulnar nerve (5, 24). If the arms are tucked at the side of the patient, neutral forearm position is recommended. If the arms are on arm boards, either supination or neutral forearm positions may be used, decreasing pressure on the postcondylar groove of the humerus (5, 17, 22, 23, 25).

Brachial plexus injury is also a concern of mispositioning of patients on surgical table. In the supine position,

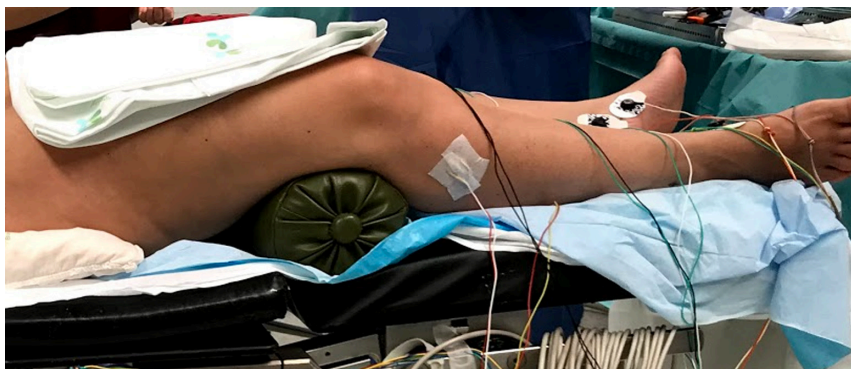

Figure 3
Leg position in supine decubitus.

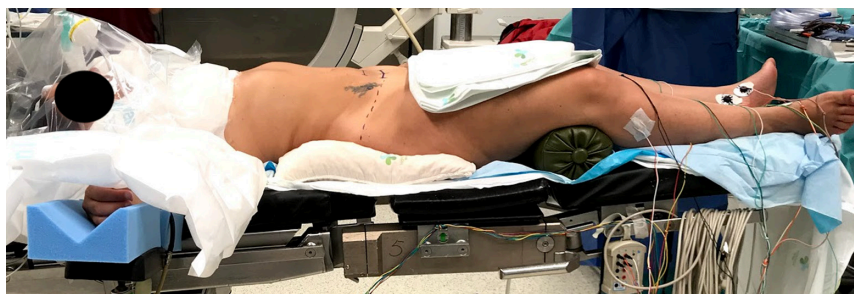

Figure 4
Supine position in lumbar spine surgery.

the brachial plexus is more at risk of stretching than compression. Excessive strain of the neck in the lateral flexion or excessive traction on the shoulder can lead to stretching and injury of the brachial plexus (6, 16). The best way to prevent brachial plexopathy is to prevent over traction of the shoulders or limit shoulder abduction to a maximum of 90°. Excessive lateral rotation of the head to one side should also be avoided to prevent stretching of contralateral brachial plexus (5, 17, 21, 26).

Radial and median nerve neuropathies are rare complications. Radial neuropathy may occur by compression at the spiral groove of the humerus. Hyperextension of the elbow may place the median nerve at risk for injury. To prevent that, we should avoid overextension of the elbow to a point that is uncomfortable to the patient when awoken (5, 25).

In the lower extremity, the common peroneal nerve is at risk of damage because it can be compressed against the fibular head if some lateral rotation is achieved. A pillow or

a gel pad should be put under the knee. Whenever used, compressive straps to restrain leg movement should be placed below the knee but not very thigh (1, 17, 24).

Prone position

Prone position in cervical spine surgery (pathologies and position)

A posterior approach to the cervical spine may be indicated in posteriorly located lesions compressing the spinal cord and/or the exiting nerve roots, such as disc disorders. C1 and C2 fractures as well as atlantooccipital dislocation can also be treated through posterior fixation. Another indication to approach cervical spine posteriorly is to reinforce anterior cervical surgery (7). A midline incision is made, with a subsequent surgical dissection through the level of interest in a relative avascular plane.

In the posterior approach to the cervical spine, the patient is in prone or ventral decubitus, in a radiolucent table. The position of head and neck is very important. In fact, the neck should be in a flexed position and the head may be fixed in a device such as Mayfield tongs. The Mayfield head holder is a 3-pin point support, with a rocker arm including 2-skull pins, which should be equidistant from the center line of the head and an arm with a single pin in line with the center line. The pins should be inserted 2.5–3.5 cm above the apex of auricle (27). Alternatively, the face is placed on a foam pillow with cutouts for the eyes, nose and airways, with support for the chin and the forehead. The body of the patient is placed over a padded support in the chest and another support at the level of the iliac crest to reduce abdominal compression. The arms may rest alongside the trunk or can be placed on arm boards. Both shoulders are pulled caudally and fixed with tape. The knees are slightly flexed and supported by a squared gel pad. The legs should rest in two pillows to leave the heels free from contact, with the toes pointing downward. This is known as concorde position (1, 7, 8, 15) (Fig. 6).

Prone position in lumbar spine surgery (pathologies and position)

The posterior approach is the most performed in lumbar spine surgery. It has some advantages over the anterior

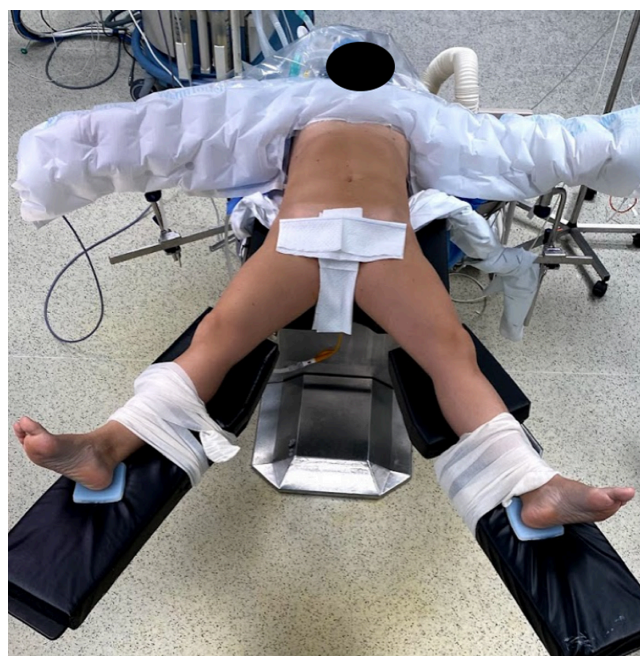

Figure 5
Da Vinci position for anterior approach to lumbar spine.

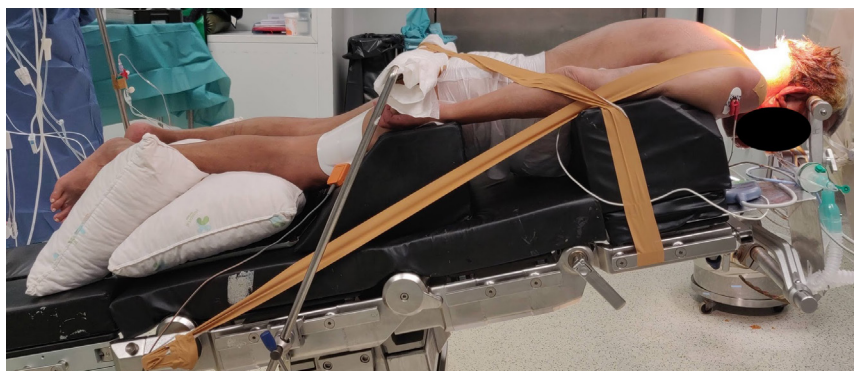

Figure 6
Concorde position for posterior approach to cervical spine.

approach such as earlier identification of the spinal cord, treatment of the posterior elements disorders and better correction of spinal imbalances. It is indicated in the treatment of symptomatic disc herniation, segmental instability as a result of trauma, tumors or listhesis. Posterior lumbar spine surgery can be made either by classic posterior/posterolateral approaches like the midline posterior approach and the paramedian approach or by minimal invasive percutaneous techniques (7, 15, 19, 28).

There are some variations in the prone position, such as the knee–chest, the knee–elbow or the kneeling position. For a proper position of the patient in ventral decubitus, the surgeon can use some special body supports, like the Wilson frame, the Andrews frame and the Relton and Hall frame (Fig. 7).

The knee–chest position is used in procedures such as laminectomy and discectomy. The patient is placed prone on an Andrews frame, which permits loss of lumbar lordosis, warranting a safe and stable positioning with a good spinal lumbar flexion (3, 29, 30). Adjusting hip flexion with the mobile tibial support, we could create and control a relative lumbar spine kyphosis, increasing the interlaminar distance (31). The face is positioned on a padded headrest. A gel bolster is placed horizontally under the chest to leave the abdomen free from compression. If the patient is female, we should pay attention to the breast. In case of big size breasts, the cushion must be

placed above them. If the breasts are small, the bolster is placed below them. The arms are placed on a well-padded armrest, with the forearm and the wrist in neutral position. The lower extremities lie on an adjustable tibial support or a buttock support, with the hips and knees flexed at a 90° angle. A square gel pad should be placed under the knees and a pillow under the leg and feet. The feet must point down (2, 3, 29) (Fig. 8).

Positioning the patient prone on a Wilson frame also permits control on the sagittal plane, reducing the lumbar lordosis. The patient lies on two parallel, longitudinal curved pads, with adjustable curvature degree, which provide continuous support for chest and pelvis. The distance between the arches can be adjusted to allow the abdomen to hang free. The face is placed in a foam pillow with cutouts for the eyes, nose and airways, with support for the chin and the forehead. The arms are flexed and in neutral position, alongside the head and supported by well-padded arm boards. The hips flex over the inferior aspect of the Wilson frame. A gel pad is put under the knees and a pillow is placed under the legs at the ankle (3, 7, 17, 21, 31, 32) (Fig. 9).

The Relton–Hall operative frame is used in the correction of scoliotic spine surgery. It is not recommended in the treatment of disc degenerative disorders due to the lordosis it induces. The patient lies on four-padded individual supports in V-shaped pairs with a 45° inward

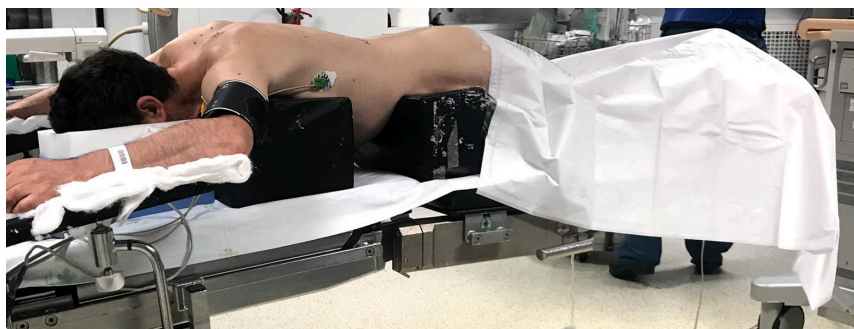


Figure 7
Prone position for posterior approach to lumbar spine.

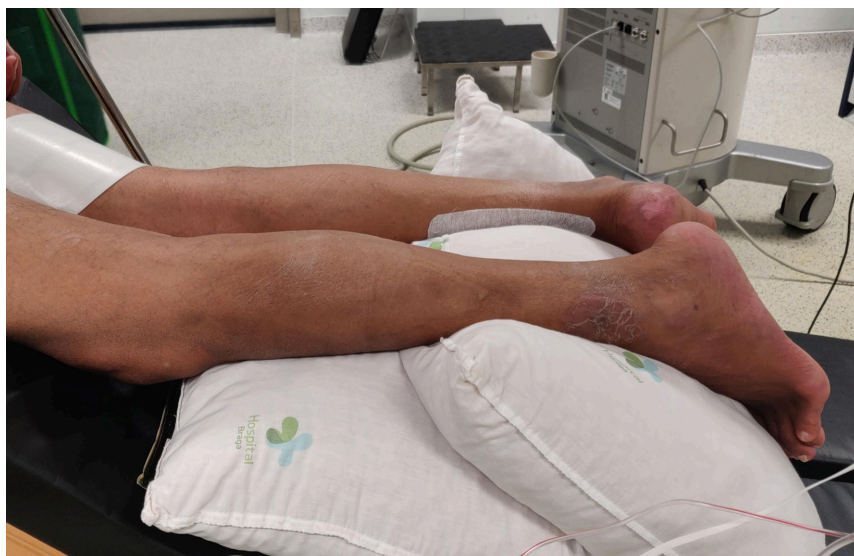

Figure 8
Leg and foot position in ventral decubitus.

tilting. The four pillars support the lateral thoracic cage and the antero-lateral pelvis. The head rests on a foam pillow. The arms are placed in padded arm supports, in a neutral position alongside the head. Hips are flexed at a 60° angle, the knees should lie on a gel pad and the feet are supported by a pillow, pointing downwards (21, 29, 33, 34).

Complications of prone position

Perioperative complications result from excessive pressure applied to ventral or nervous structures and are associated with serious morbidity. The most devastating complications are ophthalmologic, neurologic (brachial plexus and ulnar nerve injuries) and excessive bleeding (5, 31, 35). Excessive compression on ventral structures, extremities and face may lead to hemodynamic complications, visual loss, peripheral nerve compressive lesions, compartment syndrome and skin breakdown.

Care must be taken when turning the patient into prone. The head and the neck must be stable to prevent the risk of secondary neurologic injuries (16, 31, 36). It is important to avoid extreme flexion of the neck since it can

result in obstruction of venous and lymphatic drainage from the head, which, in turn, can cause swelling of the neck and airway obstruction. Also, extreme flexion may produce spinal cord ischemia (7).

In the prone position, the patient must have their chest and pelvis supported to allow free movement of the abdomen. One advantage of using special frames, such as Wilson frame, is to give free space to the abdomen, avoiding compression of ventral structures (29, 35). Compression of the abdomen may lead to restriction on normal venous return through the inferior vena cava. High intra-abdominal pressure results in a shunt of blood flow through the epidural and paravertebral veins, which increases the pressure in the epidural venous circuit, augmenting the bleeding in the surgical field during spinal surgery. Abdominal compartment syndrome is also a potential complication of prone position, as visceral compression and intra-abdominal hypertension reduce perfusion to vital organs, leading to multi-organ failure (1, 17, 37). Therefore, to avoid such complications, adequate chest and pelvic support allow the abdomen to hang free and, even more, provides good excursion of diaphragm. Some studies found that abdominal venous pressure with

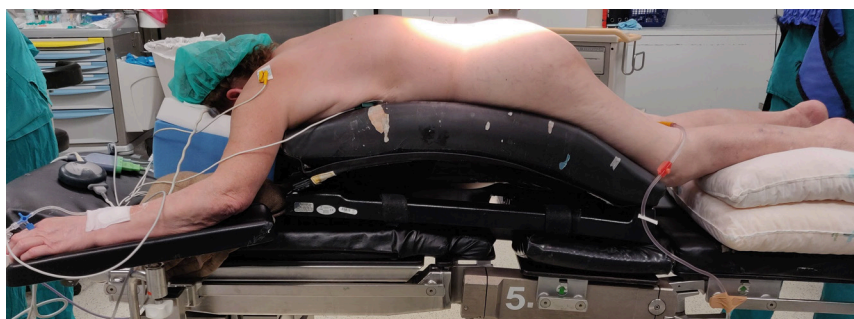

Figure 9
Prone position on Wilson frame.

Relton–Hall frame and Andrews frame is significantly lower compared with Wilson frame (21, 29, 30).

The prone position provides a number of benefits in respiratory physiology when compared to supine positioning. The most consistent finding is the increase in functional residual capacity when the patient is moved from supine to prone position. This may be explained both by the reduction of cephalad pressure on the diaphragm and by the reopening of the posterior atelectatic segments. Increased oxygenation has also been demonstrated with supine position and that may occur due to the improvement in the ventilation–perfusion ratio, since the previously dependent lung, which is better perfused, becomes better ventilated. Tidal volume and static compliance remain unchanged. If abdominal compression occurs, there is a cephalic deviation of the diaphragm with a consequent reduction in pulmonary compliance and an increase in intrathoracic pressure, this being another reason why it is important to ensure a free abdomen when turning the patient into prone position.

Ophthalmologic complications is another concern in prone position. Effectively, there are reports of postoperative visual loss, acute angle glaucoma, conjunctival swelling and corneal abrasions. Although postoperative visual loss is an uncommon complication, its prevention is a critical step in spine surgery. In a retrospective study conducted through the Nationwide Inpatient Sample, in United States, the overall incidence of visual loss after spine surgeries was 0.094% (4). It is well described but remains incompletely understood. The most common cause of postoperative visual loss is thought to be ischemic optic neuropathy (ION), but central artery occlusion and cortical blindness are also predictable causes. ION results from decreased perfusion pressure of the optic nerve head. Some conditions and positions can lead to ischemic optic neuropathy, such as anemia, hypotension, increased orbital venous pressure, significant blood loss, duration of the surgery of more than 6 h and Trendelenburg position (5, 31, 38).

A 10° angle reverse Trendelenburg position may reduce intraocular pressure (39). Furthermore, horseshoe-shaped headrest should be avoided because it can cause direct globe compression. A foam pillow with cutouts for eyes, ears, nose and airways should be used, to limit the increase in intraocular pressure. The head of the patient should be at or above the level of the heart, avoiding the head-down position, and in forward position to reduce the risk of venous stasis. It is advisable to avoid neck flexion, extension, lateral flexion or rotation. Wilson frame use has been associated with ischemic optic neuropathy, because the head is significantly lower than the heart leading to increased venous pressure (5, 31, 40). The eyes should be checked every 15–20 min to ensure that there is no orbital compression. Monitoring hypotension, anemia and blood

loss is also suggested so as to prevent postoperative visual loss (1, 5, 17, 37, 38).

Where the body is in contact with the surgical table, some pressure points are created and that can cause peripheral nerve neuropathies and skin breakdown.

As described earlier, ulnar nerve neuropathy and brachial plexopathy are the two most common nerve injuries in the upper limbs. Forearm and wrist should be in neutral position and elbow flexion over a 90° angle should be avoided. The arms should be at the same level of the head of the patient because if they are brought above, they can create pressure on axillary neurovascular complex by the humeral head (2, 22, 23, 37, 41). Brachial plexus is more susceptible to stretching rather than compression. Besides the previous recommendations, it is also advised to avoid positioning the arms below the chest level to prevent shoulder hyperextension and, consecutively, brachial plexus stretching (5, 21, 25, 37).

In the knee–chest position, there is risk of impaired perfusion distal to the knee by compression of vascular structures in the popliteal space. Excessive knee flexion greater than 90° should be avoided.

Another frequent nerve injured by compression in the prone position is lateral femoral cutaneous nerve (which can cause meralgia paresthetica). The condition may be prevented with good position of the pelvic support. Compression occurs especially when pelvic bolsters are mispositioned under the anterior superior iliac spine, where the nerve emerges (42).

When the patient is positioned on the Andrews frame, high pressure is exerted in the legs and this could lead to an anterior tibial compartment. Compression on the anterior thigh in the Wilson frame position may also lead to compartment syndrome (31, 43).

Lateral position

Lateral position in lumbar spine surgery (pathologies and position)

Anterolateral or lateral access to the lumbar spine, in order to do interbody fusion (anterior, oblique or lateral lumbar interbody fusion), to correct kyphoscoliosis or for interbody support, is performed with the patient in the lateral decubitus position (44, 45, 46).

In the lateral decubitus position, the patient is placed in the right lateral decubitus (left side up). There is the dependent side, which lies on the surgical table and the nondependent side (the upper side). The head is placed on a pillow or on a gel horseshoe. The neck should be in neutral position, without flexion or extension. A gel roll is placed under the upper chest on the dependent side to relieve pressure and avoid compression of neurovascular structures on the dependent arm. The arms could be

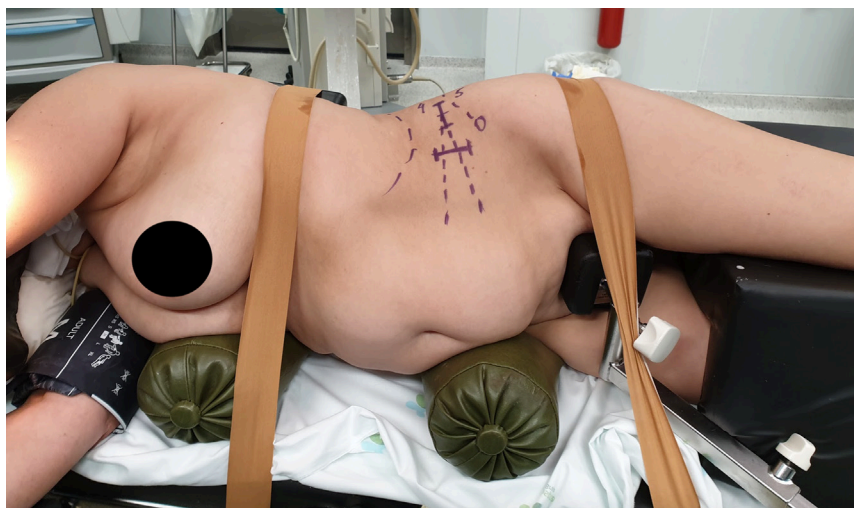

Figure 10

Lateral decubitus for lateral approach to lumbar spine.

placed on well-padded armrests, parallel to each other. The non-dependent arm may be placed in horizontal position, at the same level as the shoulder. To maintain a good body alignment, the dependent knee and hip should be flexed (Fig. 10).

In some cases, the table is slightly flexed to increase the distance between the iliac crest and the rib cage, to gain access to the lower lumbar spine. The patient is then secured with tape over the greater trochanter and chest wall (1, 7, 47).

Complications of lateral position

The major risks associated with the lateral decubitus position arise from compression/stretching of neurovascular structures and include brachial plexus injury, ulnar nerve and common peroneal nerve neuropathies and poor circulation on the dependent arm. If the neck is extremely flexed, kinking of the jugular vein, face swelling and brachial plexus injury can occur (1).

Compression between the upper thorax and the humeral head is the main mechanism of brachial plexus injury on the dependent arm. To avoid this, the axillary roll must be placed right under the chest (at the nipple's level) rather than the axilla, because an incorrect placement, under the axilla, will increase pressure on the brachial plexus. A poorly placed axillary roll can also cause poor circulation on the arm by compression of axillary and brachial arteries. The axillary roll will decrease the pressure exerted on the dependent shoulder (2, 5).

The placement of a pillow or a gel pad is mandatory between the legs and under the dependent knee to prevent compression of the common peroneal nerve against the fibular head.

Although less common than in the prone position, perioperative visual loss has been associated with lateral

decubitus position. Once the eyes are at different levels, the pressure between them is slightly different, with higher pressure on the dependent eye. For this reason, the lateral decubitus position can cause asymmetric perioperative visual loss. Neutral position of the head should be maintained to optimize venous drainage (5, 48, 49).

Conclusion

Patient position is an important step in spine surgery. Misposition can cause serious complications such as hemodynamic changes, perioperative visual loss, peripheral nerve injuries and skin ulcers. It is important that all surgical teams know the ideal patient positioning in spine surgery in order to avoid perioperative and postoperative lesions and morbidity.

ICMJE Conflict of Interest Statement

All authors declare that there is no conflict of interest that could be perceived as prejudicing the impartiality of the research reported.

Funding

This work did not receive any specific grant from any funding agency in the public, commercial or not-for-profit sector.

Patient consent

Written informed consent for publication of the patients' clinical details and clinical images has been obtained.

References

1. Gruenbaum SE, Gruenbaum BF, Shapira Y & Zlotnik A. Patient positioning for neurosurgical procedures. *Neurocritical Care Management of the Neurosurgical Patient*: Elsevier Inc. 2018. 15–24.

2. **St-Arnaud D & Paquin MJ.** Safe positioning for neurosurgical patients. *Canadian Operating Room Nursing Journal* 2009 **27** 1171–1172. (<https://doi.org/10.1016/j.aorn.2008.03.004>)
3. **Schonauer C, Bocchetti A, Barbagallo G, Albanese V & Moraci A.** Positioning on surgical table. *European Spine Journal* 2004 **13**(Supplement 1) S50–S55. (<https://doi.org/10.1007/s00586-004-0728-y>)
4. **Shen Y, Drum M & Roth S.** The prevalence of perioperative visual loss in the United States: a 10-year study from 1996 to 2005 of spinal, orthopedic, cardiac, and general surgery. *Anesthesia and Analgesia* 2009 **109** 1534–1545. (<https://doi.org/10.1213/ane.0b013e3181b0500b>)
5. **Kamel I & Barnette R.** Positioning patients for spine surgery: avoiding uncommon position-related complications. *World Journal of Orthopedics* 2014 **5** 425–443. (<https://doi.org/10.5312/wjo.v5.i4.425>)
6. **Uribe JS, Kolla J, Omar H, Dakwar E, Abel N, Mangar D & Camporesi E.** Brachial plexus injury following spinal surgery. *Journal of Neurosurgery. Spine* 2010 **13** 552–558. (<https://doi.org/10.3171/2010.4.SPINE09682>)
7. **Vieweg U & Grochulla F** *Manual of Spine Surgery* 2012. Heidelberg, Germany : SpringerVerlag. (<https://doi.org/10.1007/978-3-642-22682-3>)
8. **Hemmer C.** Surgical complications associated with cervical spine surgery. *Orthopedic Nursing* 2018 **37** 348–354. (<https://doi.org/10.1097/NOR.0000000000000498>)
9. **Cheung KMC, Mak KC & Luk KDK.** Anterior approach to cervical spine. *Spine (Phila Pa 1976)* 2012 **37** E297–E302. (<https://doi.org/10.1097/BRS.0b013e318239ccd8>)
10. **Denaro V & Di Martino A.** Cervical spine surgery: an historical perspective. *Clinical Orthopaedics and Related Research* 2011 **469** 639–648. (<https://doi.org/10.1007/s11999-010-1752-3>)
11. **Apivatthakakul REB, CGM & T.** AO principles of fracture management. *Third* 2017 717–744.
12. **Aebi M & Arlet V.** AOSpine manual principles and techniques AOSpine Manual .Thieme Medical Pub 2007 .
13. **Apostolides PJ, Vishteh AG, Galler RM & Sonntag VKH.** Technique of transoral odontoidectomy. *Minimally Invasive Spine Surgery* 2006 35–41.
14. **Aronson N, Filtzer DL & Bagan M.** Anterior cervical fusion by the smith-Robinson approach. *Journal of Neurosurgery* 1968 **29** 396–404. (<https://doi.org/10.3171/jns.1968.29.4.0397>)
15. **Kim DH** *Surgical Anatomy & Techniques to the Spine*, 2nd ed. New York: Elsevier; 2013.
16. **Gupta AK & Gelb A.** Essentials of neuroanesthesia and neurointensive care. 2008.
17. **Rozet I & Vavilala MS.** Risks and benefits of patient positioning during neurosurgical care. *Anesthesiology Clinics* 2007 **25** 631–653. (<https://doi.org/10.1016/j.andin.2007.05.009>)
18. **Mehren C, Mayer HM, Zandanell C, Siepe CJ & Korge A.** The oblique anterolateral approach to the lumbar spine provides access to the lumbar spine with few early complications. *Clinical Orthopaedics and Related Research* 2016 **474** 2020–2027. (<https://doi.org/10.1007/s11999-016-4883-3>)
19. **Vaccaro R. A.** *Spine: Core Knowledge in Orthopaedics* 2005 33–47.
20. **Pietton R, Aurgan JC, Cottin P & Begue T.** Multi-level lumbar disc replacements: review of the specificities and difficulties of the surgical technique. *Spine Research* 2015 **1** 1–6. (<https://doi.org/10.21767/2471-8173.100001>)
21. **Schubert A.** Positioning injuries in anesthesia: an update. *Advances in Anesthesia* 2008 **26** 31–65. (<https://doi.org/10.1016/j.aan.2008.07.009>)
22. **Prielipp RC, Morell RC & Butterworth J.** Ulnar nerve injury and perioperative arm positioning. *Anesthesiology Clinics of North America* 2002 **20** 589–603. ([https://doi.org/10.1016/s0889-8537\(02\)00009-3](https://doi.org/10.1016/s0889-8537(02)00009-3))
23. **Bennett J & Butterworth IJ.** Ulnar nerve Pressure – Influence of Arm Position and Relationship to somatosensory Evoked Potentials. *Anesthesiology* 1999 **2** 345–354.
24. **Winfree CJ & Kline DG.** Intraoperative positioning nerve injuries. *Surgical Neurology* 2005 **63** 5–18. (<https://doi.org/10.1016/j.surneu.2004.03.024>)
25. **American Society of Anesthesiologists Task Force on Prevention of Perioperative Peripheral Neuropathies.** Practice advisory for the prevention of perioperative peripheral neuropathies: An updated report by the American Society of Anesthesiologists Task Force on prevention of perioperative peripheral neuropathies. *Anesthesiology* 2011 **114** 741–754. (<https://doi.org/10.1097/ALN.0b013e3181fcbf3>)
26. **Jahangiri FR, Holmberg A, Vega-Bermudez F & Arlet V.** Preventing position-related brachial plexus injury with intraoperative somatosensory evoked potentials and transcranial electrical motor evoked potentials during anterior cervical spine surgery. *American Journal of Electroneurodiagnostic Technology* 2011 **51** 198–205. (<https://doi.org/10.1080/1086508X.2011.11079820>)
27. **Wang B, Wu T, Liu H, Hong Y & Meng Y.** In vitro stability analysis of the three-pronged Mayfield head clamp using pins in four different positions on the skulls. *International Journal of Clinical and Experimental Medicine* 2018 **11** 5736–5742.
28. **Wiltse LL, Bateman JG, Hutchinson RH & Nelson WE.** The paraspinous sacrospinalis-splitting approach to the lumbar spine. *Journal of Bone and Joint Surgery. American Volume* 1968 **50** 919–926. (<https://doi.org/10.2106/00004623-196850050-00004>)
29. **Feix B & Sturgess J.** Anaesthesia in the prone position. *Continuing Education in Anaesthesia Critical Care and Pain* 2014 **14** 291–297. (<https://doi.org/10.1093/bjaceaccp/mku001>)
30. **Rigamonti A, Gemma M, Rocca A, Messina M, Bignami E & Beretta L.** Prone versus knee–chest position for microdiscectomy: a prospective randomized study of intra-abdominal pressure and intraoperative bleeding. *Spine (Phila Pa 1976)* 2005 **30** 1918–1923. (<https://doi.org/10.1097/01.brs.0000176243.57869.c4>)
31. **DePasse JM, Palumbo MA, Haque M, Ebersson CP & Daniels AH.** Complications associated with prone positioning in elective spinal surgery. *World Journal of Orthopedics* 2015 **6** 351–359. (<https://doi.org/10.5312/wjo.v6.i3.351>)
32. **Cardoso MJ & Rosner MK.** Does the Wilson frame assist with optimizing surgical exposure for minimally invasive lumbar fusions? *Neurosurgical Focus* 2010 **28** E20. (<https://doi.org/10.3171/2010.1.FOCUS10325>)
33. **Anderton JM.** The prone position for the surgical patient: a historical review of the principles and hazards. *British Journal of Anaesthesia* 1991 **67** 452–463. (<https://doi.org/10.1093/bja/67.4.452>)
34. **Kumar SJ, Torres BC, Jorge JL & Quinn T.** A radiolucent spine frame: a Modification of the Relton–Hall spine frame. *Journal of Pediatric Orthopedics* 1994 **14** 383–384. (<https://doi.org/10.1097/01241398-199405000-00022>)
35. **Shriver MF, Zeer V, Alentado VJ, Mroz TE, Benzel EC & Steinmetz MP.** Lumbar spine surgery positioning complications: a systematic review. *Neurosurgical Focus* 2015 **39** E16. (<https://doi.org/10.3171/2015.7.FOCUS15268>)
36. **Boyle SL, Unger Z, Kulkarni V, Massicotte EM & Venkatraghavan L.** Prone positioning of patients with cervical spine pathology. *J Neuroanaesth Crit Care* 1999 **7** 70–76.

- 37. Kwee MM, Ho YH & Rozen WM.** The prone position during surgery and its complications: a systematic review and evidence-based guidelines. *International Surgery* 2015 **100** 292–303. (<https://doi.org/10.9738/INTSURG-D-13-00256.1>)
- 38. Nickels TJ, Manlapaz MR & Farag E.** Perioperative visual loss after spine surgery. *World Journal of Orthopedics* 2014 **5** 100–106. (<https://doi.org/10.5312/wjo.v5.i2.100>)
- 39. Kamming D & Clarke S.** Postoperative visual loss following prone spinal surgery. *British Journal of Anaesthesia* 2005 **95** 257–260. (<https://doi.org/10.1093/bja/aei173>)
- 40. Lee LA.** Perioperative visual loss and anesthetic management. *Current Opinion in Anaesthesiology* 2013 **26** 375–381. (<https://doi.org/10.1097/ACO.0b013e328360dcd9>)
- 41. Mendoza-Popoca CU & , Suárez-Morales M , .** Posterior spinal surgery and prone position: Is Kneeling Better for Pulmonary Mechanics ? *Revista Mexicana de Anestesiología* 2008 **31** 88–92.
- 42. Mirovsky Y & Neuwirth M.** Injuries to the lateral femoral cutaneous nerve during spine surgery. *Spine (Phila Pa 1976)* 2000 **25** 1266–1269. (<https://doi.org/10.1097/00007632-200005150-00011>)
- 43. Dahab R, Barrett C, Pillay R & De Matas M.** Anterior thigh compartment syndrome after prone positioning for lumbosacral fixation. *European Spine Journal* 2012 **21** (Supplement 4) S554–S556. (<https://doi.org/10.1007/s00586-012-2282-3>)
- 44. Mobbs RJ, Phan K, Malham G, Seex K & Rao PJ.** Lumbar interbody fusion: techniques, indications and comparison of interbody fusion options including PLIF, TLIF, MI-TLIF, OLIF/ATP, LLIF and ALIF. *Journal of Spine Surgery (Hong Kong)* 2015 **1** 2–18. (<https://doi.org/10.3978/j.issn.2414-469X.2015.10.05>)
- 45. Kusano S, Dezawa A, Yoshihara K & Katoh K.** Anterolateral approach to the lumbar spine. *State Art Minim Invasive Spine Surg* 2006 107–116.
- 46. Malham GM, Wagner TP & Claydon MH.** Anterior lumbar interbody fusion in a lateral decubitus position: technique and outcomes in obese patients. *Journal of Spine Surgery* 2019 **5** 433–442. (<https://doi.org/10.21037/jss.2019.09.09>)
- 47. Afzal S, Sultan A, Iqbal M & Dhar SA.** Lateral decubitus position in spinal surgery – Current concepts. *JK Practitioner* 2007 **14** 110–112.
- 48. Lee LA, Roth S, Posner KL, Cheney FW, Caplan RA, Newman NJ & Domino KB.** The American society of anesthesiologists postoperative visual loss registry: analysis of 93 spine surgery cases with postoperative visual loss. *Anesthesiology* 2006 **105** 652–652. (<https://doi.org/10.1097/00000542-200610000-00007>)
- 49. Heitz JW & Audu PB.** Asymmetric postoperative visual loss after spine surgery in the lateral decubitus position. *British Journal of Anaesthesia* 2008 **101** 380–382. (<https://doi.org/10.1093/bja/aen163>)