

An Evaluation of the Safety and Feasibility of Adenosine-assisted Clipping Surgery for Unruptured Cerebral Aneurysms: Study Protocol

Tomohito HISHIKAWA,¹ Satoshi MURAI,¹ Masafumi HIRAMATSU,¹ Jun HARUMA,¹ Kazuhiko NISHI,¹ Yuki EBISUDANI,¹ Yu SATO,¹ Takao YASUHARA,¹ Kenji SUGIU,¹ Kazuyoshi SHIMIZU,² Motomu KOBAYASHI,² Koji NAKAGAWA,³ Aya KIMURA-ONO,⁴ Katsuyuki HOTTA,⁴ Hiroshi MORIMATSU,² and Isao DATE¹

¹*Department of Neurological Surgery, Okayama University Graduate School of Medicine, Dentistry and Pharmaceutical Sciences, Okayama, Okayama, Japan*

²*Department of Anesthesiology and Resuscitology, Okayama University Graduate School of Medicine, Dentistry and Pharmaceutical Sciences, Okayama, Okayama, Japan*

³*Department of Cardiovascular Medicine, Okayama University Graduate School of Medicine, Dentistry and Pharmaceutical Sciences, Okayama, Okayama, Japan*

⁴*Center for Innovative Clinical Medicine, Okayama University Hospital, Okayama, Okayama, Japan*

Abstract

The effectiveness of adenosine-induced flow arrest in surgical clipping for the cerebral aneurysms with difficulties in temporary clip placement to the proximal main trunk has been reported. This is the first clinical trial to evaluate the safety and feasibility of adenosine-assisted clipping surgery for unruptured cerebral aneurysms (UCAs) in Japan. The inclusion criteria are as follows: patients over 20 years old, patients who agree to be enrolled in this study after providing informed consent, patients who undergo clipping surgery for UCA in our institute, and patients in whom the surgeons (T.H. or I.D.) judge that decompression of the aneurysm is effective. The primary endpoint is a modified Rankin Scale (mRS) score 30 days after surgery. We plan to enroll 10 patients in this study. The original protocol of adenosine administration was established in this trial. Herein, we present the study protocol.

Keywords: adenosine, clipping, unruptured cerebral aneurysm

Introduction

The prevalence of unruptured cerebral aneurysms (UCAs) and the annual rate of UCA rupture in Japanese cohort has been reported to be approximately 3% and 0.9%, respectively.^{1,2)} Considering the high mortality in cases of UCA rupture, preventive treatment for UCAs is recommended based on the size, shape, and location of UCAs. Surgical clipping plays a central role in preventing UCA rupture. Decompressing aneurysms and visualizing

the anatomy around them during surgical clipping are important to obliterate aneurysms completely and to preserve perforators close to aneurysms. Large and giant CAs have been reported to have a high treatment-related morbidity rate³⁾ and the decompression of aneurysms is necessary for safe clipping. The placement of a temporary clip at the main trunk proximal to aneurysms is usually performed to decompress aneurysms. Large aneurysms, deep aneurysm location, and adjacency to the skull base bone can prevent the securing of the main trunk proximal to aneurysms, however. Severe atherosclerosis of the main trunk proximal to aneurysms may cause insufficient occlusion of the proximal main trunk by the temporary clip and cerebral infarction due to thrombogenesis. Recently, the effectiveness of adenosine-induced transient

Received January 20, 2021; Accepted March 15, 2021

Copyright© 2021 The Japan Neurosurgical Society
This work is licensed under a Creative Commons Attribution-NonCommercial-NoDerivatives International License.

asystole for cases unsuitable for temporary clip placement in surgical clipping has been reported.^{4–10} In Japan, adenosine is approved for various symptoms related to complications following head trauma, heart failure, muscular dystrophy, acute poliomyelitis, cerebral palsy, progressive spinal amyotrophy, accommodative asthenopia, tinnitus, hearing loss, chronic gastritis, and chronic hepatic disease, and adenosine-induced decompression of UCAs is an off-label use. The aim of this specific clinical trial is to investigate whether adenosine is a safe and viable alternative to temporary clip placement in clipping surgery for UCAs.

Materials and Methods

Endpoints

The primary endpoint is a modified Rankin Scale (mRS) score 30 days after surgery. The secondary endpoints are (1) the degree of aneurysm obliteration by the clip, (2) the total dosage of adenosine, (3) the time between adenosine administration and termination of clipping, (4) mRS scores at discharge and at 90 days after surgery, (5) the prevalence of maintaining systolic blood pressure at less than 60 mmHg for between 30 s and 1 min by adenosine administration and its duration, (6) adverse events related to adenosine (paroxysmal atrial fibrillation [Paf] within 24 h after adenosine administration, prolonged hypotension of less than 60 mmHg in systolic blood pressure for more than 1 min, and the elevation of high-sensitivity cardiac troponin T), and (7) other adverse events (a reduction of amplitude in the motor evoked potential [MEP] and somatosensory evoked potential [SEP], new infarction detected by magnetic resonance imaging on the day after surgery).

Inclusion criteria

(1) Patients over 20 years old; (2) patients who agree to be enrolled in this study after providing informed consent; (3) patients who undergo clipping surgery for UCA in our institute; (4) patients in whom the surgeons (T.H. or I.D.) judge that decompression of the aneurysm is effective for one of the following reasons: ≥ 7 mm in aneurysm size; ≥ 4 mm in neck size (≤ 2 in dome/neck ratio); adhesion of branches, perforators, or veins to the aneurysm; being buried in the brain; atherosclerosis of the aneurysm; and existence of a daughter sac.

Exclusion criteria

(1) Significant coronary artery stenosis; (2) past history of ischemic heart disease; (3) moderate and severe aortic valve stenosis; (4) obstructive hypertrophic cardiomyopathy; (5) history of Paf; (6)

atrioventricular (AV) block; (7) asthma; (8) chronic obstructive pulmonary disease; (9) patients over 80 years old; (10) pregnant or breastfeeding women; (11) patients who simultaneously undergo clipping surgery for multiple aneurysms in a single operation; and (12) patients who are deemed to be uninterested or to have possible interruptions in the assessment by the physician.

Study design

This is a single-center, single-arm study to evaluate the safety and feasibility of adenosine-assisted clipping surgery for UCAs. This study was approved by the Okayama University Certified Review Board (approved number: CRB20-003) and was registered in the Japan Registry of Clinical Trials (jRCT, registration no. jRCTs061200023).

Recruitment and setting

Figure 1 shows the flow chart of recruitment for this study. Screening includes blood examination, electrocardiogram, chest X-ray, spirometry, high-sensitivity cardiac troponin T, and cardiovascular medicine and anesthesiology consultations. Coronary artery stenosis is screened by stress electrocardiogram.

Treatment and assessment schedule

The protocol of adenosine administration was established to maintain systolic blood pressure at less than 60 mmHg for between 30 s and 1 min in this study (Fig. 2). In cases of cessation of adenosine administration, decompression of the aneurysm is performed by applying a temporary clip to the proximal artery to the aneurysm. If redoing the clip application is needed, a temporary clip is used to decompress the aneurysm without a second administration of adenosine. Undiluted adenosine is rapidly

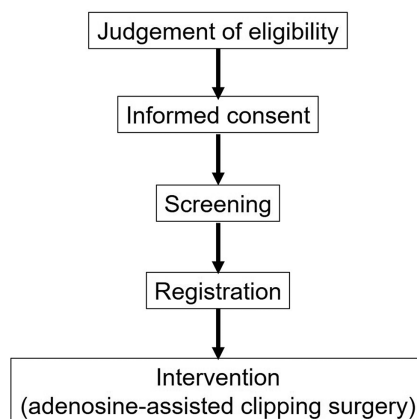


Fig. 1 The flow chart of recruitment in this study

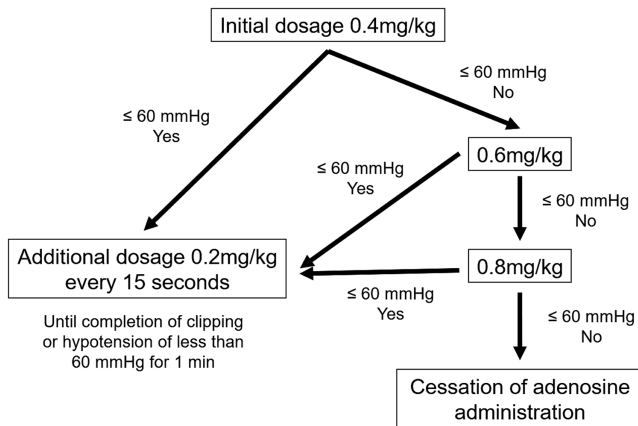


Fig. 2 The protocol of adenosine administration

administered through a central venous catheter in a manual fashion. As adenosine is more likely to cause asystole or bradycardia due to sinus arrest or AV block, electrocardiogram, arterial pressure, and central venous pressure are carefully monitored during the operation and transcutaneous pacing and related inotrope are prepared. Both MEP and SEP monitoring are performed during the procedure and amplitude less than 30% compared to the control in MEP and less than 50% in SEP are judged as adverse events. The assessment schedule after surgery is presented in Fig. 3. High-sensitivity cardiac troponin T is checked to evaluate myocardial ischemia on postoperative day 1. The elevation of high-sensitivity cardiac troponin T is defined as more than 0.014 ng/mL on postoperative day 1, and an increase of more than 20% compared to the preoperative value.¹¹⁾ Electrocardiogram is monitored 24 h after the operation to detect Paf. Brain magnetic resonance imaging is performed to assess ischemic lesions on postoperative day 1. The degree of aneurysm obliteration by the clip is evaluated by three-dimensional computed tomography angiography on postoperative days 4–7, and is divided into three categories: complete clipping, residual neck, and residual dome.

Statistical considerations

We plan to enroll 10 patients in this study, in light of the number of annual cases who undergo clipping for UCAs in our institute and the survey period. In this study, statistical description is mainly performed due to the small sample size. The point estimate and 95% confidence interval are calculated as an analysis of the primary outcome. The number of adverse events from the point of adenosine administration to the day after surgery is aggregated for the safety assessment.

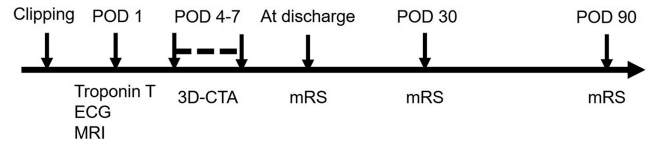


Fig. 3 Post-surgical assessment schedule

Discussion

Adenosine is a nucleoside analogue that binds to cardiac A1 receptors and his binding causes AV nodal blockage and bradycardia. To achieve hypotension 10–20 s after adenosine bolus injection and to recover normotension promptly due to a short half-life of 0.6–20 s is advantageous for the decompression of aneurysms in clipping surgery.⁸⁾ Groff et al. first reported adenosine use in clipping surgery for a basilar artery aneurysm.¹²⁾ Recently, several studies have reported the effectiveness of adenosine-induced flow arrest in surgical clipping for aneurysms with challenging temporary clip placements to the proximal main trunk due to large aneurysm size, deep aneurysm location, adjacency to the skull base bone, premature aneurysm rupture, and severe atherosclerosis of the main trunk.^{5,6,9,13)} The American Heart Association/American Stroke Association includes adenosine for temporary cardiac arrest as a technical advance in the guidelines for the management of patients with UCAs.¹⁴⁾

The use of adenosine to decompress aneurysms is not yet approved and this is the first clinical trial to evaluate the safety and feasibility adenosine-assisted clipping surgery for UCAs in Japan. This study investigates whether adenosine is a viable alternative to temporary clip placement in clipping surgery. As it is possible that cardiopulmonary function is damaged in patients with ruptured aneurysms, this study only included patients with UCAs. Most patients with UCAs have a preoperative mRS score of 0. When considering surgical clipping for UCAs as a preventive treatment, preserving the preoperative mRS score after surgery is one of the goals of UCA treatment. As such, the mRS score 30 days after adenosine use was set as a primary endpoint in this study. The original protocol of adenosine administration was established in this trial. This protocol was based on previous reports^{4–9,13)} and advice from anesthesiologists and cardiovascular medicine clinicians. To determine the optimal dose of adenosine in Japanese patients, it is important to assess the adequacy of this protocol. Some papers reported temporary arrhythmia and the elevation of troponin T as adverse events.^{4,5,7–9)} In addition to these adverse

cardiac events, the ischemic influence of adenosine-induced hypotension on the central nervous system during surgery is monitored with both SEP and MEP in this study.

This study is the first step in adenosine-assisted clipping surgery for UCAs. If adenosine use is established as a viable alternative to the placement of a temporary clip, adenosine could be utilized in aneurysms that present challenges in the placement of a temporary clip.

Trial status

The trial is currently in the recruitment phase. Recruitment commenced in October 2020 and data collection will be completed by September 30, 2023.

Acknowledgments

We are grateful to Dr. Toru Miyoshi and Prof. Hiroshi Ito at the Department of Cardiovascular Medicine in Okayama University Graduate School of Medicine, Dentistry and Pharmaceutical Sciences for their outpatient care. We thank Mrs. Yoko Sakamoto for her technical support.

Conflicts of Interest Disclosure

The authors have no interests to declare.

References

- 1) UCAS Japan Investigators, Morita A, Kirino T, et al.: The natural course of unruptured cerebral aneurysms in a Japanese cohort. *N Engl J Med* 366: 2474–2482, 2012
- 2) Harada K, Fukuyama K, Shirouzu T, et al.: Prevalence of unruptured intracranial aneurysms in healthy asymptomatic Japanese adults: differences in gender and age. *Acta Neurochir (Wien)* 155: 2037–2043, 2013
- 3) Park W, Chung J, Ahn JS, Park JC, Kwun BD: Treatment of large and giant middle cerebral artery aneurysms: risk factors for unfavorable outcomes. *World Neurosurg* 102: 301–312, 2017
- 4) Bebawy JF, Gupta DK, Bendok BR, et al.: Adenosine-induced flow arrest to facilitate intracranial aneurysm clip ligation: dose-response data and safety profile. *Anesth Analg* 110: 1406–1411, 2010
- 5) Bendok BR, Gupta DK, Rahme RJ, et al.: Adenosine for temporary flow arrest during intracranial aneurysm surgery: a single-center retrospective review. *Neurosurgery* 69: 815–820; discussion 820–821, 2011
- 6) Guinn NR, McDonagh DL, Borel CO, et al.: Adenosine-induced transient asystole for intracranial aneurysm surgery: a retrospective review. *J Neurosurg Anesthesiol* 23: 35–40, 2011
- 7) Lee SH, Kwun BD, Kim JU, et al.: Adenosine-induced transient asystole during intracranial aneurysm surgery: indications, dosing, efficacy, and risks. *Acta Neurochir (Wien)* 157: 1879–1886; discussion 1886, 2015
- 8) Dasai VR, Rosas AL, Britz GW: Adenosine to facilitate the clipping of cerebral aneurysms: literature review. *Stroke Vasc Neurol* 2: 204–209, 2017
- 9) Intarakhao P, Thiarawat P, Rezai Jahromi B, et al.: Adenosine-induced cardiac arrest as an alternative to temporary clipping during intracranial aneurysm surgery. *J Neurosurg* 129: 684–690, 2018
- 10) Meling TR, Lavé A: What are the options for cardiac standstill during aneurysm surgery? A systematic review. *Neurosurg Rev* 42: 843–852, 2019
- 11) Toda H, Nakamura K, Nakagawa K, et al.: Diastolic dysfunction is a risk of perioperative myocardial injury assessed by high-sensitivity cardiac troponin T in elderly patients undergoing non-cardiac surgery. *Circ J* 82: 775–782, 2018
- 12) Groff MW, Adams DC, Kahn RA, Kumbar UM, Yang BY, Bederson JB: Adenosine-induced transient asystole for management of a basilar artery aneurysm. Case report. *J Neurosurg* 91: 687–690, 1999
- 13) Niiya Y, Ito M, Itosaka H, et al.: Efficacy of adenosine triphosphate-induced transient cardiac arrest for deflation of cerebral aneurysms during clipping surgery. *Jpn J Neurosurg (Tokyo)* 23: 889–896, 2014
- 14) Thompson BG, Brown RD, Amin-Hanjani S, et al.: Guidelines for the management of patients with unruptured intracranial aneurysms: a guideline for healthcare professionals from the American Heart Association/American Stroke Association. *Stroke* 46: 2368–2400, 2015

Corresponding author: Tomohito Hishikawa, MD

Department of Neurological Surgery, Okayama University Graduate School of Medicine, Dentistry and Pharmaceutical Sciences, 2-5-1 Shikatacho, Kita-ku, Okayama, Okayama 700-8558, Japan.
e-mail: t-hishi@md.okayama-u.ac.jp