



Contents lists available at ScienceDirect

Gynecology and Minimally Invasive Therapy

journal homepage: www.e-gmit.com

Review article

Laparoscopic technique of para-aortic lymph node dissection: A comparison of the different approaches to trans- versus extraperitoneal para-aortic lymphadenectomy

Soshi Kusunoki ^a, Kuan-Gen Huang ^{b, *}, Angelito Magno ^c, Chyi-Long Lee ^b^a Department of Obstetrics and Gynecology, Faculty of Medicine, Juntendo University, Tokyo, Japan^b Department of Obstetrics and Gynecology, Chang Gung Memorial Hospital at Linkou and Chang Gung University College of Medicine, Kweishan, Taoyuan, Taiwan^c Department of Obstetrics and Gynecology, University of Perpetual Help Medical Center, Las Pinas and De La Salle University Medical Center, Cavite, Philippines

ARTICLE INFO

Article history:

Received 19 August 2015
 Received in revised form
 29 December 2015
 Accepted 4 January 2016
 Available online 8 February 2016

Keywords:

extraperitoneal
 para-aortic lymphadenectomy
 transperitoneal

ABSTRACT

Since Dr Dargent first reported endoscopic surgery using retroperitoneal pelvicoscopy to perform pelvic lymph node sampling in 1987, many literature reviews on the safety and feasibility of laparoscopic staging surgery of gynecologic malignancies have been published. However, the procedure of laparoscopic lymphadenectomy is more difficult to perform due to the limited surgical space and associated technical problems. Especially in the para-aortic lymphadenectomy procedure, there are many barriers to overcome in the surgical field, learning curve, and technique. We present a review of lymphadenectomy, especially para-aortic lymphadenectomy.

Copyright © 2016, The Asia-Pacific Association for Gynecologic Endoscopy and Minimally Invasive Therapy. Published by Elsevier Taiwan LLC. This is an open access article under the CC BY-NC-ND license (<http://creativecommons.org/licenses/by-nc-nd/4.0/>).

Introduction

Endoscopic oncologic surgery has about 2 decades of history and spread rapidly with remarkable progress. Minimal invasive surgery offers benefits over laparotomy in terms of fewer operative complications, lesser adhesion formation, shorter hospital stay, and maintenance of quality of life, including reduced analgesia requirements and earlier return to normal activities. In 1987, the French gynecologic oncologist Dr Daniel Dargent¹ was the first to report endoscopic surgery in the gynecologic oncologic field by using retroperitoneal pelvicoscopy in performing pelvic lymph node sampling in patients with cervical cancer. In addition, Querleu et al² reported 39 cases of Stage Ia cervical cancer, who underwent laparoscopic transperitoneal pelvic lymphadenectomy in 1991. Subsequently, Childers et al^{3,4} and

Nezhat et al⁵ first reported the efficacy of transperitoneal para-aortic lymphadenectomy for staging surgery of invasive gynecologic malignancies. Later on, Vasilev and McGonigle⁶ started an entirely extraperitoneal laparoscopic technique for para-aortic lymphadenectomy in a pig model, followed by application to humans in 1996, and Dargent et al⁷ developed this procedure systematically.

Abdominal lymphadenectomy with a large incision may lead to some complications, such as abdominal incisional pain, bleeding, infection, or intestinal obstruction, not to mention the delay it will cause to postoperative adjuvant therapy, if indicated, waiting for the large wound to heal. Compared with laparotomy, laparoscopic lymphadenectomy can decrease these complications. There are many literatures about the safety and feasibility of laparoscopic staging surgery in gynecologic malignancies.^{8,9} However, laparoscopic lymphadenectomy is more difficult to perform due to the limited surgical space and associated technical problems. Especially in the procedure of para-aortic lymphadenectomy, there are many barriers to overcome in the surgical field, learning curve, and technique. Here, we present a review of lymphadenectomy, especially para-aortic lymphadenectomy.

Conflicts of interest: The authors have no conflicts of interest relevant to this article.

* Corresponding author. Department of Obstetrics and Gynecology, Chang Gung Memorial Hospital, Linkou Medical Center and Chang Gung University College of Medicine, 5, Fu-Hsin Street, Kwei-Shan, Tao-Yuan 333, Taiwan.

E-mail address: kghuang@ms57.hinet.net (K.-G. Huang).

<http://dx.doi.org/10.1016/j.gmit.2016.01.003>

2213-3070/© 2016, The Asia-Pacific Association for Gynecologic Endoscopy and Minimally Invasive Therapy. Published by Elsevier Taiwan LLC. This is an open access article under the CC BY-NC-ND license (<http://creativecommons.org/licenses/by-nc-nd/4.0/>).

Materials and methods

The PubMed database was used to collect the literature published up to November 2014. We searched the database for relevant articles using the following terms: a combination of “laparoscopy,” “para-aortic,” and “lymphadenectomy” or “transperitoneal lymphadenectomy” or “extraperitoneal lymphadenectomy,” or a combination of “transperitoneal” and “extraperitoneal.” Case reports were excluded.

Results and discussion

Approach to performing para-aortic lymphadenectomy

There are two approaches to para-aortic lymphadenectomy: transperitoneal and extraperitoneal. The transperitoneal approach offers a greater working space and familiar landmarks, but sometimes requires bowel mobilization. The advantages of the extraperitoneal approach include operative feasibility in spite of previous abdominal surgery, decreased risk of direct bowel injury, and bowel adhesion formation. The disadvantages are a small working space, limited landmarks, and the risk of becoming disoriented. Childers et al³ introduced transperitoneal para-aortic lymphadenectomy using four trocars. One large 10-mm trocar was placed in the umbilicus and one in the midline near the symphysis pubis. Two 5-mm trocars were placed laterally midway between the umbilicus and the anterior superior iliac crest. Since the evolution of this approach, many authors have used five trocars: one at the umbilicus, one at the suprapubic area, two at the lower quadrants, and a 10-mm trocar at the left upper quadrant, which is used as a retractor or for removal of lymph nodes (Figure 1A).^{10,11} In another report, Lee et al^{12,13} reported the efficiency with five trocars (two 10-mm and three 5-mm). The 10-mm laparoscope was introduced at the midpoint between the umbilicus and the xiphoid process (Lee–Huang point), and all other ancillary ports were inserted laterally (Figure 1B). They reported the safety and feasibility in the field of gynecologic malignancies.^{13,14}

Vasilev and McGonigle,⁶ following Dargent et al⁷ and Querleu et al,¹⁵ reported that extraperitoneal lymphadenectomy is preferred as it is more effective in decreasing the formation of adhesions with fewer resultant bowel complications than the transperitoneal approach. The surgical approach introduced by Vasilev and McGonigle⁶ is as follows. A 15-mm incision was made just below the midcostal margin. The extraperitoneal space was developed using a balloon dissector inflated with 500–1000 cc of air. Then the trocar was replaced with a 10-mm trocar and pneumoretroperitoneum was created. An additional two 5-mm trocars were placed in the left subcostal region.

Dargent et al⁷ evaluated the accuracy of the left extraperitoneal route in 21 cases, by comparing the transperitoneal route in nine cases with the bilateral extraperitoneal route in 14 cases. There was no statistically significant difference in the total number of aortic nodes removed; however, the operating time was significantly shortened using the left extraperitoneal route. They concluded that infrarenal para-aortic lymphadenectomy by the left extraperitoneal route was feasible. Recently, the surgical approach has been improved and many authors reported better techniques.^{16,17} The most reported surgical techniques are as follows. The initial entry is placed at the umbilicus to evaluate the abdominal cavity. Subsequently, 10-mm trocars are placed 3–4 cm medial to the left iliac spine, another 10-mm or 5-mm trocar is inserted at the external clavicular line under the subcostal margin approximately 5 cm above the initial point, and one more 5-mm or 10-mm trocar is placed 3–5 cm cephalad to the previous trocar (Figure 1C).^{16,17} Through the first incision, the surgeon uses his/her index finger

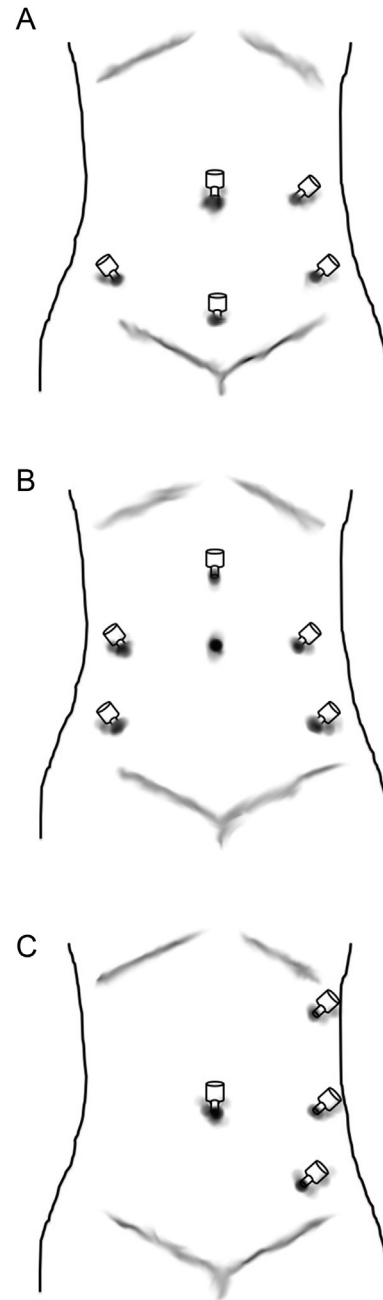


Figure 1. (A, B) Trocar placements for transperitoneal para-aortic lymphadenectomy. (C) Trocar placement for extraperitoneal para-aortic lymphadenectomy.

to open the extraperitoneal space between the peritoneum and muscles of the abdominal wall. A balloon-tipped trocar is then inserted and used to visualize the extraperitoneal space. Carbon dioxide is used to insufflate the extraperitoneal space while exsufflating the peritoneal cavity at the same time.

Comparison between extraperitoneal and transperitoneal lymphadenectomy

Since the extra- and transperitoneal lymphadenectomy were introduced, Weiser et al¹⁸ studied 284 patients with Stage IIB or IIIB cervical carcinoma who underwent surgical staging, including selective para-aortic lymphadenectomy, followed by pelvic

irradiation with or without para-aortic irradiation. Of 284 patients, 128 underwent extraperitoneal and 156 transperitoneal procedures. There were similar sensitivities in detecting nodal spread and no significant differences in the frequency of surgical complications that could be detected between these groups; however, both bowel obstruction and nonobstructive enteric injuries were observed significantly more often in the transperitoneal group than in the extraperitoneal group. Many authors support that extraperitoneal lymphadenectomy reduced the complication rates associated with less long-term radiation morbidity and can be the standard surgical staging procedure in patients with locally advanced cervical cancer.^{19,20} Occelli et al²¹ compared the risk of adhesion formation and the site of postoperative adhesions between trans- and extraperitoneal laparoscopic para-aortic lymphadenectomy by randomly allocating 33 pigs into two groups. Although no statistically significant difference was observed between the two techniques in terms of the operating time, number of lymph nodes removed, and intra- and postoperative morbidity, the overall adhesion rates were 76% in the transperitoneal group and 43.33% in the extraperitoneal group. They showed that extraperitoneal laparoscopy leads to significantly fewer adhesions and suggested that the radiation field can be evaluated by this technique for the staging of advanced cervical carcinoma. Their study is the only randomized prospective study about the comparison between extra- and transperitoneal lymphadenectomy reported in the literature to date. Subsequently, the same authors examined the learning curves between these groups in another report.²² The learning curves of the 10th procedure were necessary for each surgeon and for each approach to become proficient, and they concluded that extraperitoneal lymphadenectomy has a steep learning curve similar to that for transperitoneal laparoscopy.

By contrast, Fowler et al²³ reported the converse result of adhesion rates. They investigated pelvic adhesion formation in a porcine model after pelvic lymphadenectomy, and eight of 10 (80%) and five of nine (56%) animals in the trans- and extraperitoneal groups, respectively, had no adhesions after pelvic lymphadenectomy.

Pakish et al²⁴ compared the surgical outcomes of extraperitoneal laparoscopic, transperitoneal laparoscopic, and robotic transperitoneal para-aortic lymphadenectomy in endometrial cancer staging. The median number of para-aortic lymph nodes removed was higher in the extraperitoneal group than in the transperitoneal laparoscopic and robotic groups. This pattern held true within obese patients, and they suggested that the use of an extraperitoneal operative technique is adequate for patients with a higher body mass index. Morales et al¹⁹ compared these approaches in gynecologic cancer patients and reported that the extraperitoneal group had a higher rate of positive nodes compared with the transperitoneal group.

So far, there are no significant differences in the frequency of surgical complications between trans- and extraperitoneal

lymphadenectomy, and the opinions about which approach is superior with respect to the adhesion rate are different and contradicting among journals (Table 1). However, the extraperitoneal approach seems to allow better exposure of the surgical field and removal of lymph nodes.

Anatomy and surgical procedures of para-aortic lymphadenectomy

Para-aortic lymph nodes in the gynecologic oncologic field are subgrouped into b1 and b2 lymph nodes; b1 lymph nodes are located between the lower margin of the left renal vein and the upper margin of the inferior mesenteric artery (IMA), whereas b2 lymph nodes are located between the upper margin of the IMA and the bifurcation of the abdominal aorta. The procedure of para-aortic lymphadenectomy is divided into two types: right-sided and left-sided para-aortic lymphadenectomy with respect to the center of the aorta. Right-sided para-aortic lymphadenectomy is performed by dissecting the lymph nodes of the precaval and paracaval area up to the level of the origin of the right ovarian vein in the inferior vena cava (IVC) or the right renal vein. Conversely, left-sided para-aortic lymphadenectomy is performed by dissecting the lymph nodes on the aorta from the level of bifurcation to the left renal vein.

The abdominal aorta has important branch vessels, such as the renal artery, ovarian artery, IMA, lumbar artery, and median sacral artery, and has variations as well.²⁵ The IVC also has variations. Possover et al²⁶ evaluated the anatomy of the infrarenal portion of the IVC by dividing it into three portions: Level 1 is the area of the bifurcation of the vena cava, Level 2 is the area between the bifurcation and the IMA, and Level 3 is the area between the IMA and the right ovarian vein. The mean numbers of tributaries were 3 in Level 1, 1.7 in Level 2, and 1 in Level 3.

The most important and basic requirements of lymphadenectomy are the maintenance of a clear surgical field and precise anatomy of vessels in case of an accidental injury. In case of a vessel injury, compression by a gauze to decrease the bleeding is necessary. Then skeletonization of the vessel following the detection of the bleeding point has to be performed. If the procedures prove difficult, the use of a hemostatic agent can be considered. An injury of a larger vessel may require suture repair with monofilament and nonabsorbable sutures. Removal of positive lymph nodes has to be performed taking care not to cause any injury to the main vessels, especially the IVC, due to affluent artery and vein to lymph nodes.

Procedure of transperitoneal para-aortic lymphadenectomy

Para-aortic lymphadenectomy is started by incision of the peritoneum covering the upper part of the right common iliac artery. An incision along the aortic bifurcation to the level of the left renal vein is made over the right side of the descending aorta because the origin of IMA is located on the left side of the aorta. In the case of an obscure surgical field due to the small bowel,

Table 1
Comparison between extraperitoneal and transperitoneal lymphadenectomy.

	Extraperitoneal lymphadenectomy	Transperitoneal lymphadenectomy	Learning curve	Adhesion formation	Lymph nodes removed	Blood loss	Operative time	Postoperative complication	Conversion to open surgery
Morales et al ¹⁹	28	19			NS		T > E ($p < 0.01$)	NS	
Occelli et al ^{21,22}	33	33	NS	T > E ($p < 0.05$)	NS		NS	NS	
								Lymphocele: E > T ($p < 0.005$)	
Fowler et al ²³	10	10		NS					
Pakish et al ²⁴	34	108			E > T ($p < 0.01$)	NS	T > E ($p < 0.01$)	NS	NS

E = extraperitoneal lymphadenectomy; NS = not significant; T = transperitoneal lymphadenectomy.

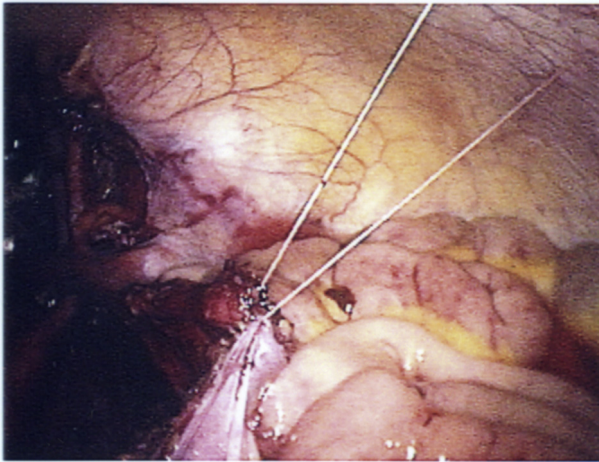


Figure 2. Elevation of the peritoneum to form a tent in the case of an obscure surgical field.

suturing the edge of the incised peritoneum and elevating it to form a tent can be considered (Figure 2). Right-sided para-aortic lymphadenectomy is followed by the left-side procedure (Figure 3).

Dissection of lymph nodes along the vena cava is carried out cranially up to the level of the right ovarian vein. Right-sided para-aortic lymphadenectomy has to be performed with attention to the right ureter, affluent vessels to lymph nodes at the IVC, and the location of lumbar veins. The right ureter is identified and pushed laterally. The anterior of the IVC contains some affluent veins, which are coagulated and cut to prevent bleeding using a vessel sealing device or bipolar coagulation. The surrounding tissues are dissected meticulously by blunt suction dissection to isolate lumbar vessels and affluent veins. Especially in the dissection of intercavo- and retroaortic lymph nodes, care should be taken not to cause any injury to the lumbar vessels. As we mentioned, the IVC has variations between the lumbar veins and the left ovarian vein. The lumbar veins are located symmetrically and are the landmarks during left-sided para-aortic lymphadenectomy. The abdominal aortic plexus is situated on the sides and front of the aorta between the origins of the superior and inferior mesenteric arteries. The hypogastric nerve enters the sympathetic chain at T10–L2. These routes are essential for contraction of the internal urethral

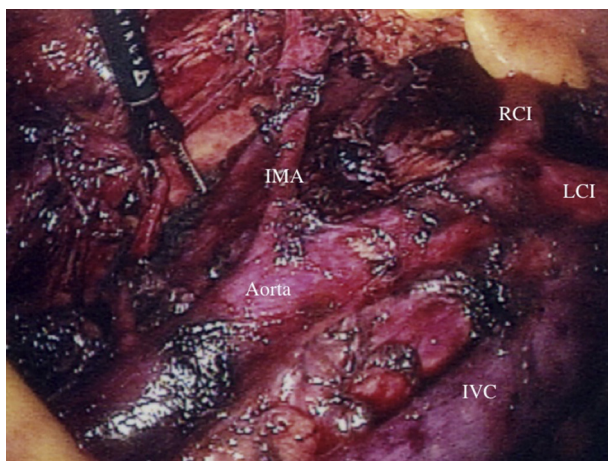


Figure 3. Completed laparoscopic transperitoneal para-aortic lymphadenectomy. IMA = inferior mesenteric artery; IVC = inferior vena cava; LCI = left common iliac artery; RCI = right common iliac artery.

sphincter and, in male patients, for ejaculation function. Injuries of the hypogastric nerve may cause urinary dysfunction for female patients and lead to incontinence, so preservation of the hypogastric nerve should be considered.

As for left-sided para-aortic lymphadenectomy, the left ureter and the ovarian vein are the lateral borders of lymph node dissection. The left ureter is identified first and pushed laterally to avoid any injury. The left renal vein receives a branch to the left second lumbar vein at the origin of the left ovarian vein. Lymphadenectomy in this area has to be performed carefully. Injury of these veins will lead to a large amount bleeding, and repair may be difficult and a meticulous procedure is needed.

Retroaortic lymph nodes are dissected using suction with special attention to the lumbar vessels and affluent vein. A lumbar artery injury may cause infarction of the spinal cord. The level of the left renal vein, the upper limit of infrarenal lymphadenectomy, is coagulated and cut with a clip to prevent chylorrhea.

Procedure of extraperitoneal para-aortic lymphadenectomy

Extraperitoneal lymphadenectomy is less commonly performed as compared with transperitoneal para-aortic lymphadenectomy because it has limited landmarks, less working space, and the risk of becoming disoriented, so landmarks are needed to confirm the orientation. These include identification of the psoas muscle, iliac artery, ureter, and ovarian vessels. Then an incision is made to the level of the left renal vein. Extraperitoneal lymphadenectomy is started by separating the anterior abdominal wall peritoneum to the preperitoneal fat and muscles at the upper quadrant trocars until enough working space is created and until the mentioned landmarks are seen. Dissection of the para-aortic and paracaval nodes and the surrounding tissues is performed cranially from the common iliac to renal vein. Close attention should be given to the left second lumbar vein at the origin of the left ovarian vein to avoid injury and severe bleeding. After dissection of the left lateral chain, preaortic lymphadenectomy is performed caudally, toward the aortic bifurcation and common iliac artery. Exposure of the IMA at its origin is necessary for the dissection.

In the same way as in case of transperitoneal para-aortic lymphadenectomy, dissection of right-sided para-aortic lymph nodes is performed cranially up to the level of the right renal vein with attention to the affluent vessels at the IVC and lumbar veins. Extraperitoneal para-aortic lymphadenectomy has a dead angle and a camera at the multiport site is needed during this procedure.

Role of para-aortic lymphadenectomy in endometrial cancer

Para-aortic lymphadenectomy has an important role to evaluate the surgical staging. The International Federation of Gynecology and Obstetrics (FIGO) staging revised in 2008 divided Stage IIIC into Stage IIIC1 and Stage IIIC2 by the presence of para-aortic lymph node metastasis, which is based on the evidence that prognosis is worse with involvement of the para-aortic nodes than that of the pelvic nodes. The risk factors for metastasis of para-aortic lymph nodes are reported to be poor grade, invasion of >1/2 of the myometrium, cervical invasion, lymph-vascular space involvement, and pelvic lymph node metastasis.^{27,28}

The National Comprehensive Cancer Network (NCCN) guideline defines para-aortic lymph node dissection as utility for staging of selected high-risk patients such as deeply invasive lesion, high-grade histology of serous or clear cell carcinoma, or carcinosarcoma. The Society for Medical Oncology²⁹ also recommends pelvic lymphadenectomy and para-aortic lymphadenectomy in intermediate–high-risk endometrial cancer. The National Cancer Institute recommends pelvic lymph node sampling in low-risk patients,

and pelvic and para-aortic lymph node sampling in intermediate- or high-risk patients.

No randomized study on therapeutic significance and prognostic factor of para-aortic lymphadenectomy is seen so far; however, some studies reported the therapeutic effect of para-aortic lymphadenectomy in selected high-risk endometrial cancer patients.^{30,31} Furthermore, the Survival Effect of Para-aortic Lymphadenectomy in Endometrial Cancer study is a retrospective study that was divided into two groups, one was systematic pelvic lymphadenectomy (PLX, 325 cases), and the other was combined pelvic and para-aortic lymphadenectomy (PLX/PALX, 346 cases) for patients with endometrial cancer.³² PLX and PLX/PALX of 5-year overall survival were, respectively, 94.2% and 96.2% in the low-risk group and those of 5-year overall survival were, respectively, 72.6% and 83.2% in each of the intermediate/high-risk groups. This study showed that para-aortic lymph node dissection was a prognostic factor with therapeutic effect for patients at intermediate or high risk of recurrence.

Based on the above, systematic para-aortic lymphadenectomy is necessary in a case that preoperative diagnosis as intermediate or high risk case by histopathology or imaging methods is made. Accumulation of findings from retrospective or randomized controlled studies is essential for the investment of therapeutic effect of para-aortic lymphadenectomy.

Development of minimal invasive surgery

Minimal invasive surgeries have spread to the field of gynecologic oncology, and the number of gynecologic oncologists who use laparoscopic surgery to treat gynecologic cancer is increasing. As the instruments and surgical techniques of surgeons improved, surgeries with a smaller incision have emerged. These novel approaches include single-port surgery and robotic surgery.

Single-port surgery

Laparoscopic para-aortic lymphadenectomy usually used five or six incisions, but the laparoscopic extraperitoneal staging procedure using single-port laparoscopic surgery requires only two incisions. This procedure has cosmetic advantage and reduction in postoperative pain, and is developed on the concept of less incision and less pain.^{33,34}

Escobar et al³⁵ reported para-aortic staging surgery using the single-port laparoscopic approach for early-stage gynecologic cancers transperitoneally for the first time in 2010. They introduced the procedures performed through a single 2–3 cm umbilical incision using a single-port device, a deflecting-tip laparoscope, and multifunctional instrumentation. The median pelvic and para-aortic node counts were 14 (range, 7–19) and 6 (range, 2–14), respectively, and in two of 21 cases conversion to a conventional multiport laparoscopy was carried out.

Since Escobar et al introduced transperitoneal para-aortic lymphadenectomy, most surgeons reported the efficacy and feasibility of the extraperitoneal approach. The procedure of single-port extraperitoneal lymphadenectomy starts with the standard transumbilical diagnostic laparoscopy with a single port inserted via a 2–3 cm incision to assess the peritoneal cavity and obtain a peritoneal fluid sample. Gouy et al³⁶ performed extraperitoneal lymphadenectomy with an incision at a point situated one-third of the way along the line from the anterior superior iliac spine toward the umbilicus. Lambaudie et al³⁷ and Hurdy et al³⁸ introduced the incision at the patient's left side between the iliac crest and the last ribs.

Gouy et al³⁹ reported the use of the extraperitoneal approach in 14 cases of locally advanced cervical cancer. The median number of lymph nodes removed was 14 (range, 2–23) and there was no

conversion to conventional laparoscopy. Many authors reported the feasibility of para-aortic lymphadenectomy via the extraperitoneal approach. They also reported that this procedure can be radical, and the median number of lymph nodes removed is similar to that of the conventional multiport laparoscopic para-aortic lymphadenectomy.^{37,39,40} However, the technical constraints required a longer operative time. Moreover, the learning curve to perform all procedures by a single incision may be slower compared with conventional laparoscopy. On the other hand, Hudry et al³⁸ reported that the mean operative time was shorter than that of the conventional multiport laparoscopic lymphadenectomy, and this surgical technique was feasible for surgeons familiar with extraperitoneal laparoscopy.

Robotic surgery

The robotic approach is increasingly being adopted for several gynecologic malignancies. Robotic surgery provides three-dimensional visualization, and tiny wristed instruments allow the surgeon the maximum range of motion and precision. These systems may have technical advantages over traditional laparoscopy; however robotic para-aortic lymphadenectomy to remove the infrarenal aortic nodes up to the renal veins without relocating the robotic column is challenging.

Lambaudie et al⁴¹ examined 53 patients who underwent infrarenal para-aortic lymphadenectomy using different positions of the robot system, depending on the surgical procedure. For elective para-aortic lymphadenectomy, the da Vinci patient unit was docked at the patient's head, and they had a longer operative time and equivalent lymph node yield compared with the conventional transperitoneal laparoscopic approach. The robotic-assisted extraperitoneal approach showed that para-aortic lymphadenectomy up to the left renal vein was feasible; however, instruments collided frequently, with subsequent risk of great vessel injury. They recommended that extraperitoneal dissection should be performed by experienced laparoscopists. When both pelvic and para-aortic lymphadenectomy are performed by using only one position, they had fewer lymph nodes due to a limited exposure of surgical field. They concluded that positioning of the da Vinci surgical system and port placements should be decided according to the surgical approach. Magrina et al⁴² reported the feasibility of robotic transperitoneal infrarenal aortic lymphadenectomy in 33 patients of gynecologic malignancies with the robotic column at the patient's head and the trocars in the lower pelvis. Zanagnolo et al⁴³ inherited Magrina et al's technique and also reported that robotic infrarenal aortic lymphadenectomy performed with the suprapubic approach is feasible, safe, and oncologically adequate in spite of the need for operative table/robotic column rotation and additional trocar site placement. Thorough para-aortic lymphadenectomy up to the left renal vein can be performed by the rotation of the operative table/robotic column. By contrast, Vizza et al⁴⁴ reported a surgical technique for robotic aortic lymphadenectomy without rotation of the robotic column. They placed the trocars supraumbilically, used a 30° endoscope camera, and changed the camera's position during left-sided para-aortic lymphadenectomy to get a wide field of dissection. An advantage of robotic para-aortic lymphadenectomy is that it has a shorter learning curve suited for surgeons who have very little or no previous laparoscopic experience.⁴³ Disadvantages include a longer operating time and higher cost. Rotation of the robotic column is also time consuming and needs help from the anesthesiologists and operating room nurses.

The procedures of pelvic surgeries and para-aortic lymphadenectomy concomitantly require extensive exploration with adequate movement of camera and robotic arms. The best trocar locations for the removal of pelvic and para-aortic lymph nodes thoroughly are under investigation. Nevertheless, we should seek

to obtain a safer and more reliable method for exposure and removal of lymph nodes, especially the infrarenal para-aortic lymph nodes.

Conclusion

Minimal invasive surgery has been shown to be as safe and feasible as traditional open surgery in women with gynecologic cancers. Furthermore, laparoscopic staging surgery plays a more important role in the treatment and should be the gold standard treatment. The development of the technology and instruments leads us to single-port and robotic surgeries. Single-port surgery is a scarless procedure, and offers decreased postoperative pain and quick recovery. The advantages of robotic surgery are that the surgeon performs the entire surgery with less fatigue and overcomes the limitation of procedures. These novel techniques appear reasonable for both patients and surgeons.

Although diagnostic lymphadenectomy is well established for gynecologic malignant patients, it is controversial to perform lymphadenectomy for all patients. We should decide the surgical treatment for individual patients depending on the risk factors for endometrial cancer. As for ovarian cancer, surgical staging surgery implies not only confirmation of extent to which cancer has spread, but also therapeutic benefit. Lymphadenectomy for cervical cancer also has the meaning as treatment and the decision of radiation field. An adequate technique of lymphadenectomy is essential for staging surgery.

Laparoscopic para-aortic lymphadenectomy is a procedure with technical difficulties. Well-trained surgeons can overcome technical problems and remove more lymph nodes with fewer complications. The familiar surgical anatomy also helps surgeons to reduce blood loss and complications. Transperitoneal lymphadenectomy is more common due to a familiar surgical field with great working space; however, extraperitoneal lymphadenectomy has less adhesion rate and better surgical field to remove lymph nodes. Once knowledge and anatomy of the extraperitoneal approach are acquired, the transperitoneal approach might be a superior procedure for better surgical outcome.

It is significant to gain experience and acquire laparoscopic skill regardless of the type of surgeries and approaches.

Acknowledgments

We thank the Asia-Pacific Association for Gynecologic Endoscopy and Minimally Invasive Therapy for providing International Fellowship Endoscopy Training Program at Chang Gung Memorial Hospital to Dr. Kusunoki.

References

- Dargent D. A new future for Schauta's operation through presurgical retroperitoneal pelvic dissection. *Eur J Gynaecol Oncol.* 1987;8:292–296.
- Querleu D, Leblanc E, Castelain B. Laparoscopic pelvic lymphadenectomy in the staging of early carcinoma of the cervix. *Am J Obstet Gynecol.* 1991;164:579–581.
- Childers JM, Hatch K, Surwit EA. The role of laparoscopic lymphadenectomy in the management of cervical carcinoma. *Gynecol Oncol.* 1992;47:38–43.
- Childers JM, Hatch KD, Tran AN, Surwit EA. Laparoscopic para-aortic lymphadenectomy in gynecologic malignancies. *Obstet Gynecol.* 1993;82:741–747.
- Nezhat CR, Nezhat FR, Burrell MO, et al. Laparoscopic radical hysterectomy and laparoscopically assisted vaginal radical hysterectomy with pelvic and para-aortic node dissection. *J Gynecol Surg.* 1993;9:105–120.
- Vasilev SA, McGonigle KF. Extraperitoneal laparoscopic para-aortic lymph node dissection. *Gynecol Oncol.* 1996;61:315–320.
- Dargent D, Ansquer Y, Mathevet P. Technical development and results of left extraperitoneal laparoscopic paraaortic lymphadenectomy for cervical cancer. *Gynecol Oncol.* 2000;77:87–92.
- Pomel C, Atallah D, Le Bouedec G, et al. Laparoscopic radical hysterectomy for invasive cervical cancer: 8-year experience of a pilot study. *Gynecol Oncol.* 2003;91:534–539.
- Chi DS, Abu-Rustum NR, Sonoda Y, et al. The safety and efficacy of laparoscopic surgical staging of apparent stage I ovarian and fallopian tube cancers. *Am J Obstet Gynecol.* 2005;192:1614–1619.
- Kohler C, Tozzi R, Klemm P, Schneider A. Laparoscopic paraaortic left-sided transperitoneal infrarenal lymphadenectomy in patients with gynecologic malignancies: technique and results. *Gynecol Oncol.* 2003;91:139–148.
- Recio FO, Piver MS, Hempling RE. Pretreatment transperitoneal laparoscopic staging pelvic and paraaortic lymphadenectomy in large (> or = 5 cm) stage IB2 cervical carcinoma: report of a pilot study. *Gynecol Oncol.* 1996;63:333–336.
- Lee C-L, Huang K-G, Wu P-J, Lee P-S, Yen C-F. Long-term survival outcome of laparoscopic staging surgery for endometrial cancer in Taiwanese experience. *Taiwan J Obstet Gynecol.* 2014;53:57–61.
- Lee C-L, Wu K-Y, Huang K-G, Lee P-S, Yen C-F. Long-term survival outcomes of laparoscopically assisted radical hysterectomy in treating early-stage cervical cancer. *Am J Obstet Gynecol.* 2010;203:165.e161–e167.
- Su H, Huang K-G, Yen C-F, Ota T, Lee C-L. Laparoscopic radical trachelectomy: the choice for conservative surgery in early cervical cancer. *Gynecol Minim Invasive Ther.* 2013;2:39–41.
- Querleu D, Dargent D, Ansquer Y, Leblanc E, Narducci F. Extraperitoneal endoscopic aortic and common iliac dissection in the staging of bulky or advanced cervical carcinomas. *Cancer.* 2000;88:1883–1891.
- Nagao S, Fujiwara K, Kagawa R, et al. Feasibility of extraperitoneal laparoscopic para-aortic and common iliac lymphadenectomy. *Gynecol Oncol.* 2006;103:732–735.
- Ramirez PT, Milam MR. Laparoscopic extraperitoneal paraaortic lymphadenectomy in patients with locally advanced cervical cancer. *Gynecol Oncol.* 2007;104:9–12.
- Weiser EB, Bundy BN, Hoskins WJ, et al. Extraperitoneal versus transperitoneal selective paraaortic lymphadenectomy in the pretreatment surgical staging of advanced cervical carcinoma (a Gynecologic Oncology Group study). *Gynecol Oncol.* 1989;33:283–289.
- Morales S, Zapardiel I, Grabowski JP, et al. Surgical outcome of extraperitoneal paraaortic lymph node dissections compared with transperitoneal approach in gynecologic cancer patients. *J Minim Invasive Gynecol.* 2013;20:611–615.
- Ramirez PT, Jhingran A, Macapinlac HA, et al. Laparoscopic extraperitoneal para-aortic lymphadenectomy in locally advanced cervical cancer: a prospective correlation of surgical findings with positron emission tomography/computed tomography findings. *Cancer.* 2011;117:1928–1934.
- Occelli B, Narducci F, Lanvin D, et al. De novo adhesions with extraperitoneal endoscopic para-aortic lymphadenectomy versus transperitoneal laparoscopic para-aortic lymphadenectomy: a randomized experimental study. *Am J Obstet Gynecol.* 2000;183:529–533.
- Occelli B, Narducci F, Lanvin D, LeBlanc E, Querleu D. Learning curves for transperitoneal laparoscopic and extraperitoneal endoscopic paraaortic lymphadenectomy. *J Am Assoc Gynecol Laparosc.* 2000;7:51–53.
- Fowler JM, Hartenbach EM, Reynolds HT, et al. Pelvic adhesion formation after pelvic lymphadenectomy: comparison between transperitoneal laparoscopy and extraperitoneal laparotomy in a porcine model. *Gynecol Oncol.* 1994;55:25–28.
- Pakish J, Soliman PT, Frumovitz M, et al. A comparison of extraperitoneal versus transperitoneal laparoscopic or robotic para-aortic lymphadenectomy for staging of endometrial carcinoma. *Gynecol Oncol.* 2014;132:366–371.
- Raikos A, Paraskevas GK, Natsis K, Tzikas A, Njau SN. Multiple variations in the branching pattern of the abdominal aorta. *Rom J Morphol Embryol.* 2010;51:585–587.
- Possover M, Plaul K, Krause N, Schneider A. Left-sided laparoscopic para-aortic lymphadenectomy: anatomy of the ventral tributaries of the infrarenal vena cava. *Am J Obstet Gynecol.* 1998;179:1295–1297.
- Yokoyama Y, Maruyama H, Sato S, Saito Y. Indispensability of pelvic and para-aortic lymphadenectomy in endometrial cancers. *Gynecol Oncol.* 1997;64:411–417.
- Hirahatake K, Hareyama H, Sakuragi N, Nishiya M, Makinoda S, Fujimoto S. A clinical and pathologic study on para-aortic lymph node metastasis in endometrial carcinoma. *J Surg Oncol.* 1997;65:82–87.
- Barton DPJ, Davies DC, Mahadevan V, et al. Dissection of soft-preserved cadavers in the training of gynaecological oncologists: report of the first UK workshop. *Gynecol Oncol.* 2009;113:352–356.
- Chan JK, Kapp DS. Role of complete lymphadenectomy in endometrioid uterine cancer. *Lancet Oncol.* 2007;8:831–841.
- Mariani A, Webb MJ, Galli L, Podratz KC. Potential therapeutic role of para-aortic lymphadenectomy in node-positive endometrial cancer. *Gynecol Oncol.* 2000;76:348–356.
- Todo Y, Kato H, Kaneuchi M, Watari H, Takeda M, Sakuragi N. Survival effect of para-aortic lymphadenectomy in endometrial cancer (SEPAL study): a retrospective cohort analysis. *Lancet.* 2010;375:1165–1172.
- Fagotti A, Boruta 2nd DM, Scambia G, Fanfani F, Paglia A, Escobar PF. First 100 early endometrial cancer cases treated with laparoendoscopic single-site surgery: a multicentric retrospective study. *Am J Obstet Gynecol.* 2012;206:353.e351–e356.

34. Chern BSM, Lakhota S, Khoo CK, Siow AYM. Single incision laparoscopic surgery in gynecology: evolution, current trends, and future perspectives. *Gynecol Minim Invasive Ther*. 2012;1:9–18.
35. Escobar PF, Fader AN, Rasool N, Espalliat LR. Single-port laparoscopic pelvic and para-aortic lymph node sampling or lymphadenectomy: development of a technique and instrumentation. *Int J Gynecol Cancer*. 2010;20:1268–1273.
36. Gouy S, Uzan C, Kane A, et al. A new single-port approach to perform a transperitoneal step and an extraperitoneal para-aortic lymphadenectomy with a single incision. *J Am Coll Surg*. 2012;214:e25–e30.
37. Lambaudie E, Cannone F, Bannier M, Buttarelli M, Houvenaeghel G. Laparoscopic extraperitoneal aortic dissection: does single-port surgery offer the same possibilities as conventional laparoscopy? *Surg Endosc*. 2012;26:1920–1923.
38. Hudry D, Cannone F, Houvenaeghel G, et al. Comparison of single-port laparoscopy and conventional laparoscopy for extraperitoneal para-aortic lymphadenectomy. *Surg Endosc*. 2013;27:4319–4324.
39. Gouy S, Kane A, Uzan C, Gauthier T, Gilmore J, Morice P. Single-port laparoscopy and extraperitoneal para-aortic lymphadenectomy: about fourteen consecutive cases. *Gynecol Oncol*. 2011;123:329–332.
40. Uzan C, Souadka A, Gouy S, et al. Analysis of morbidity and clinical implications of laparoscopic para-aortic lymphadenectomy in a continuous series of 98 patients with advanced-stage cervical cancer and negative PET-CT imaging in the para-aortic area. *Oncologist*. 2011;16:1021–1027.
41. Lambaudie E, Narducci F, Leblanc E, et al. Robotically assisted laparoscopy for paraaortic lymphadenectomy: technical description and results of an initial experience. *Surg Endosc*. 2012;26:2430–2435.
42. Magrina JF, Long JB, Kho RM, Giles DL, Montero RP, Magtibay PM. Robotic transperitoneal infrarenal aortic lymphadenectomy: technique and results. *Int J Gynecol Cancer*. 2010;20:184–187.
43. Zanagnolo V, Rollo D, Tomaselli T, et al. Robotic-assisted transperitoneal aortic lymphadenectomy as part of staging procedure for gynaecological malignancies: single institution experience. *Obstet Gynecol Int*. 2013;2013:931318.
44. Vizza E, Mancini E, Baiocco E, et al. Robotic transperitoneal aortic lymphadenectomy in gynecologic cancer: a new robotic surgical technique and review of the literature. *Ann Surg Oncol*. 2012;19:3832–3838.