

# An inflammatory myofibroblastic tumor in the transplanted liver displaying quick wash-in and wash-out on contrast-enhanced ultrasound

## A case report

Jing Shang, MD<sup>a</sup>, Yun-yue Wang, BA<sup>a</sup>, Ying Dang, MD<sup>a</sup>, Xin-juan Zhang, MD<sup>b</sup>, Yan Song, MD<sup>a</sup>, Li-tao Ruan, PhD<sup>a,\*</sup>

### Abstract

**Rationale:** Inflammatory myofibroblastic tumor (IMT) is an uncommon mesenchymal neoplasm, and its presence in a grafted liver is exceedingly rare.

**Patient concerns:** A 54-year-old woman was admitted to our hospital with a half-month history of intermittent melena. She had undergone deceased-donor liver transplantation (LT) for hepatitis B virus related liver cirrhosis without hepatocellular carcinoma 5 months previously.

**Diagnosis:** Laboratory examination showed impaired liver and renal functions and Epstein–Barr virus (EBV) infection, but tumor markers within normal ranges. Gastroscopy showed esophageal varices. Ultrasound and computed tomography angiography revealed an ill-defined and irregular solitary lesion in the porta hepatis, encasing both the portal vein and the hepatic artery. The lesion was characterized by arterial hyper-enhancement and hypo-enhancement in the remaining phases with contrast-enhanced ultrasound (CEUS). The lesion was finally confirmed as an IMT by ultrasound-guided biopsy.

**Intervention:** The patient received conservative treatment, including immunosuppression, endoscopic variceal ligation, antibiotics, steroids, and antiviral agents.

**Outcome:** The patient's gastrointestinal bleeding was controlled, but the symptoms associated with portal hypertension worsened. Attempts to perform a transjugular intrahepatic portosystemic shunt were unsuccessful, and she unfortunately died soon after.

**Lessons:** A differential diagnosis of IMT should be considered in LT recipients presenting with EBV infection, normal tumor markers, and a de novo hepatic lesion with quick wash-in and wash-out on CEUS. Ultrasound is associated with the advantages of convenience and nonionizing radiation, and should thus be the priority approach for monitoring transplanted liver.

**Abbreviations:** CEUS = contrast-enhanced ultrasound, CT = computed tomography, EBV = Epstein–Barr virus, HCC = hepatocellular carcinoma, IMT = inflammatory myofibroblastic tumor, LT = liver transplantation.

**Keywords:** contrast-enhanced ultrasound, diagnosis, hepatocellular carcinoma, inflammatory myofibroblastic tumor, liver transplantation

Editor: N/A.

The Ethics Committee of the First Affiliated Hospital of Xi'an Jiaotong University College of Medicine gave approval for this case report. The patient in this case has provided written informed consent.

The authors report no conflicts of interest.

<sup>a</sup> Department of Ultrasound Medicine, <sup>b</sup> Department of Pathological Diagnosis, the First Affiliated Hospital of Xi'an Jiaotong University, Xi'an, China.

\* Correspondence: Li-tao Ruan, Department of Ultrasound Medicine, The First Affiliated Hospital of Xi'an Jiaotong University, No. 277, Yanta West Road, Xi'an 710061, Shaanxi Province, China (e-mail: rlt555@mail.xjtu.edu.cn).

Copyright © 2017 the Author(s). Published by Wolters Kluwer Health, Inc. This is an open access article distributed under the terms of the Creative Commons Attribution-Non Commercial-No Derivatives License 4.0 (CCBY-NC-ND), where it is permissible to download and share the work provided it is properly cited. The work cannot be changed in any way or used commercially without permission from the journal.

Medicine (2017) 96:49(e9024)

Received: 27 October 2017 / Received in final form: 9 November 2017 /

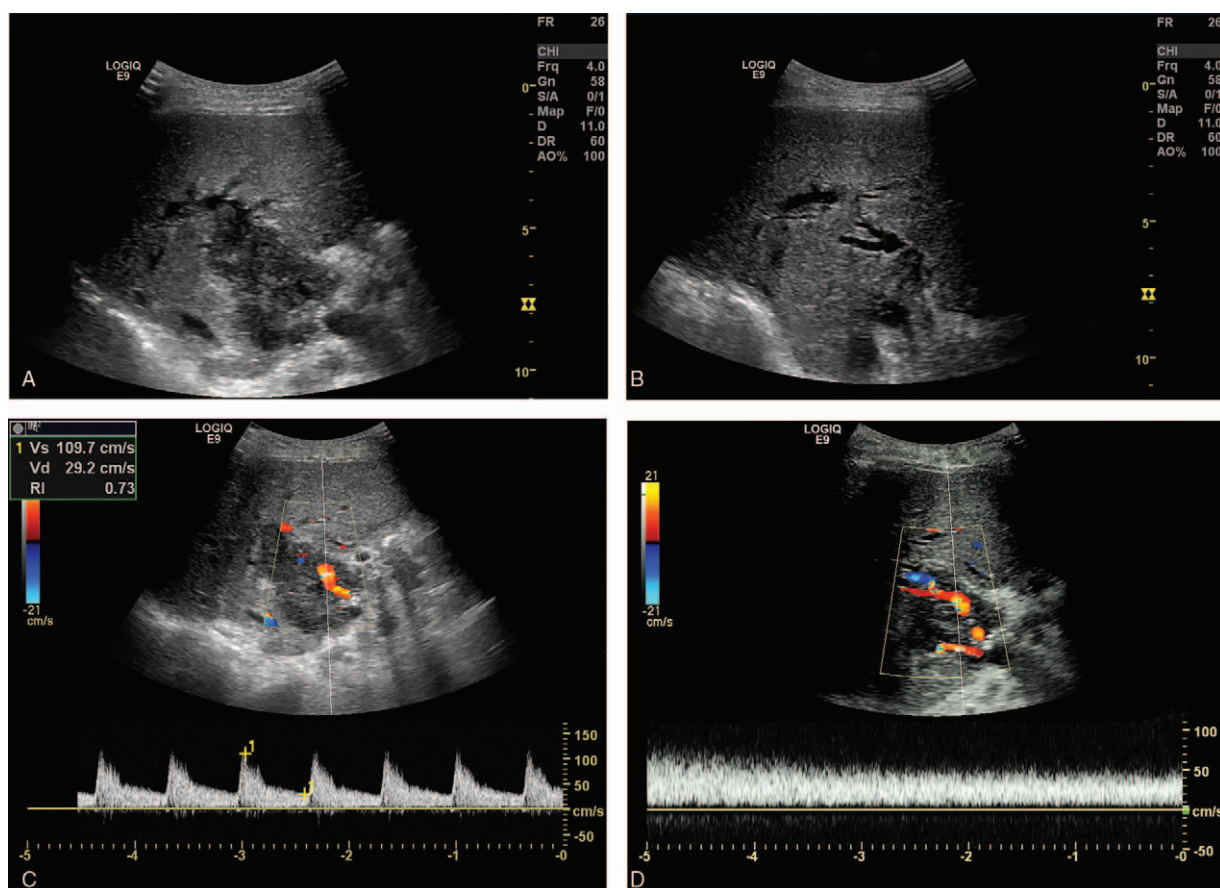
Accepted: 10 November 2017

<http://dx.doi.org/10.1097/MD.0000000000009024>

## 1. Introduction

Inflammatory myofibroblastic tumor (IMT) is an uncommon myofibroblastic neoplasm, variably characterized histologically by cellular spindle cell proliferation in a myxoid-to-collagenous stroma, with a prominent inflammatory infiltrate composed primarily of plasma cells and lymphocytes.<sup>[1]</sup> It is usually located in the lung, but can also occur in extrapulmonary tissues; however, grafted-liver involvement has been extremely rare, with only 2 cases reported to date.<sup>[2,3]</sup> A lack of typical clinical, laboratory, and radiological characteristics means that a definite diagnosis of IMT usually relies on pathological findings.<sup>[4]</sup> Hence, IMT is frequently misdiagnosed as malignancy,<sup>[2,3,5]</sup> resulting in unnecessary surgery. It is therefore necessary to develop better methods of diagnosing IMT before biopsy or surgery.

To the best of our knowledge, the current case represents the first report of a hepatic IMT, evaluated by contrast-enhanced ultrasound (CEUS), in an elderly female liver transplantation (LT) recipient.



**Figure 1.** Ultrasound images of the transplanted liver. (A) Grey-scale ultrasound showed an ill-defined, irregular, hypoechoic lesion (76 mm × 39 mm) located in the hilum, encasing both the portal vein and hepatic artery. (B) Right hepatic duct dilatation was visualized. (C) Pulsed Doppler showed normal color flow in the hepatic artery. (D) Accelerated flow was detected in the portal vein by pulsed Doppler.

## 2. Case report

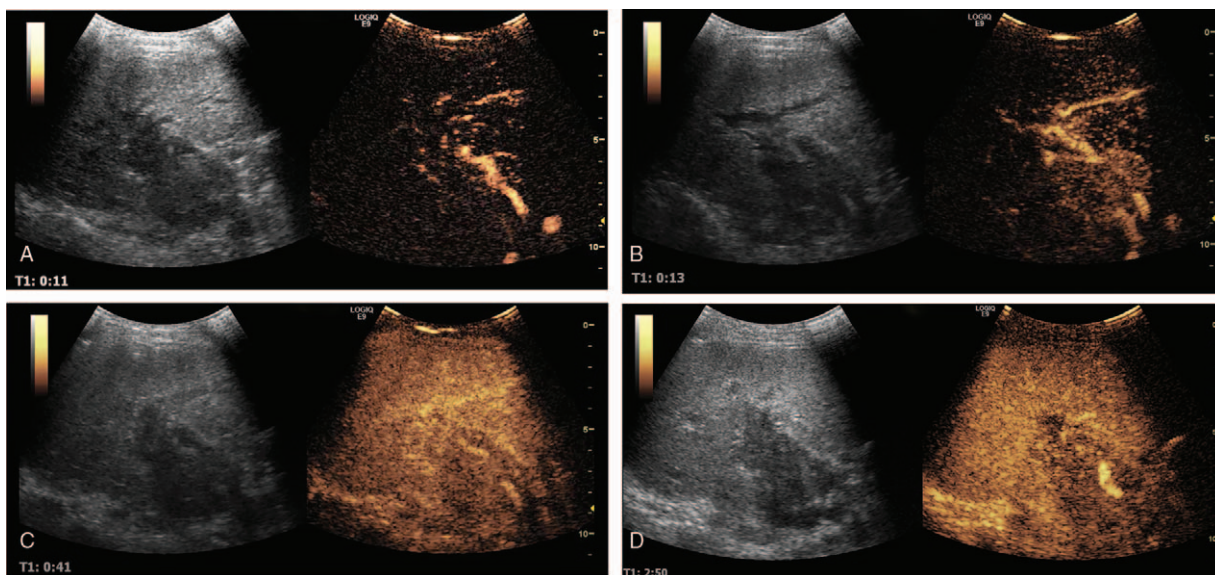
A 54-year-old woman was admitted to our hospital with a half-month history of intermittent tarry stools. She reported no weight loss or any other digestive discomforts. Her medical history included an orthotopic LT 5 months previously for hepatitis B virus related liver cirrhosis accompanied by recurrent upper gastrointestinal hemorrhage. Her postoperative medication consisted of regular cyclosporine, mycophenolate mofetil, and entecavir. Physical examination was unremarkable, except for a right upper quadrant scar.

Routine blood examination showed a decreased red blood cell count of  $2.79 \times 10^{12}/L$  (normal:  $3.8\text{--}5.1 \times 10^{12}$ ), white blood cell count of  $1.94 \times 10^{12}/L$  (normal:  $3.5\text{--}9.5 \times 10^9$ ), platelet count of  $85 \times 10^9/L$  (normal:  $125\text{--}325 \times 10^9$ ), and hemoglobin of 69 g/L (normal: 115–150). Liver function tests were as follows: aspartate aminotransferase 64.00 U/L (normal: 13–35), alanine aminotransferase 54 U/L (normal: 7–40), total protein 15.9 g/L (normal: 65–85), albumin 24.8 g/L (normal: 40–55), and direct bilirubin 43.6  $\mu\text{mol}/L$  (normal: 0–3.4). Clotting study revealed an elevated prothrombin time of 15.9 s (normal: 11–14) and d-dimer of 2.37 mg/L (normal: 1–1.0). Renal function tests showed increased blood urea nitrogen of 18.2 mmol/L (normal: 2.6–7.5) and creatinine of 136  $\mu\text{mol}/L$  (normal: 41–73). Tumor markers including alpha-fetoprotein (3.07 ng/mL, normal: 0–7.02), carcinoembryonic antigen (2.15 ng/mL, normal: 0–3.4), and

carbohydrate antigen 199 (19.44 U/mL, normal: 0–39) were within normal ranges.

The patient developed fever and ongoing melena on the third hospital day. Blood culture was positive for *Staphylococcus epidermidis*, and routine stool examination suggested active gastrointestinal bleeding. Gastroscopy showed esophageal varices. Abdominal ultrasonography showed an ill-defined and irregular solitary lesion arising in the porta hepatis (Fig. 1A), with encasement of the hepatic artery and portal vein. Right intrahepatic duct dilatation (maximum width: 7 mm) was visualized (Fig. 1B). The flow signal in the hepatic artery was normal on pulsed Doppler (Fig. 1C). The portal vein was compressed above the anastomosis (minimum diameter: 3.1 mm), with an accelerated flow velocity of 74 cm/s on pulsed Doppler (Fig. 1D). The right anterior portal vein was filled with loose hypoechoogenicity, and there was no detectable color Doppler signal.

Further CEUS examination was applied to investigate the suspicion of portal vein thrombosis. The hepatic artery and hilar lesion were initially enhanced on CEUS at 11 seconds (Fig. 2A) and 13 seconds (Fig. 2B), respectively. Enhancement of the lesion was obviously stronger than the surrounding parenchyma in the arterial phase. The lesion then quickly faded by 41 seconds (Fig. 2C). The lesion displayed hypo-enhancement (Fig. 2D) in the portal venous and late phases. No perfusion defects were detected in the tortuous hepatic artery or portal vein. This

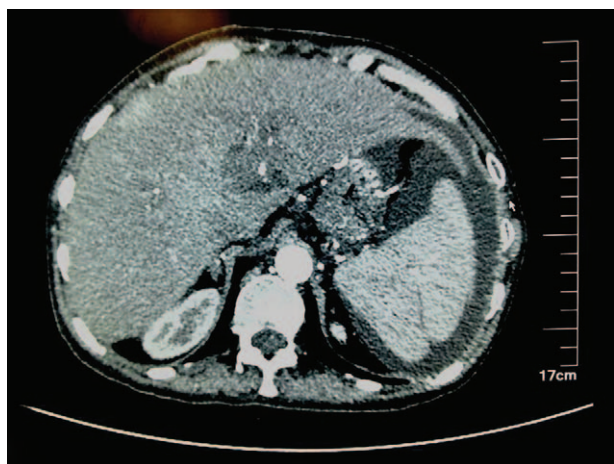


**Figure 2.** Contrast-enhanced ultrasound of the grafted liver. (A) The ultrasound contrast agent entered into the hepatic artery at 11 s. (B) The lesion started to enhance at 13 s and the enhancement signal was higher than the surrounding tissue. (C) The enhancement initially faded at 41 s. (D) The lesion appeared hypo-enhanced in the late phase.

enhancement pattern characterized by “rapid wash-in and wash-out” was a typical feature of malignancy.

Computed tomography (CT) angiography and percutaneous transhepatic cholangiography were also applied to explore the association between the hepatic lesion and adjacent tissue. The former showed a low-density mass in the hepatic hilum, encasing the right anterior hepatic artery (Fig. 3) and compressing the biliary duct, while the latter showed that the common biliary duct was narrowed and shifted by the lesion. A T-tube was therefore placed in situ for biliary drainage.

The patient underwent ultrasound-guided biopsy to confirm the diagnosis (Fig. 4A). Hematoxylin–eosin staining of the greyish-white specimen was characterized by myofibroblastic proliferation with infiltration of numerous plasma cells and lymphocytes (Fig. 4B). The lesion was ultimately confirmed as an



**Figure 3.** Computed tomography angiography of the abdomen showed a low-density mass located in the porta hepatis and encasing the proximal segment of the right hepatic artery.

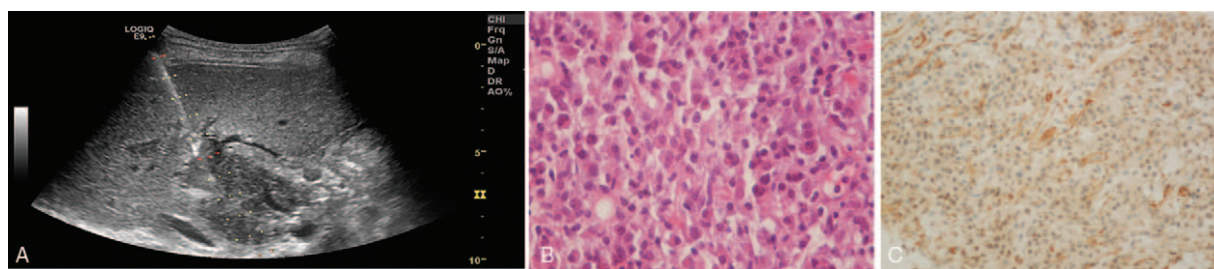
IMT based on immunohistochemical results showing positivity for smooth muscle actin (Fig. 4C), vimentin, actin, CD34, and Ki-67, but no staining for anaplastic lymphoma kinase, desmin, or epithelial membrane antigen. Viral serology for EBV, hepatitis B virus, and cytomegalovirus was only positive for EBV ( $5.52 \times 10^2$  copies/mL).

The patient immediately received conservative therapy, including antibiotics, steroids, antiviral agents, tumor necrosis factor-blocker, biliary drainage, and endoscopic ligation of esophageal varicosity in preference to surgery, in light of her recent LT and recurrent upper gastrointestinal bleeding. She was discharged with no discomfort, but was rehospitalized 1 month later for relapsed gastrointestinal bleeding. A repeated CT revealed no change in lesion size, but increased encasement of the hepatic hilum and emerging portal vein thrombosis compared with the previous CT. A transjugular intrahepatic portosystemic shunt was attempted to relieve the portal hypertension, but the operation failed because the guide wire was unable to pass through the occluded common portal vein. The patient died 1 month later.

### 3. Discussion

IMT has previously been referred to as inflammatory pseudotumor, plasma cell granuloma, xanthomatous pseudotumor, and inflammatory fibrosarcoma.<sup>[6]</sup> The World Health Organization defines it as a distinctive lesion composed of myofibroblastic spindle cells along with chronic infiltration of inflammatory cells.<sup>[7]</sup> Although IMT is usually reported in the lung, extrapulmonary tissues such as the abdomen and pelvis may also be involved.<sup>[1]</sup> However, hepatic IMT is extremely infrequent, and a retrospective study covering a 15-year period identified only 11 (0.15%) cases among 7228 patients with hepatic lesions.<sup>[8]</sup> Hepatic IMT after LT is exceedingly rare, with only a single case report<sup>[2]</sup> and a short letter.<sup>[3]</sup>

Two retrospective studies of hepatic IMT involving 45<sup>[9]</sup> cases and 114<sup>[10]</sup> cases demonstrated that it usually presents with a



**Figure 4.** Hepatic lesion biopsy and histopathology. (A) Ultrasound-guided hepatic lesion biopsy. (B) Hematoxylin–eosin staining of biopsy specimen characterized by myofibroblastic proliferation with infiltration of numerous plasma cells and lymphocytes ( $\times 400$ ). (C) Immunochemical staining was positive for smooth muscle actin ( $\times 200$ ).

solitary lesion in the right lobe on imaging, normal tumor markers, and symptoms of abdominal pain and fever. Its typical sonographic features are hypochoic, solitary, and heterogeneous echo.<sup>[11]</sup> However, these features are insufficient for a diagnosis, which may explain why hepatic IMT is often misdiagnosed<sup>[5]</sup> in the absence of histopathology.

Ultrasound is associated with the advantages of convenience and nonionizing radiation, and is thus the preferred approach for monitoring transplanted livers. In the current case, a hypochoic lesion in the porta hepatis was found in a patient who had undergone LT for liver decompensation. However, it was difficult to make a diagnosis based exclusively on the ultrasound results, and CEUS was carried out as recommended<sup>[12,13]</sup> to investigate the suspected thrombosis in the portal vein, as well as the microvascular characteristics of the lesion. The lesion demonstrated hyperenhancement in arterial phase and hypo-enhancement in the portal venous and late phases, while no perfusion defects were detected in the suspicious portal vein. According to the guidelines for liver CEUS,<sup>[14]</sup> this pattern was typical of a malignant mass but could also be found in other diseases. Given the short time after LT, lack of pre-transplant malignancy, and normal tumor markers, our diagnosis was more inclined to a rare benign, rather than a malignant disease. Although a recent study showed an increase in the incidence of de novo cancers after LT in patients with no evidence of pre-transplant malignancies,<sup>[15]</sup> the risk of a new malignancy within 1 year remains extremely small. This opinion was justified by ultrasound-guided biopsy.

Hepatic lesions in grafted livers usually represent recurrent malignancy,<sup>[16]</sup> metastasis, or focal nodule hyperplasia.<sup>[17]</sup> CEUS can generally be used to differentiate effectively among these.<sup>[14]</sup> Quick wash-in and wash-out on CEUS has been widely accepted as a classic characteristic of hepatocellular carcinoma (HCC).<sup>[14]</sup> However, the chance that CEUS may lead to a false-positive diagnosis of HCC<sup>[5]</sup> has attracted increasing attention.<sup>[18]</sup> One study suggested that both malignant and benign hepatic nodules demonstrated similar enhancement to HCC, and emphasized the importance of the wash-out time for differentiating between these.<sup>[18]</sup> Kong et al<sup>[18]</sup> also showed that some rare benign diseases such as hepatic IMT had faster wash-out times (33 seconds) than HCC (60 seconds), while another study aimed at evaluating IMT by CEUS demonstrated variable enhancement patterns, but a quick duration, with a mean wash-out time of 45 seconds.<sup>[19]</sup> The current case also showed a fast wash-out time. This feature might thus be worth further analysis, given that no diagnostic pattern on CEUS has yet been identified, due to pathological changes during the course of disease progression.

In conclusion, IMT should be considered as a differential diagnosis in LT recipient presenting with a solitary hepatic lesion, normal tumor markers, EB infection, and quick wash-in and wash-out on CEUS. In the absence of radiation injury or liver/kidney function injury, CEUS should be considered as the first-choice imaging technology for patients after major operations such as LT, who are not suitable for multiple CT angiography.

### Acknowledgment

We thank Susan Furness, PhD, from Liwen Bianji, Edanz Group China ([www.liwenbianji.cn/ac](http://www.liwenbianji.cn/ac)), for editing the English text of a draft of this manuscript.

### References

- [1] Gleason BC, Hornick JL. Inflammatory myofibroblastic tumours: where are we now? *J Clin Pathol* 2008;61:428–37.
- [2] Lykavieris P, Fabre M, Waguët J, et al. Inflammatory pseudotumor after liver transplantation. *J Pediatr Gastroenterol Nutr* 2000;31:309–12.
- [3] Yoshiya S, Ikegami T, Yoshizumi T, et al. Fairly rare de novo inflammatory pseudotumor in a graft after living donor liver transplantation. *Liver Transpl* 2014;20:616–8.
- [4] Elpek GÖ. Inflammatory myofibroblastic tumor of the liver: a diagnostic challenge. *J Clin Transl Hepatol* 2014;2:53–7.
- [5] Xian MF, Lan WT, Huang H, et al. Huge hepatic fungal inflammatory pseudotumor misdiagnosed as primary hepatocellular carcinoma. *Ultrasound Q* 2017;33:242–4.
- [6] Fragoso AC, Eloy C, Estevãocosta J, et al. Abdominal inflammatory myofibroblastic tumor a clinicopathologic study with reappraisal of biologic behavior. *J Pediatr Surg* 2011;46:2076–82.
- [7] Coffin CM, Fletcher JA. Inflammatory myofibroblastic tumor. In: Fletcher CDM, Unni KK, Mertens F, editors. *World Health Organization classification of tumours. Pathology and genetics of tumours of soft tissue and bone*. Lyon: IARC Press; 2002;91–3.
- [8] Yang X, Miao R, Yang H, et al. Retrospective and comparative study of inflammatory myofibroblastic tumor of the liver. *J Gastroenterol Hepatol* 2015;30:885–90.
- [9] Park JY, Choi MS, Lim YS, et al. Clinical features, image findings, and prognosis of inflammatory pseudotumor of the liver: a multicenter experience of 45 cases. *Gut Liver* 2014;8:58–63.
- [10] Yang X, Zhu J, Biskup E, et al. Inflammatory pseudotumors of the liver: experience of 114 cases. *Tumour Biol* 2015;36:5143–8.
- [11] Motojuku M, Oida Y, Morikawa G, et al. Inflammatory pseudotumor of the liver: case report and review of literature. *Tokai J Exp Clin Med* 2008;33:70–4.
- [12] Ren J, Wu T, Zheng BW, et al. Application of contrast-enhanced ultrasound after liver transplantation: current status and perspectives. *World J Gastroenterol* 2016;22:1607–16.
- [13] Teegen EM, Denecke T, Eisele R, et al. Clinical application of modern ultrasound techniques after liver transplantation. *Acta Radiol* 2016;57:1161–70.
- [14] Claudon M, Dietrich CF, Choi BI, et al. Guidelines and good clinical practice recommendations for contrast enhanced ultrasound (CEUS) in the liver: update 2012. *Ultraschall Med* 2013;34:11–29.

- [15] Yu S, Gao F, Yu J, et al. De novo cancers following liver transplantation: a single center experience in China. *PLoS One* 2014;9:e85651.
- [16] Welker MW, Bechstein WO, Zeuzem S, et al. Recurrent hepatocellular carcinoma after liver transplantation: an emerging clinical challenge. *Transplant Int* 2013;26:109–18.
- [17] Ra SH, Kaplan JB, Lassman CR. Focal nodular hyperplasia after orthotopic liver transplantation. *Liver Transpl* 2010;16:98–103.
- [18] Kong WT, Wang WP, Huang BJ, et al. Value of wash-in and wash-out time in the diagnosis between hepatocellular carcinoma and other hepatic nodules with similar vascular pattern on contrast-enhanced ultrasound. *J Gastroenterol Hepatol* 2014;29:576–80.
- [19] Kong WT, Wang WP, Cai H, et al. The analysis of enhancement pattern of hepatic inflammatory pseudotumor on contrast-enhanced ultrasound. *Abdom Imaging* 2014;39:168–74.