

Safety and Efficacy of Laparoscopic Oophorectomy for Ovarian Dermoid Cyst Associated With Autoimmune Hemolytic Anemia

Masafumi Nii, Eiji Kondo, Shintaro Maki, Michiko Kubo, Kenta Yoshida, Lingyun Zhang, Yoshiyuki Kobayashi, Tsutomu Tabata, Tomoaki Ikeda

Department of Obstetrics and Gynecology, Mie University School of Medicine, Tsu, Mie, Japan

Abstract

Ovarian dermoid cysts (ODCs) are the most common benign tumors in young women, but autoimmune hemolytic anemia (AIHA) induced by ODC is rare. We report the first case of ODC-associated AIHA with improvement after laparoscopic oophorectomy. An 18-year-old nulliparous woman was diagnosed with a left ODC that was 7 cm in diameter. Preoperative blood tests showed macrocytic anemia, reticulocytosis, high serum lactate dehydrogenase activity, hyperbilirubinemia, and low haptoglobin. Direct and indirect Coombs tests were positive. We diagnosed AIHA. Prednisolone therapy did not result in improvement, so it seemed that AIHA was being induced by the ODC. After laparoscopic oophorectomy, the patient's condition improved without blood transfusion. Resection of ODC should be performed first for ODC-associated AIHA; laparoscopic surgery may be superior to laparotomy from the standpoint of hemorrhage given the underlying anemia.

Keywords: Autoimmune hemolytic anemia, laparoscopic oophorectomy, ovarian dermoid cyst

INTRODUCTION

Dermoid cyst is the most common type of benign ovarian tumor in young women, but it is quite rare for ovarian dermoid cysts (ODCs) to induce autoimmune hemolytic anemia (AIHA). In AIHA, antibodies against red blood cells (RBCs) shorten their lifespan through hemolysis mediated by antigen-antibody interactions. Causes of AIHA are varied and complex. Causes of secondary AIHA include underlying diseases such as collagen diseases, rheumatic diseases, lymphocytosis, neoplasms, infection, and ovarian tumors such as ODC and ovarian adenocarcinoma.^[1] We have identified only 24 cases of AIHA induced by ovarian ODC, including the present case, since it was first described by West-Watson and Young in 1938.^[2] Over the last two decades, there have been no reports of ODC-associated AIHA. Mechanisms by which ODC induces the production of RBC autoantibodies are unknown, but corticosteroids and splenectomy are ineffective. Tumor resection is the most effective treatment.^[3] In addition, blood transfusion should be avoided because of the risk of incompatibility.^[4] Laparoscopic surgery is superior to laparotomy from the standpoint of hemorrhage.^[5] We report the first case of ODC-associated

AIHA that resolved with laparoscopic oophorectomy and no blood transfusion.

CASE REPORT

An 18-year-old nulliparous woman was diagnosed with a left abdominopelvic mass based on an ultrasound examination 3 months before hospital admission planned for laparoscopic oophorectomy. Her past medical history and family history were unremarkable. There was no recent exposure to medications.

Her tumor marker levels were carcinoembryonic antigen, 0.7 ng/mL; CA19-9, 37.5 U/mL; and CA125, 17.3 U/mL. Abdominal magnetic resonance imaging and computed tomography revealed a cystic ovarian mass (7 cm × 6 cm × 7 cm). The mass was suspected to consist of mostly fat, so it was

Address for correspondence: Dr. Masafumi Nii,
Department of Obstetrics and Gynecology, Mie University School of
Medicine, 2-174 Edobashi, Tsu, Mie, Japan.
E-mail: doaldosleeping@yahoo.co.jp

This is an open access article distributed under the terms of the Creative Commons Attribution-NonCommercial-ShareAlike 3.0 License, which allows others to remix, tweak, and build upon the work non-commercially, as long as the author is credited and the new creations are licensed under the identical terms.

For reprints contact: reprints@medknow.com

How to cite this article: Nii M, Kondo E, Maki S, Kubo M, Yoshida K, Zhang L, *et al.* Safety and efficacy of laparoscopic oophorectomy for ovarian dermoid cyst associated with autoimmune hemolytic anemia. *Gynecol Minim Invasive Ther* 2018;7:27-30.

Access this article online

Quick Response Code:



Website:
www.e-gmit.com

DOI:
10.4103/GMIT.GMIT_9_17

considered to be a benign tumor. There were no other remarkable findings. Thus, we made a diagnosis of left ODC.

Before admission, preoperative tests showed macrocytic anemia, reticulocytosis, low haptoglobin, elevated hepatic enzymes, high serum lactate dehydrogenase (LDH) activity, and hyperbilirubinemia. Her hemoglobin (Hb) level was 7.8 g/dL, reticulocyte count was 13.9%, mean corpuscular volume was 111.2 fL, LDH was 792 IU/L, total bilirubin (T-Bil) was 2.3 mg/dL, and haptoglobin was <7.3 mg/dL. The white blood cell and platelet counts were within normal limits [Figure 1]. She had multiple abnormal antibodies. The direct Coombs test was positive (4+), with activity against IgG but not C3 complement. The indirect Coombs test was positive (1+). The cold hemagglutination test was negative. We made the diagnosis of AIHA. The patient was admitted ahead of schedule.

On admission, she was slightly icteric and pale. Oral prednisolone 50 mg (1 mg/kg) once daily was started at this time. Her condition did not improve after 1 week of prednisolone therapy. At that time, Hb was 6.1 g/dL, reticulocyte count was 20.6%, LDH was 681 IU/L, and T-Bil was 1.7 mg/dL [Figure 1]. Therefore, we inferred that AIHA was induced by the ODC and performed laparoscopic left oophorocystectomy [Figure 2]. Since splenomegaly was not present, we did not perform splenectomy. Operative time was 70 min, and total blood loss was 26 mL. Blood transfusion was not needed. Pathologic evaluation revealed a left mature cystic teratoma with dental, fatty, and dermoid tissue. Immature components were not detected.

After surgery, hemolysis and anemia gradually became less severe. She was discharged on postoperative day 16 with Hb of 9.0 g/dL [Figure 1]. The same quantity of prednisolone (50 mg daily) was continued after surgery. Serial follow-up showed a steady rise in Hb. We were able to reduce the dose of prednisolone from 50 mg to 45 mg a day on postoperative day 14, but the direct and indirect Coombs tests remained positive. During the following weeks, Hb level reached normal values. She remained on prednisolone therapy until both direct and

indirect Coombs test results turned negative. Written informed consent was obtained from the patient for publication of this case report and accompanying images.

DISCUSSION

Since AIHA associated with ODC is a rare disease, few physicians know about this condition. Its pathogenesis is unknown, but tumor resection has been reported to be the most effective therapy for ODC-associated AIHA. However, in most cases of AIHA, patients already have anemia before surgery. Thus, laparoscopic surgery is more suitable for this disease than laparotomy from the standpoint of blood loss.

AIHA can be idiopathic or secondary. Possible causes include various complicated factors. However, ODC-associated AIHA is not common. Possible mechanisms underlying ODC-associated AIHA include (1) a substance produced by the ovarian tumor that alters the surface of RBCs, rendering them antigenic to the host, (2) a component of the ovarian tumor stimulates the production of antibodies that cross-react with host erythrocytes, and (3) the cyst itself produces antibodies against RBCs. However, the real pathophysiology of this disease has not been defined.^[6,7]

Regarding therapy for ODC-associated AIHA, prednisolone and splenectomy are not effective. Resection is the only effective way to treat ODC-associated AIHA.^[3] Approximately 40% of patients with idiopathic AIHA were successfully treated with 4 weeks of steroids. Oral prednisolone 50 mg/day was used in this case; however, since this patient had AIHA secondary to ODC, preoperative and postoperative steroid therapy might not have been needed. To the best of our knowledge, except two patients who died during or after surgery, all reported cases involved anemia that resolved after tumor resection, which is why we performed ODC resection.

All resections to date have involved laparotomy [Table 1]. Ours is the first case of ODC-associated AIHA that involved laparoscopic ODC resection. Laparoscopic surgery is

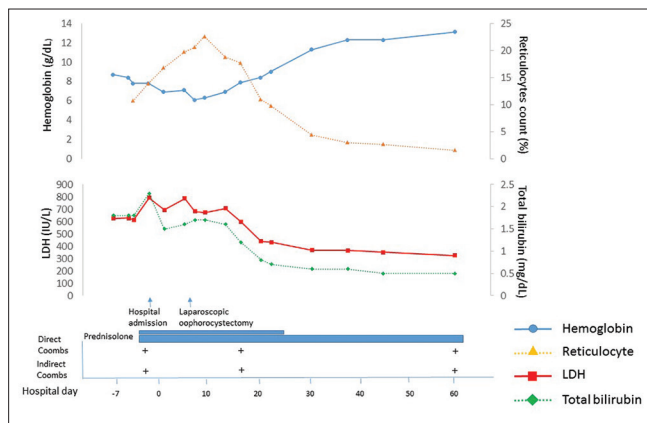


Figure 1: Laboratory findings and clinical course before and after surgery. LDH = lactate dehydrogenase

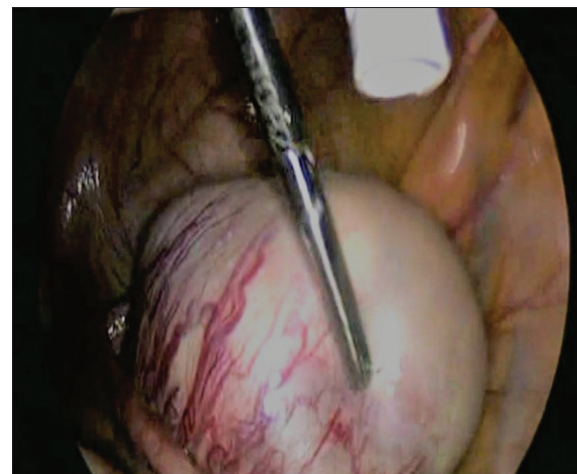

Figure 2: Laparoscopic oophorocystectomy for the ODC. ODC = ovarian dermoid cyst

Table 1: Reported cases of ovarian dermoid cyst associated with autoimmune hemolytic anemia

Author (year)	Age	Hb (g/dL)	Reticulocyte count (%)	Therapy			Type of surgery	Transfusion
				Steroids	Splenectomy	Cystectomy		
West-Watson and Young (1938)	44	3.4	45		—	+	Laparotomy	Yes
Singer and Dameshek (1941)	47	5.1	46		±	+	Laparotomy	
Lindeboom (1950)	40	4.3	16		—			
Allibeone and Collins (1951)	4	7	47			+	Laparotomy	Yes
De Gruchy (1954)	61	5.2	20					
Wuhrmann (1954)	53	6.5	78	—		+	Laparotomy	
Andre,Dreyfus, and Salmon (1955)	54	6.7	58	—		+	Laparotomy	
Prochazka (1956)	40	4.3	74	±	±	+	Laparotomy	
Barry and Crosby (1957)	26	3.6	58			+	Laparotomy	
von Müller and Schubotho (1958)	44	4	50	—	—	+	Laparotomy	
Szirmai (1961)	49			—	—	+	Laparotomy	
Szirmai (1961)	45					+	Laparotomy	
Larrain et al (1963)	30	3.5	74	±		+	Laparotomy	
Mc Andrew (1964)	48	4.2	97	—		+	Laparotomy	Yes
Baker et al (1968)	52	6.8	11	—	+	+	Laparotomy	
De Bruyere et al (1971)	32	3.5	50	—	±	+	Laparotomy	
Bernstein (1974)	35	5.5	6.5			+	Laparotomy	
Bunuel et al (1976)	47	4.8	60	±		+	Laparotomy	
Payne et al (1981)	34	10.3	1.9	±		+	Laparotomy	No
Ikeda et al (1985)	40	4.6	64	±		+	Laparotomy	No
Takechi et al (1988)	35	3.7	23.4	+		+	Laparotomy	No
Suzuki et al (1991)	20	3.8	49.5	—		+	Laparotomy	Yes
Cobo et al (1995)	37	7.3	33	+		+	Laparotomy	No
Present Case (2016)	18	8.7	10.7	+		+	Laparoscopy	No

Hb = hemoglobin, + = effective, ± = partially effective, — = not effective, blank = not mentioned

superior to laparotomy with respect to blood loss, especially for this disease. Patients with AIHA have already anemia at diagnosis and may likely need blood transfusion at the time of diagnosis and again during surgery. In addition, in AIHA, free antibodies in serum and antibodies coating RBC antigens might interfere with blood typing and cross-matching, leading to a high risk of an incompatibility. Patients with AIHA also have abnormal antibodies, so blood transfusion itself may aggravate hemolysis and produce both alloantibodies and autoantibodies.^[8] Thus, if possible, blood transfusion should be avoided, but it was performed in some laparotomy cases [Table 1]. Laparoscopic surgery is especially suitable for this disease because laparoscopic surgery that allows for an expanded visual field helps reduce hemorrhage compared to laparotomy.^[5,9] Even for idiopathic cases, Rosen *et al.* reported that laparoscopic splenectomy resulted in shorter surgery, minimal blood loss, and earlier hospital discharge than laparotomy.^[10] Therefore, we believe that laparoscopic surgery for AIHA has more benefits than laparotomy. However, if massive bleeding encountered during cystectomy, we prepare two plans. First, we prepare some blood plasma expander. Second, we will change unilateral oophorectomy. And then, if those approach do not work well, we do not hesitate to do blood transfusion.

We encountered a rare case of ODC-associated AIHA. After the diagnosis was made, we immediately performed laparoscopic oophorectomy, which lessened hemolysis and anemia without the need for blood transfusion.

Declaration of patient consent

The authors certify that they have obtained all appropriate patient consent forms. In the form the patient(s) has/have

given his/her/their consent for his/her/their images and other clinical information to be reported in the journal. The patients understand that their names and initials will not be published and due efforts will be made to conceal their identity, but anonymity cannot be guaranteed.

Acknowledgment

The authors are grateful to all the doctors and staff of Mie University Hospital for their support, which made this manuscript possible.

Financial support and sponsorship

Nil.

Conflicts of interest

There are no conflicts of interest.

REFERENCES

- Cobo F, Pereira A, Nomdedeu B, Gallart T, Ordi J, Torne A, *et al.* Ovarian dermoid cyst-associated autoimmune hemolytic anemia: A case report with emphasis on pathogenic mechanisms. *Am J Clin Pathol* 1996;105:567-71.
- West-Watson WN, Young CJ. Failed splenectomy in acholuric jaundice. *Br Med J* 1938;1:1305-9.
- Young RH. New and unusual aspects of ovarian germ cell tumors. *Am J Surg Pathol* 1993;17:1210-24.
- Young PP, Uzieblo A, Trulock E, Lublin DM, Goodnough LT. Autoantibody formation after alloimmunization: Are blood transfusions a risk factor for autoimmune hemolytic anemia? *Transfusion* 2004;44:67-72.
- Morgante G, Ditto A, la Marca A, Trotta V, De Leo V. Surgical treatment of ovarian dermoid cysts. *Eur J Obstet Gynecol Reprod Biol* 1998;81:47-50.
- De Bruyere M, Sokal G, Devoitille JM, Fauchet-Dutrieux CH, De Spa V. Autoimmune hemolytic anemia and ovarian tumor. *Br J Haematol* 1971;20:83.
- Payne D, Muss HB, Homesley HD, Jobson VW, Baird FG. Autoimmune

- hemolytic anemia and ovarian dermoid cysts: Case report and review of the literature. *Cancer* 1981;48:721-4.
8. Sokol RJ, Hewitt S, Booker DJ, Morris BM. Patients with red cell autoantibodies: Selection of blood for transfusion. *Clin Lab Haematol* 1988;10:257-64.
 9. Briones-Landa CH, Ayala-Yáñez R, Leroy-López L, Anaya-Coeto H, Santarosa-Pérez MA, Reyes-Muñoz E, *et al.* Comparison of laparoscopic vs. Laparotomy treatment in ovarian teratomas. *Ginecol Obstet Mex* 2010;78:527-32.
 10. Rosen M, Brody F, Walsh RM, Tarnoff M, Malm J, Ponsky J, *et al.* Outcome of laparoscopic splenectomy based on hematologic indication. *Surg Endosc* 2002;16:272-9.