

Possible Biological Heterogeneity of Airway Mucus Plugs in a Patient with Asthma

Hiroki Tashiro, Mizuki Nanri, Yuki Kuwahara, Yuki Kurihara, Shinya Kimura, Koichiro Takahashi 

Division of Hematology, Respiratory Medicine and Oncology, Department of Internal Medicine, Faculty of Medicine, Saga University, Saga, Saga Prefecture, Japan

Correspondence: Hiroki Tashiro, Division of Hematology, Respiratory Medicine and Oncology, Department of Internal Medicine, Faculty of Medicine, Saga University, 5-1-1 Nabeshima, Saga, Saga Prefecture, 849-8501, Japan, Tel +81 952 34 2369, Fax + 81 952 34 2017, Email si3222@cc.saga-u.ac.jp

Background: The presence of mucus plugs in the airway is a severe phenotype in patients with asthma; however, the mechanisms and specific treatments are not fully understood.

Purpose: To clarify the efficacy of biologics and the mechanisms for mucus plug in patients with asthma.

Patients and Methods: A 79-year-old Japanese asthmatic woman with high blood eosinophil and fractional exhaled nitric oxide (FeNO) was pointed massive mucus plugs in airway on chest CT imaging. She was treated with mepolizumab for 3 months; however, those were augmented without improvement of pulmonary function and FeNO. She was switched to dupilumab and, three months later, the mucus plugs were completely disappeared with improvement in pulmonary function, FeNO and asthma-related symptoms. She continues treatment with dupilumab, and her asthma symptoms are stable.

Conclusion: Biologics including mepolizumab and dupilumab have been reported to improve mucus plugs in patients with asthma; however, their efficacy might be different depending on the clinical characteristics of patients. Present data remind us of the possibility that, if FeNO levels remain high after treatment with anti-IL-5 antibody in asthma patients with mucus plugs, switching to other biologics, including anti-IL-4R α antibody, might be considered.

Keywords: asthma, biologics, mucus plugs, mechanisms

Introduction

The presence of mucus plugs in the airway, which are detected as high attenuation structures on computed tomography (CT) on the mediastinal window setting, is a severe phenotype in patients with asthma, whose particular characteristic is eosinophilic airway inflammation called “type 2 inflammation”.¹ Mucus plugs contribute to decreased pulmonary function, and they might be related to mortality in patients with asthma^{2,3}; however, the mechanisms and specific treatments are not fully understood. Currently, several biologics including anti-immunoglobulin E (IgE), anti-interleukin (IL)-5, anti-IL-5 receptor alpha (IL-5R α), anti-IL-4 receptor alpha (IL-4R α), and anti-thymic stromal lymphopoietin (TSLP) antibodies are clinically available for treating patients with severe uncontrolled asthma, and the efficacies are greater for patients with eosinophilic airway inflammation.⁴ Additionally, the treatment efficacy of each biologic allows us to understand the biological phenotypes of patients with severe eosinophilic asthma. In this report, the case of an asthma patient with mucus plugs treated sequentially with anti-IL-5 antibody and anti-IL-4R α antibody, showing different effects for mucus plugs in different anatomical locations, which suggests the biological heterogeneity of airway mucus plugs in patients with asthma, is presented.

Case Presentation

A 79-year-old Japanese woman who had cataract, glaucoma, and allergic rhinitis consulted our hospital for increased cough and sputum. She had been diagnosed as having asthma 2 months earlier and was treated with a medium dose of inhaled corticosteroid (ICS), a long-acting β_2 adrenergic agonist, and a leukotriene receptor antagonist. She had no history of chronic sinusitis, alcohol abuse, smoking and allergic reaction to foods and drugs. On physical examination,

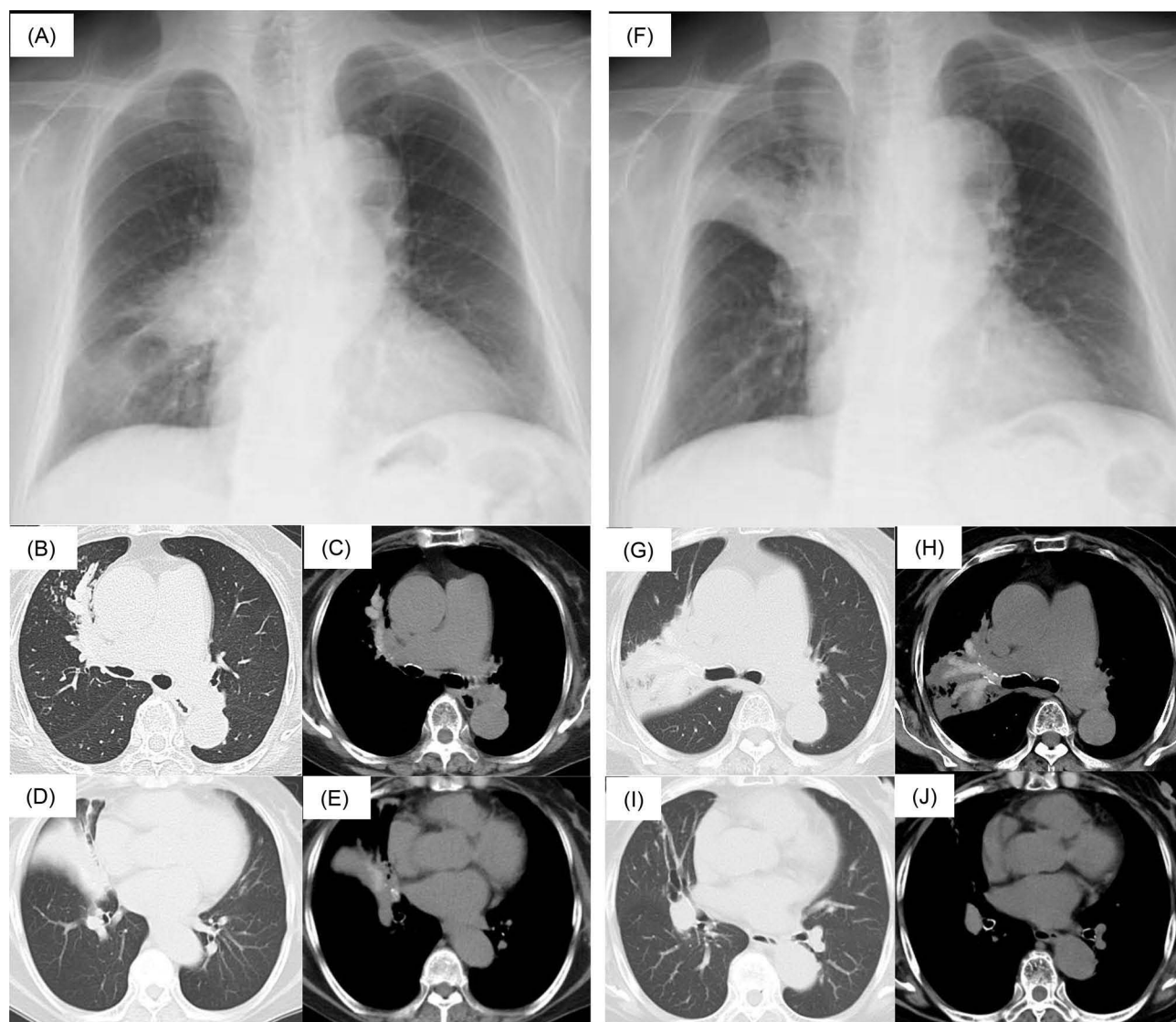


Figure 1 Findings on chest X-ray and computed tomography (CT) before (A–E) and after treatment with mepolizumab (F–J). (A) Before treatment, the chest X-ray shows decreased density in the middle central and lower peripheral fields of the right lung. (B–E) Chest CT shows a funicular shadow in the right upper lobe and consolidation in the right middle lobe on the lung window setting with high attenuation structures on the mediastinal window setting in the B3 and B4 bronchi. (F) After treatment with mepolizumab, the chest X-ray shows decreased density in the upper field with disappearance of the decreased density in the middle central and lower peripheral field of the right lung. (G–J) Chest CT shows consolidation in the right upper lobe on the lung window setting, with high attenuation structures on the mediastinal window setting in the B2 and B3 bronchi, even though those in the B4 bronchus have recovered with resolution of obstructive atelectasis of the right middle lobe.

she had productive cough and wheezes on both sides of the chest without fever, hypoxia, or skin rash. Her chest X-ray showed consolidation in the middle central and lower peripheral fields of the right lung (Figure 1A). Chest CT showed a funicular shadow in the right upper lobe and consolidation in the right middle lobe in the lung window setting, with high attenuation structures in the mediastinal window setting, indicating mucus plugs, in the B3 and B4 bronchi (Figure 1B–E). On laboratory examination, the white blood cell count was 6600/ μ L, with 20% eosinophils (1320/ μ L), total IgE was 232 IU/mL without positive findings for any specific IgE levels including *Aspergillus* and *Alternaria*. The asthma control test (ACT) score was 17 points, and on pulmonary function testing, vital capacity (VC) was 1930 mL, %VC was 78.8%, forced vital capacity was 1800 mL, %FVC was 75.9%, forced expiratory volume in 1 second (FEV1) was 1330 mL, %FEV1 was 73.5% and fractional exhaled nitric oxide (FeNO) was 66 ppb. Considering the adverse effects of systemic corticosteroid treatment and her quite high blood eosinophil counts, she was treated with mepolizumab (100mg every 4 weeks) for 3 months without eventually administration of systemic corticosteroid. Her ACT scores

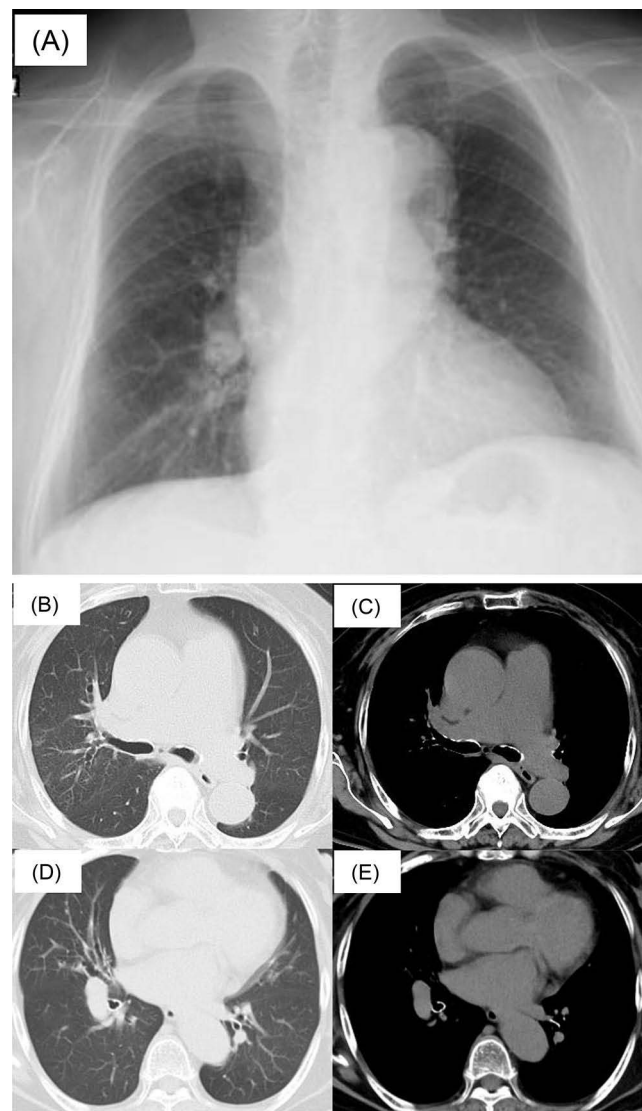


Figure 2 Findings on chest X-ray and CT after treatment with dupilumab. (A) Chest X-ray shows disappearance of the decreased density in the upper lung field. (B–E) Chest CT shows disappearance of consolidation on the lung window setting and high attenuation structures on the mediastinal window setting in the right upper lobe.

improved to 21 points with blood eosinophils of $189/\mu\text{L}$ and total IgE of 264 IU/mL, but mucus plugs in the right upper lobe were increased with expansion to the B2 bronchus even though those in the B4 bronchus recovered with resolution of obstructive atelectasis of the right middle lobe (Figure 1F–J). Her pulmonary function testing showed further worsening of VC (1690 mL), %VC (69.0%), FVC (1640 mL), %FVC (69.2%), FEV1 (1250 mL), %FEV1 (69.1%) and FeNO (57 ppb). Considering that mepolizumab had an insufficient effect on the mucus plugs, she was switched to dupilumab (an initial dose of 600mg followed by 300mg every other week). Three months later, her ACT scores were further increased to 25 points, with blood eosinophils of $329/\mu\text{L}$, and total IgE of 59 IU/mL, and the mucus plugs, including those in the right upper lobe, had completely disappeared (Figure 2A–E). Her pulmonary function testing showed an increased VC of 1890 mL, %VC of 77.1%, FVC of 1790 mL, %FVC of 75.5%, FEV1 of 1280 mL, %FEV1 of 70.7% and decreased FeNO of 15 ppb. She continues treatment with dupilumab, and her asthma symptoms are stable.

Discussion

Biologics have been reported to improve mucus plugs. Tang et al, in a 3-year observational study of severe asthma in the USA, reported that serum and sputum eosinophil peroxidase levels were correlated with the mucus score, and they were significantly attenuated by treatment with mepolizumab.⁵ On the other hand, dupilumab contributes to a greater reduction

in mucus plugging with greater improvement in ventilation quantified using ^{129}Xe magnetic resonance imaging compared with placebo.⁶ In Japan, dupilumab has also been shown to have a beneficial effect on mucus plugs evaluated on CT in patients with asthma.⁷ Interestingly, in the present case, the mucus plug in the B4 bronchus recovered and that in the B3 bronchus increased with anti-IL-5 antibody treatment. Furthermore, the mucus plug in the B3 bronchus recovered with anti-IL-4R α antibody treatment, which supported the possibility of biological heterogeneity of airway mucus plugs in patients with asthma. Increasing dose of ICS might be also considered to avoid the side effects of systemic corticosteroid before administration of biologics according to the guideline.⁸ In the present case, we treated with biologics prior to increasing dose of ICS considering the therapeutic benefit, risk of systemic side effect⁹ and characteristics of participants in Phase 3 studies of the biologics.^{10,11} There has been no direct comparison of efficacy between anti-IL-5 and anti-IL-4R α antibodies for mucus plugs in patients with asthma, to the best of our knowledge, and prediction of the heterogeneity of mucus plugs might be challenging. However, in the present case, the FeNO level was still high after treatment with anti-IL-5 antibody, even though there was partial improvement of the mucus plug in the right middle lobe (Figure 1D, E, I, J). A high FeNO level suggests that an IL-13-driven sub-phenotype in type 2 high asthma is one of the biomarkers for poor responders to anti-IL-5 antibody compared with IL-4R α antibody.¹² In addition, Hayashi et al recently reported that asthma patients with high FeNO levels showed a greater rate of mucus plugging than those with low FeNO levels.¹³ These data remind us of the possibility that, if FeNO levels remain high after treatment with anti-IL-5 antibody in asthma patients with mucus plugs, switching to other biologics, including anti-IL-4R α antibody, might be considered, following the rotation strategy recommended by asthma treatment guidelines. Notably, Nordenmark et al recently reported that, compared with placebo, anti-TSLP antibody decreased mucus plugs for patients with high mucus scores characterized by high blood eosinophil and FeNO levels.¹⁴ The data indicated that anti-TSLP antibody, which blockades the signals of IL-4, IL-5, and IL-13 as a targeting upstream molecule of type 2 cytokines, is another candidate for the treatment of mucus plugs for patients with asthma. The present report has several limitations. First, the patient was not examined bronchodilator reversibility test even though the diagnosis of asthma referring to the Global Initiative for Asthma guideline⁸ was consistent. Second, the impact of biologics for mucus plugs might be different depending on the inflammatory phenotype of the patient. Third, allergic phenotype is also one of the important characteristics focused on the efficacy; however, related examinations such as skin prick test are not performed. Fourth, seasonal alternation of surrounding allergens might be also affected for improvement of mucus plugs.

Conclusion

Biologics including mepolizumab and dupilumab have been reported to improve mucus plugs in patients with asthma; however, their efficacy might be different depending on the clinical characteristics of patients. Present data remind us of the possibility that, if FeNO levels remain high after treatment with anti-IL-5 antibody in asthma patients with mucus plugs, switching to other biologics, including anti-IL-4R α antibody, might be considered.

Abbreviations

FeNO, fractional exhaled nitric oxide; CT, computed tomography; IgE, immunoglobulin E; IL-5, interleukin-5; IL-4R α , IL-4 receptor alpha; TSLP, thymic stromal lymphopoietin; ACT, asthma control test; VC, vital capacity; FEV₁, forced expiratory volume in 1 second.

Consent for Publication

The patient gave written consent to publish this material. Our institute of Saga University Hospital indicates that institutional approval for the case report is not applicable if written consent from the patient is obtained.

Author Contributions

All authors made a significant contribution to the work reported, whether that is in the conception, execution, acquisition of data and interpretation, or in all these areas; took part in drafting, revising or critically reviewing the article; gave final approval of the version to be published; have agreed on the journal to which the article has been submitted; and agree to be accountable for all aspects of the work.

Funding

This report was supported by the JSPS KAKENHI Grant Numbers 23K15210 and 24K23416.

Disclosure

Hiroki Tashiro received honoraria and research funding from AstraZeneca. Koichiro Takahashi received honoraria from AstraZeneca, GlaxoSmithKline, Sanofi, Nippon Boehringer Ingelheim and research fundings from GlaxoSmithKline, Nippon Boehringer Ingelheim.

References

1. Dunican EM, Elicker BM, Gierada DS, et al. Mucus plugs in patients with asthma linked to eosinophilia and airflow obstruction. *J Clin Invest*. 2018;128(3):997–1009. doi:10.1172/JCI95693
2. Tang M, Elicker BM, Henry T, et al. Mucus plugs persist in asthma, and changes in mucus plugs associate with changes in airflow over time. *Am J Respir Crit Care Med*. 2022;205(9):1036–1045. doi:10.1164/rccm.202110-2265OC
3. Dunican EM, Watchorn DC, Fahy JV. Autopsy and imaging studies of mucus in asthma. lessons learned about disease mechanisms and the role of mucus in airflow obstruction. *Ann Am Thoracic Soc*. 2018;15(Suppl 3):S184–s191. doi:10.1513/AnnalsATS.201807-485AW
4. Brusselle GG, Koppelman GH. Biologic Therapies for Severe Asthma. *New Engl J Med*. 2022;386(2):157–171. doi:10.1056/NEJMra2032506
5. Tang M, Charbit AR, Johansson MW, et al. Utility of eosinophil peroxidase as a biomarker of eosinophilic inflammation in asthma. *J Allergy Clin Immunol*. 2024;154(3):580–591.e6. doi:10.1016/j.jaci.2024.03.023
6. Svenningsen S, Kjarsgaard M, Haider E, et al. Effects of dupilumab on mucus plugging and ventilation defects in patients with moderate-to-severe asthma: a randomized, double-blind, placebo-controlled trial. *Am J Respir Crit Care Med*. 2023;208(9):995–997. doi:10.1164/rccm.202306-1102LE
7. Tajiri T, Suzuki M, Nishiyama H, et al. Efficacy of dupilumab for airway hypersecretion and airway wall thickening in patients with moderate-to-severe asthma: a prospective, observational study. *Allergol Int*. 2024;73(3):406–415. doi:10.1016/j.alit.2024.02.002
8. Global Initiative for Asthma 2024. Available from: <https://ginasthma.org/>. Accessed December 06, 2024.
9. Beasley R, Harper J, Bird G, Majiers I, Weatherall M, Pavord ID. Inhaled corticosteroid therapy in adult asthma. time for a new therapeutic dose terminology. *Am J Respir Crit Care Med*. 2019;199(12):1471–1477. doi:10.1164/rccm.201810-1868CI
10. Ortega HG, Liu MC, Pavord ID, et al. Mepolizumab treatment in patients with severe eosinophilic asthma. *New Engl J Med*. 2014;371(13):1198–1207. doi:10.1056/NEJMoa1403290
11. Castro M, Corren J, Pavord ID, et al. Dupilumab efficacy and safety in moderate-to-severe uncontrolled asthma. *New Engl J Med*. 2018;378(26):2486–2496. doi:10.1056/NEJMoa1804092
12. Gates J, Hearn A, Mason T, et al. Long-term effectiveness of anti-IL-4R therapy following suboptimal response to anti-IL-5/5R therapy in severe eosinophilic asthma. *J Allergy Clin Immunol Pract*. 2024;12(7):1794–1800. doi:10.1016/j.jaip.2024.03.049
13. Hayashi Y, Tanabe N, Matsumoto H, et al. Associations of fractional exhaled nitric oxide with airway dimension and mucus plugs on ultra-high-resolution computed tomography in former smokers and nonsmokers with asthma. *Allergol Int*. 2024;73(3):397–405. doi:10.1016/j.alit.2024.01.013
14. Nordenmark LH, Hellqvist Å, Emson C, et al. Tezepelumab and mucus plugs in patients with moderate-to-severe asthma. *NEJM evid*. 2023;2(10):EVIDoa2300135. doi:10.1056/EVIDoa2300135

Journal of Asthma and Allergy

Dovepress

Publish your work in this journal

The Journal of Asthma and Allergy is an international, peer-reviewed open-access journal publishing original research, reports, editorials and commentaries on the following topics: Asthma; Pulmonary physiology; Asthma related clinical health; Clinical immunology and the immunological basis of disease; Pharmacological interventions and new therapies. The manuscript management system is completely online and includes a very quick and fair peer-review system, which is all easy to use. Visit <http://www.dovepress.com/testimonials.php> to read real quotes from published authors.

Submit your manuscript here: <https://www.dovepress.com/journal-of-asthma-and-allergy-journal>