



## A very rare case of late diagnosis of cor triatriatum sinistrum

Ingrid Schusterova<sup>1</sup>, Martin Czerny<sup>2</sup>, Alexander Jurko Jr<sup>3</sup>, Milan Minarik<sup>4</sup>

<sup>1</sup>Cardiac Surgery Clinic, Eastern Heart Institute, Kosice 04011, Slovakia

<sup>2</sup>Department of Cardiovascular Surgery, University Hospital Zurich 8091, Switzerland

<sup>3</sup>Pediatric Cardiology Clinic, Jessenius Faculty of Medicine, Comenius University, Martin 03601, Slovakia

<sup>4</sup>Faculty of Health Care, Catholic University in Ruzomberok 03401, Slovakia

### Abstract

We presented a 73-year-old patient with a history of hospitalizations for heart failure as well as treatment for arterial hypertension and permanent atrial fibrillation and who was found to have cor triatriatum sinistrum in combination with bicuspid aortic valve. Patient refused surgical correction, but his condition improved on conservative therapy for heart failure and atrial fibrillation.

*J Geriatr Cardiol* 2015; 12: 185–186. doi:10.11909/j.issn.1671-5411.2015.02.013

**Keywords:** Congenital heart defect; Cor triatriatum; Echocardiography

### 1 Case report

A 73-year old male was referred for progression of dyspnea on exertion. His medical history revealed hospitalization for heart failure as well as treatment for arterial hypertension and permanent atrial fibrillation. Diagnosis was by transesophageal echocardiography showing a linear structure dividing the left atrium in two chambers (Figure 1). Pulmonary veins drained into the postero-superior chamber and the mitral valve and the left atrial appendage were located in the antero-inferior chamber. There was no atrial septal defect.

Consequently, the diagnosis of cor triatriatum sinistrum Class A according to the Lam classification was made.<sup>[1]</sup> The communication between both chambers was wide, corresponding to a Loeffler group 3.<sup>[2]</sup> Furthermore, the diagnosis of a calcified bicuspid aortic valve with moderate stenosis was established corresponding to a Sievers type classification of 1, L/R meaning one raphe between a fused left and right coronary cusp.<sup>[3]</sup> A classical combination of a sinus of Valsalva and ascending aortic dilatation was seen during CT angiography (Figure 2 & 3).

Surgical correction was proposed. However, the patient refused. Heart failure therapy was optimized, symptoms

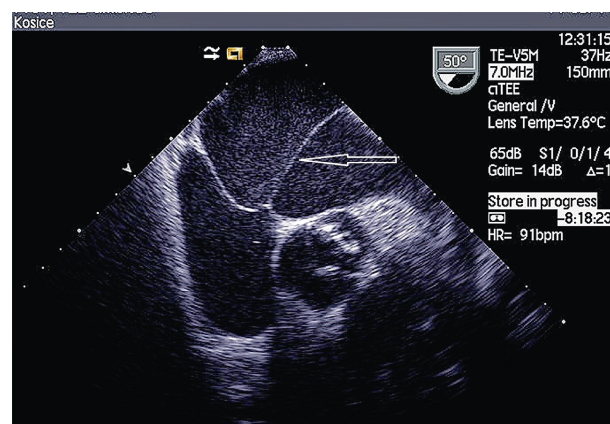


Figure 1. Transesophageal echocardiography showing a membrane dividing left atrium (arrow).

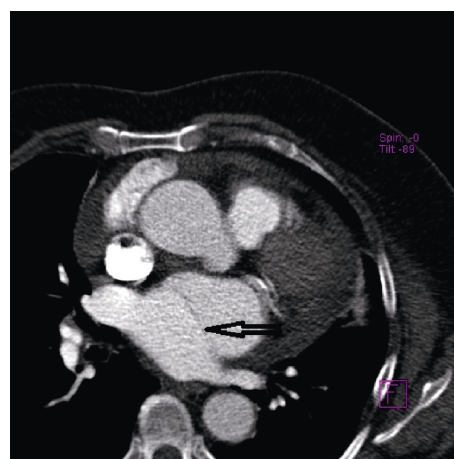
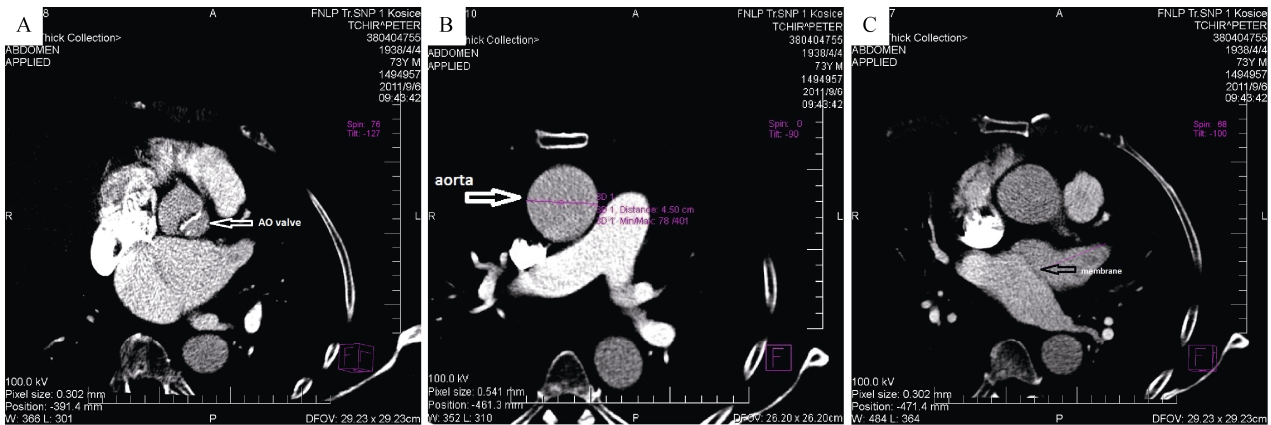


Figure 2. Corresponding CT axial slide showing the same finding (arrow).

**Correspondence to:** Alexander Jurko, Jr., MD, PhD, Pediatric Cardiology Clinic, Jessenius Faculty of Medicine, Comenius University, Kollarova 13, Martin 03601, Slovakia. E-mail: ltvsro@gmail.com

**Received:** November 25, 2014 **Revised:** December 1, 2014

**Accepted:** December 1, 2014 **Published online:** March 12, 2015



**Figure 3.** CTreconstruction showing the combined cardiac pathology of aortic valve calcification (A), sinus and ascending aortic ectasia (B), as well as the membrane (arrow) separating the left atrium into two chambers (C).

improved and he is currently seen on a regular basis in our outpatient clinic.

## 2 Discussion

Cor triatriatum sinistrum is rare. The combination with bicuspid aortic valve disease is even rarer, as is late presentation in life as in our patient, and a mere single digit report in the literature was available.<sup>[4]</sup> The median age in a recently published series of the Mayo clinic was 19 years.<sup>[5]</sup>

Several reasons may account for that exceptional late presentation in life. Obviously, functional obstruction of the membrane is moderate and, therefore, physiologically compensated. By the onset of atrial fibrillation, it might have been that symptoms occurred. However, this was not connected to a congenital defect, but due to the onset of atrial fibrillation per se.

Regarding diagnostics, transthoracic and transesophageal echocardiography have obviously become the treatment modalities of first choice to establish the correct diagnosis. Furthermore, the rare association with a bicuspid aortic valve was made. In our patient, additional CT angiography further revealed ectasia of the sinus of Valsalva as well as the ascending aorta. These are most likely the very aspects making this case report unique, as we were not able to iden-

tify a single case report where a clear categorization of Lam classification and Loeffler groups, as Sievers classification of bicuspidity, was established. Furthermore, this patient is one of the few who seems to do well with modification of heart failure therapy as well as rate control of atrial fibrillation.

Summarizing, the combination of cor triatriatum sinistrum and bicuspid aortic valve disease is a rare variation of nature. Furthermore, membranes with a larger effective orifice area might be treated conservatively in distinct clinical situations.

## References

- 1 Lam CR, Green E, Drake E. Diagnosis and surgical correction of 2 types of triatrial heart. *Surgery* 1962; 51: 127–137.
- 2 Loeffler E. Unusual malformation of the left atrium: pulmonary sinus. *Arch Pathol* 1949; 48: 371–376.
- 3 Sievers HH, Schmidke C. A classification system for the bicuspid aortic valve from 304 surgical specimens. *J Thorac Cardiovasc Surg* 2007; 133: 1226–1233.
- 4 Pirc B, Gersak B, Ruzic-Medvescek N. Cor triatriatum sinistrum, aortic coarctation and bicuspid aortic stenosis in an adult. *Eur J Cardiothorac Surg* 1996; 10: 1139–1140.
- 5 Saxena P, Burkhart HM, Schaff HV, et al. Surgical Repair of Cor Triatriatum Sinister: The Mayo Clinic 50-Year Experience. *Ann Thorac Surg* 2014; 97: 1659–1663.