



Contents lists available at ScienceDirect

North American Spine Society Journal (NASSJ)

journal homepage: www.elsevier.com/locate/xnsj

Clinical studies

An algorithm for selection of full endoscopic approach for symptomatic nerve root decompression



Prasad Patgaonkar, MS, DNB Orth, Vaibhav Goyal, DNB Orth*, Pratik Patel, MS Orth, Kiran Dhole, MS Orth, Achyut Ravi, MS Orth, Vivek Patel, MS Orth, Pushkar Borole, MS Orth

Indore Spine Centre, 5-6 RS Bhandari Marg, Indore, Madhya Pradesh 452009, India

ARTICLE INFO

Keywords:

FAPDIS
Algorithm
Transforaminal
Interlaminar
Full endoscopic spine surgery
Approach selection

ABSTRACT

Background Context: Both Transforaminal (TF) and Interlaminar (IL) endoscopic approaches are established techniques of decompression for lumbar compressive radiculopathy. In the absence of adequate literature, there is always some dilemma in selecting the approach for endoscopic decompression leading to long learning curves and high chances of inadequate decompression, iatrogenic instability, dural tear, or dysesthesia. Hence authors propose a new surgical nomenclature and algorithm for selection of endoscopic approach.

Methods: This retrospective study included 396 of 626 consecutive patients who met the inclusion criteria, who underwent either TF (n=302) or IL (n=202) full endoscopic spine surgery. MRI findings of every patient were classified as per FAPDIS (Facet angle, Anterior pathology, Posterior pathology, Dorsal, Inferior, and Superior migration) algorithm. Inter-observer variations were calculated. The targeted nomenclature was used to define the selection of endoscopic TF or IL approach for symptomatic nerve root decompression. All patients were followed up for preop and postop 6 months VAS and Oswestry Disability Index score for validation of FAPDIS algorithm.

Results: Median age: 46.8 years; Sides and levels operated 330 single-level ipsilateral, 54 multiple-level ipsilateral, 6 single-level bilateral, and 6 multiple-level bilateral. Interobserver agreement in the selection of TF approach was 0.873 and IL approach was 0.882. Interobserver variability was also calculated for each FAPDIS factor, selection of P3 and P4 pathology was the main reason for disagreement. All other FAPDIS factors show good to excellent correlation. The overall VAS score decreased from a preoperative value of 9 to 1 at 6 months follow-up (p-value < 0.001), and the overall Oswestry Disability Index score improved from 89 to 12 (p-value < .001).

Conclusions: The author's new FAPDIS surgical nomenclature and algorithm is a reliable tool for describing the symptomatic nerve root compression for the selection of endoscopic surgical approach to achieve adequate decompression of offending neural structure with minimum challenges to minimize perioperative complication rate.

Introduction

Lumbar disc herniation and stenosis often present as a combined problem in different stages of pathogenesis [1]. Current studies have not included co-existent stenosis and herniations. Consensus has developed regarding the amenability of endoscopic approaches for lumbar disc herniation and stenosis but currently, there are 2 schools of thought regarding endoscopic approaches (e.g., IL vs. TF) which are now gradually coming to specific indications of different lumbar pathologies [2].

We considered FAPDIS (Facet angle, Anterior pathology, Posterior pathology, Dorsal migration, Inferior migration, and Superior migra-

tion) factors such as facet joint orientation, offending anterior or posterior pathologies, and migration of herniated disc to select an easier approach. Although, none of the approaches are contraindicated, mastering any one technique can extend the indications of the same but mastering both techniques can provide an option of easier selection and safer ways to manage the problem.

At present, there is no algorithm for approach selection for full endoscopic spine surgery. The purpose of this article is to give the FAPDIS algorithm which will ease-out approach selection and reduce the learning curve and perioperative complication rate.

FDA device/drug status: Not applicable.

Author disclosures: **PP:** Nothing to disclose. **VG:** Nothing to disclose. **PP:** Nothing to disclose. **KD:** Nothing to disclose. **AR:** Nothing to disclose. **VP:** Nothing to disclose. **PB:** Nothing to disclose.

* Corresponding author: Shalby Hospitals, 5-6 RS Bhandari Marg, Indore, Madhya Pradesh 452009, India.

E-mail address: vgvgoyal1@gmail.com (V. Goyal).

<https://doi.org/10.1016/j.xnsj.2023.100244>

Received 2 March 2023; Received in revised form 13 July 2023; Accepted 13 July 2023

Available online 16 July 2023

2666-5484/© 2023 The Authors. Published by Elsevier Inc. on behalf of North American Spine Society. This is an open access article under the CC BY-NC-ND license (<http://creativecommons.org/licenses/by-nc-nd/4.0/>)

Table 1
Summary of demographic results.

Total patients	626
Included	396
Excluded	230
Total studied	396
Total FAPDIS motion segment	504
Median age	46.8
Sex	
Male	288
Female	216
Total	396
Levels	
L1L2	0
L2L3	54
L3L4	63
L4L5	243
L5S1	144
Side	
Unilateral one level	330
Unilateral multilevel	54
Bilateral one level	6
Bilateral multilevel	6
Approach	
TF	302
IL	202

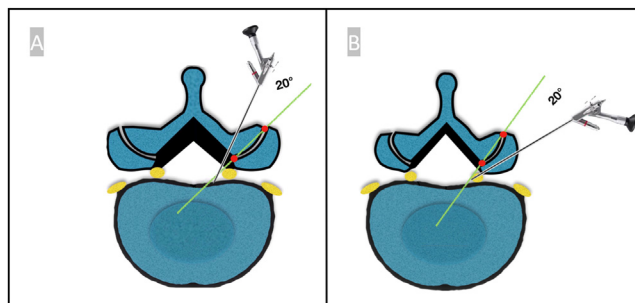


Fig. 1. FAPDIS motion segment – Endoscopic approach must have a minimum 20-degree angle to the facet inclination to have maximum bone resection possible for proper decompression without destabilizing the facet joint. (A) for interlaminar approach while (B) for transforaminal approach.

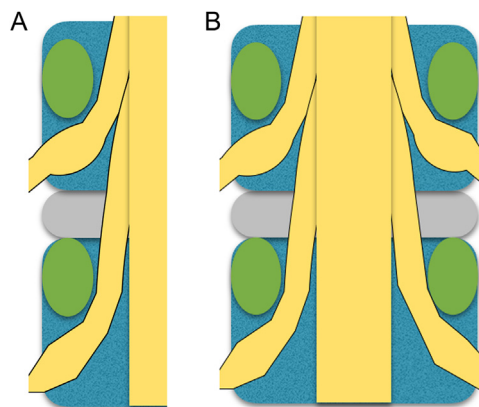


Fig. 2. FAPDIS motion segment – Individual FAPDIS algorithm is applied to different FAPDIS motion segments which is either bilateral symptomatic pathology in the same motion segment or multiple symptomatic nerve root compression in different motion segments.

Materials and methods

A retrospective observational study of 396 cases with a clinical diagnosis of symptomatic nerve root compression (over the last 4 years) performed by a single surgeon was conducted at a tertiary care spine center (Table 1) after Institutional review board (IRB) approval from Indore spine center and Shalby Hospital. X-ray, CT scan, and MRI images of these patients were studied, and based on clinical-radiological correlation a FAPDIS algorithm was designed. This algorithm includes all 6 factors which are the parts of FAPDIS algorithm (vide infra) based on surgical principles which affect the approach selection between TF and IL full endoscopic spine surgery without fusion.

All the cases of disc herniation and stenosis in lumbar levels L1 to S1 and Stable Grade 1 spondylolisthesis were included in the study. Patients with chemical Radiculitis without obvious compressive pathology, discogenic low back pain with internal disc derangement with or without annular fissure, settled disc space with foraminal stenosis, unstable low-grade spondylolisthesis, high-grade Spondylolisthesis were excluded from study.

The principles of endoscopic approach selection include facet orientation, minimal facetectomy, anterior and posterior targeted decompression, migration, and extent of herniation in targeted classification and avoiding Nerve Injury.

Endoscopic approach must have a minimum 20-degree angle to the facet inclination to have adequate bone resection possible for proper decompression without destabilizing the facet joint. (Fig. 1) This applies to both TF and IL approach. The approach should include minimum removal of articular part superior articular process (SAP) or inferior articular process (IAP). The extent of decompression to be planned by separate assessment of both anterior and posterior offending compressive pathology. Best full endoscopic access should be decided by individually assessing the superior or/and inferior migration along with the dorsal migration of herniation. The approach should be decided to have minimal or no retraction the of nerve root as far as possible.

FAPDIS algorithm

Individual FAPDIS algorithm is applied to either bilateral symptomatic pathology in the same motion segment or multiple symptomatic nerve root compression in different motion segments. (Fig. 2)

FAPDIS algorithm is used in order of its significance which is described below. (Fig. 3)

F stands for Facet orientation. The angle is measured as an angle between the line perpendicular to PLL and the line joining intra-articular dorsal points of SAP at the lower discal margin. *A* stand for Anterior compression as seen on a minimum 3 axial (Upper discal margin, mid disc, and lower discal margin) and 3 sagittal cuts (Central, Paracentral and foraminal) of MRI. *P* stand for Posterior compression as seen on a minimum 3 axial (Upper discal margin, mid disc, and lower discal margin) and 3 sagittal cuts (Central, Paracentral and foraminal) of MRI. *D* stand for Dorsal migration (either soft or hard) and is divided in near or far by the line joining the intracanalicular most medial point of the articular surface of SAP. *I* stand for the inferior extent of herniation on 3 equal divisions of the vertebral body in sagittal sections. *S* stands for the superior extent of migration on 3 equal divisions of the vertebral body in sagittal sections.

Further sub-types of all 6 above factors were done (Fig. 4) and individual score was given for both TF and IL approaches (Table 2) considering the surgical challenges with either approach. (Table 3) The maximum possible score for any symptomatic nerve root can be 12. Approach recommendation was given based on a higher final total comparative score that is, TF:IL score (where total score weighs more than any individual scores). The Individual score which is going against the final approach selection becomes the challenge for the approach, prior understanding of which, will help minimizing complications. When the difference between total comparative score is 0 (ie, TF = IL) or 0.5 (ie, TF < IL / TF > IL), then it's the surgeon's preference of the selection of approach.

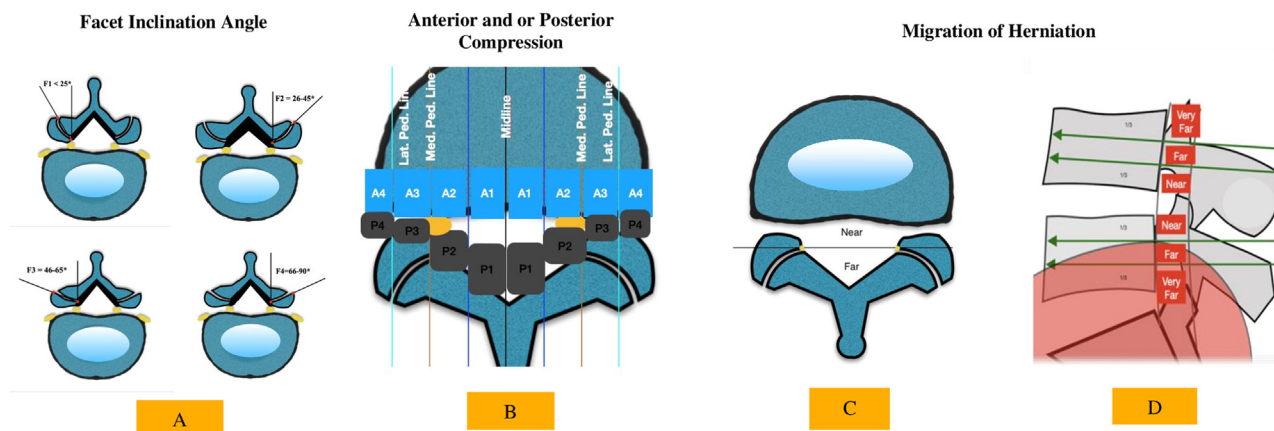


Fig. 3. Schematic diagram of FAPDIS – (A) Facet inclination types F1 to F4. (B) anterior and posterior pathology types. (C) extent of dorsal migration. (D) extent of inferior and superior migration.

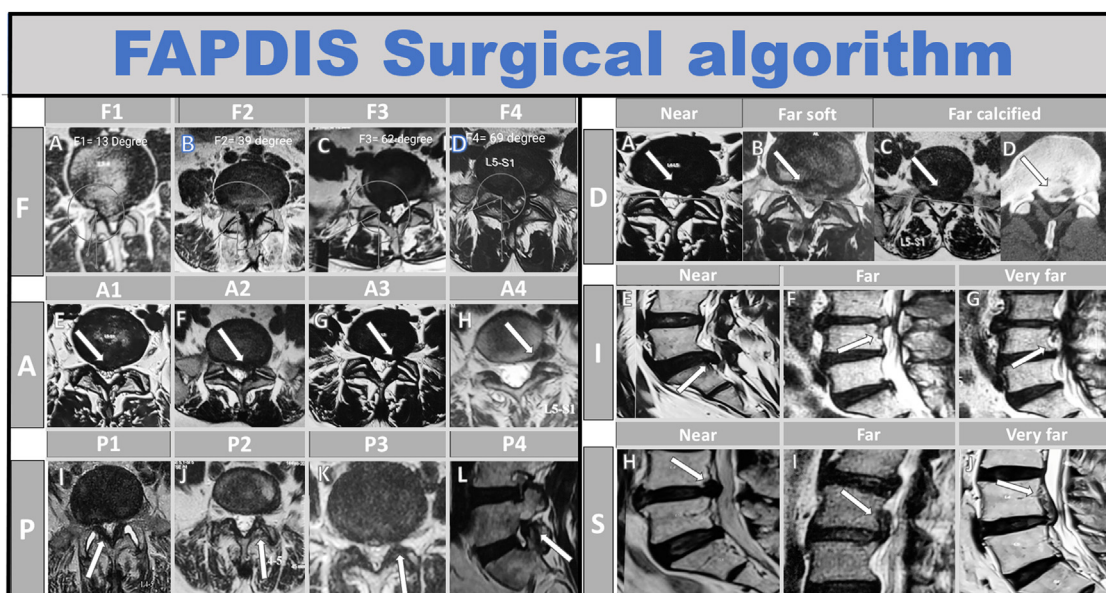


Fig. 4. FAPDIS radiological algorithm includes all the 6 factors (Facet angle, Anterior pathology, Posterior pathology, Dorsal migration, Inferior migration, and Superior migration).

Results

There were total 626 patients studied, out of which 230 patients were excluded due to the aforementioned criteria and total 396 patients were included, in which 504 FAPDIS motion segments were studied based on clinical dermatomal pattern of pain, correlating with symptomatic nerve root compression. The median age of this population was 46.8 years, out of which 288 were male and 216 were female.

There were 144 (28%) patients operated at L5S1 level, 243 (48%) at L4L5, 63 (12.5%) at L3L4, and 54 (10.7%) at L2L3. 261 patients were operated one level ipsilaterally, 54 patients were operated on more than one level ipsilaterally, 6 patients were operated on at one level on both sides, and 6 patients were operated on more than one level on both sides. (Table 4)

According to FAPDIS algorithm, there were 84 segments of F1 type, 156 of F2, 201 of F3, and 63 of F4. We found the offending pathology of type A0 was 6, A1 was 276, A2 was 333, A3 was 138, and A4 was 42. For posterior pathology, 138 segments had no posterior pathology which needed decompression. P1 type of offending pathology was 9, P2 was 198, P3 was 39 and P4 was 27. Out of 504 segments, dorsal near

migration was found in 264 segments. The soft type of far dorsal migration was found in 126 and calcified type of dorsal migration was found in 108. Inferior near migration was found in 120 segments and inferior far migration was found in 15. Superior near migration was found in 63 segments and superior far migration was found in 9. Out of 504 segments studied, 342 pathologies were managed by the TF approach (Fig. 5) and 162 IL approaches (Fig. 6) were preferred.

The overall VAS score decreased from a preoperative value of 9 to 1 at 6 months follow-up (p-value<.001), and the overall ODI score improved from 89 to 12 (p-value<.001).

Statistical analysis

The Statistical analysis was performed by SPSS 23.0 version. Continuous variables were described as mean and variation of each observation from the mean value (Standard deviation) represented as mean ± SD if they followed normal distribution and were described as Median (IQR) if they followed non normal distribution. Inter observer reliability was analyzed using Intraclass Coefficient as the scores were continuous data. This was done using the 2-way Mixed model with Absolute Agreement type of reliability analysis by taking the average measures of the analysis

Table 2
FAPDIS surgical algorithm scoring system for selection of endoscopic spine surgery (transforaminal vs. interlaminar).

Facet angle (F)	Description	TF score	IL score
F1	< 25	1	0
F2	25–45	1	0.5
F3	46–65	0.5	1
F4	66–90	0	1
Anterior pathology (A)			
A0	No anterior compression	0	0
A1	Central	1	1
A2	Paracentral	1	1
A3	Foraminal	1	0.5
A4	Extraforaminal	1	0
Posterior pathology (P)			
P0	No posterior compression	0	0
P1	Central flaval stenosis	0	1
P2	Lateral recess stenosis	0.5	1
P3	Lower foraminal stenosis	1	0.5
P4	Upper foraminal stenosis (SAP syndrome)	1	0
Dorsal migration (D)			
D-Zero	No dorsal migration	0	0
D- near	Not touching the line	1	1
D- far soft	Touching/Beyond the line	0.5	1
D- far calcified	Touching/Beyond the line	0	1
Inferior migration (I)			
Near	Upper third	1	1
Far	Middle third	0.5	1
Very far	Lower third	0	1
Superior migration (S)			
Near	Upper third	1	1
Far	Middle third	0.5	1
Very far	Lower third	0	1
Total score	Max possible score (n=12)	Comparative score (TF:IL)	

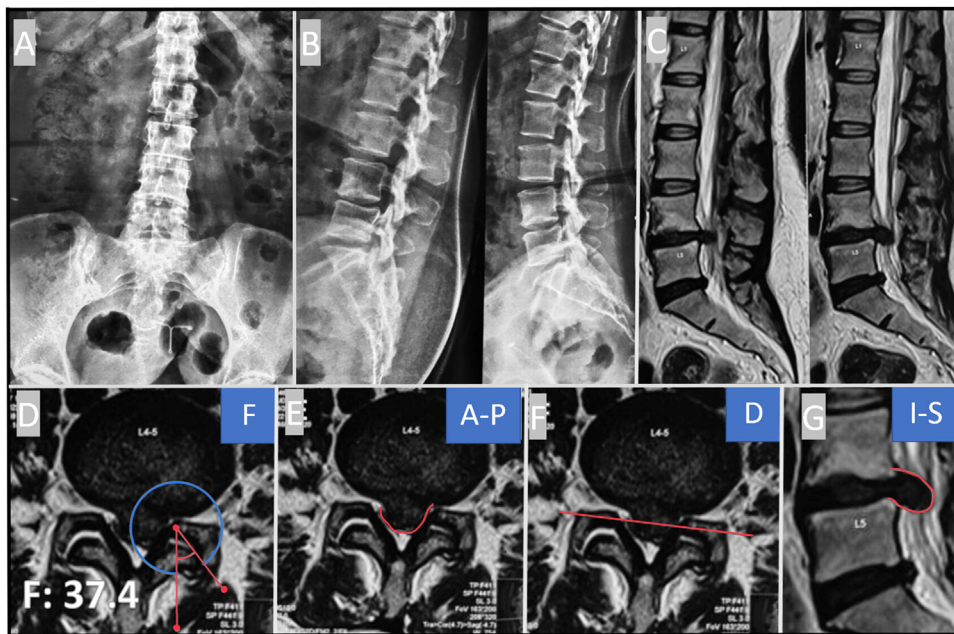


Fig. 5. FAPDIS description of transforaminal approach – A and B (X-ray LS Spine AP and Lateral): showing stable spine. (C) Sagittal T2 MRI showing Dorsal and inferior disc extrusion at L4/L5 level. (D–F) (FAPDIS Calculation): (D) Facet angle 37.2 (F2). (F) Anterior disc pathology without any posterior offending pathology. (D) Dorsal far soft disc herniation. (F) Inferior near disc herniation (FAPDIS calculation F2A1A1PODfsInS0; Total score (TF:IL = 4.5: 4.5).

(Table 5). Values less than 0.5 are indicative of poor reliability, values between 0.5 and 0.75 indicate moderate reliability, values between 0.75 and 0.9 indicate good reliability and values greater than 0.90 indicate excellent reliability (Table 6) [3].

Interobserver agreement was 0.873 in the selection of the TF approach and 0.882 in selection of the IL approach. Interobserver variability was also calculated for each FAPDIS factor, selection of P3 and P4 pathology was the main reason for disagreement. All other FAPDIS factors show good to excellent correlation. Continuous Paired data was analyzed using Wilcoxon Signed Rank Test (For non-normal distribution). Variables with p value <0.05 was considered as statistically significant.

Discussion

The spectrum of approach practiced today for lumbar disc herniation and stenosis includes open procedure, minimally invasive spine surgery including tubular system, full endoscopic discectomy and decompression, or endoscopic assisted procedures like micro-endoscopic decompression, standau, or unilateral biportal endoscopy [4,5].

Full endoscopic spine surgery represents the evolution of minimally invasive surgical access to spinal pathology. It has advantages such as minimal muscle and bone damage, less pain, early rehabilitation, reduced hospital stays and early return to work [6]. It provides high resolution, off-axis visualization of the surgical field and is associated

Table 3
FAPDIS description with TF:IL score and challenges.

FAPDIS	Description	TF score	IL score	Author's recommendation	Challenges for other approach	Recommendation to deal with challenges
Facet angle (F)	The angle is measured as an angle between the line perpendicular to PLL and line joining intraarticular dorsal points of SAP.					
F1	< 25	1	0	TF	IL- Very high risk of damage to IAP & Pars	IL- Contralateral approach
F2	26–45	1	0.5	TF > IL	IL- Risk of damage to IAP & Pars	IL- Contralateral approach
F3	46–65	0.5	1	IL > TF	TF- Risk of Exiting Nerve root injury	TF- Far lateral entry point, primary foraminotomy
F4	66–90	0	1	IL	TF- Very high risk of Exiting Nerve root injury and Removal of Non articular part of SAP	TF- Far lateral entry point, primary foraminotomy
Anterior (A)	Types of offending anterior pathology (Disc/ osteophyte/ discal cyst)					
A0	No anterior compression	0	0	Nil	Nil	Nil
A1	Central	1	1	TF = IL	TF- Exiting Nerve root injury IL- Traversing root retraction	IL- medial facetectomy, mobilization of traversing root. TF- far lateral entry point, primary foraminotomy, medialisation of annulotomy.
A2	Paracentral	1	1	TF = IL	Nil	Depends on facet orientation
A3	Foraminal	1	0.5	TF > IL	IL- Risk of damage to IAP & Pars	IL- contralateral approach
A4	Extraforaminal	1	0	TF	IL- Inadequate Decompression and risk of damage to IAP and pars	IL- contralateral approach
Posterior (P)	Types of offending posterior pathology (Flavum hypertrophy/ osteophyte/ IAP or SAP Facet hypertrophy, facet cyst)					
P0	No posterior compression	0	0	Nil	Nil	Nil
P1	Central flaval stenosis	0	1	IL	TF - High chances of inadequate decompression	TF not recommended
P2	Lateral recess stenosis	0.5	1	IL > TF	TF- Inadequate posterior decompression depends on Facet orientation	TF- Far lateral entry point, primary foraminotomy
P3	Lower foraminal stenosis	1	0.5	TF > IL	IL - Risk of damage to IAP & Pars, inadequate decompression	IL- Contralateral approach
P4	SAP syndrome (upper foraminal stenosis)	1	0	TF	IL - Very high risk of damage to IAP & Pars, inadequate decompression	IL- Contralateral approach
Dorsal Migration (D)	Divided in near & far by the line joining intracanal most medial points of the articular surface of SAP on both sides.					
D-zero	No dorsal migration	0	0	Nil	Nil	Nil
D-Near	Offending anterior pathology not touching the line	1	1	TF = IL	Depends on Facet Orientation	Nil-
D-Far Soft	Offending anterior pathology on or beyond the line	0.5	1	IL > TF	TF- Exiting Nerve root injury, Inadequate decompression IL- Risk of damage to IAP & Pars (Depends on Facet Orientation) TF- Inadequate decompression	TF- Far lateral entry point, primary foraminotomy. IL- Medial facetectomy, mobilization of traversing root. Mechanical tools eg, laser, tip control burr is required.
D-Far Calcified	Offending calcified anterior pathology on or beyond the line	0	1	IL	TF- Inadequate decompression	Mechanical tools eg, laser, tip control burr is required.
Inferior	Inferior migrations are divided in near, far & very far based on 3 equal division of Lower vertebral body in sagittal sections					
I-Zero	No inferior migration	0	0	Nil	Nil	Nil
I-Near	Upper third	1	1	TF = IL	Depends on Facet Orientation	
I-Far	Middle third	0.5	1	IL > TF	TF- Inadequate decompression,	Primary foraminotomy (partial pediculotomy)
I-Very Far Superior	Lower third	0	1	IL	TF- Inadequate decompression,	Trans-pedicular approach
Superior	Superior migrations are divided in near, far & very far based on 3 equal division of Upper vertebral body in sagittal sections					
S-Zero	No superior migration	0	0	Nil	Nil	Nil
S-Near	Lower third	1	1	TF = IL	Depends on Facet Orientation	
S-Far	Middle third	0.5	1	IL > TF	TF- Inadequate decompression	Primary foraminotomy (partial pediculotomy)
S-Very Far	Upper third	0	1	IL	TF- Inadequate decompression	Trans-pedicular approach

with a favorably low rate of perioperative and postoperative complications compared with minimally invasive spine surgery (MISS) or traditional spine surgery [7].

Historically, the use of endoscopic spinal surgery was limited to discectomies but recently its indications have widened to include lumbar spinal stenosis and fusion [8,9]. There has been a steady and persistent technical advancement, and popularity in full endoscopic TF and IL surgery for addressing the disc pathology and stenosis since the last couple of decades. As this field continues to expand and evolve, it is critical for surgeons to address the mélange of endoscopic procedures within the literature to provide a solid foundation for future scholarship.

There is a lack of literature for the selection of approaches between Full endoscopic TF or IL surgery. Hence, the author believes that it is critical to construct and define a consistent nomenclature and algorithm to clearly define approach selection for full-endoscopic procedures.

The IL and TF full endoscopic spine surgeries have been the representatives for the full endoscopic spine surgery (FESS) [6]. Each technique has developed many modified skills in treating different pathologies. Modern TF endoscopic spine surgery has been evolved for the last couple of decades [10,11,12], starting from Kambin's era [13,14,15] to visualize the disc pathology through a "triangular safe zone".

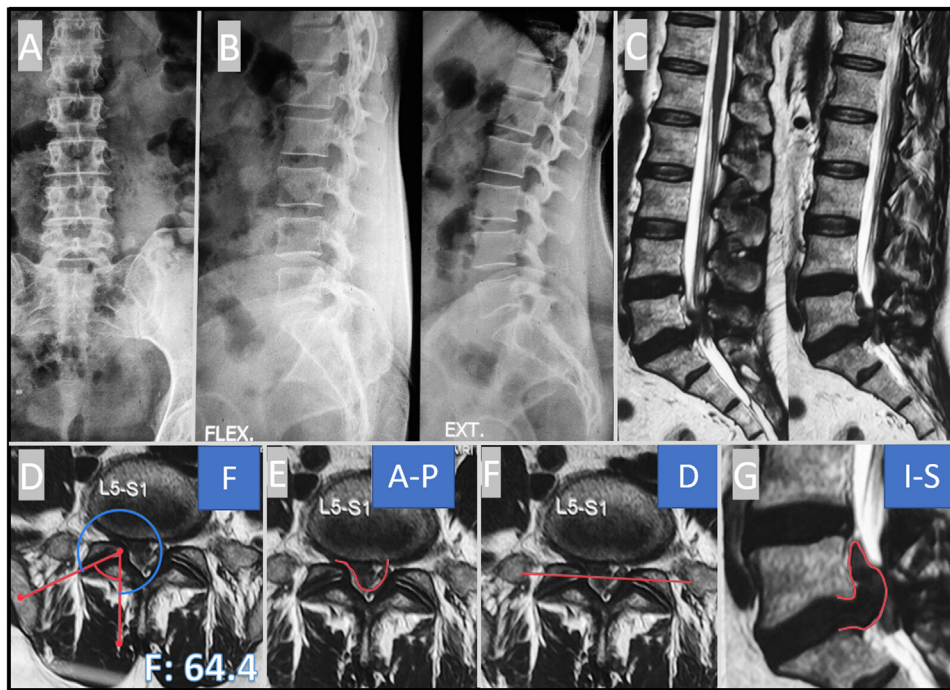


Fig. 6. FAPDIS description of interlaminar approach – A and B (X-ray LS Spine AP and Lateral): showing stable spine. (C) Sagittal T2 MRI showing Dorsal and superior disc extrusion at L4/L5 level. (D–G) (FAPDIS Calculation) : (D) Facet angle 64.4 (F3). (E) Anterior disc pathology without any posterior offending pathology. (F) Dorsal far soft disc herniation. (G) Inferior far disc herniation (FAPDIS calculation F3A1A2PODfsvf; Total score (TF:IL = 3: 5).

Table 4
Summary of results (FAPDIS factor distribution).

FACET	
F1	84
F2	156
F3	201
F4	63
Anterior	
A0	6
A1	276
A2	333
A3	138
A4	42
Posterior	
P1	9
P2	198
P3	39
P4	27
Dorsal migration	
Near soft	264
Far soft	126
Far calcified	108
Inferior migration	
Near	120
Far	15
Very far	0
Superior migration	
Near	63
Far	9
Very far	0

Various techniques have been developed like Destandau technique [16], Yeung “Inside-out” [17] technique, Hoogland “outside-in technique” [18–21], Lee’s half and half epiduroscopic approach [22], foraminoplasty approach by Choi et al. [23], L5-S1 IL access by Ruetten [24] and, “mobile outside-in” technique by Kim et al [25] for migrated disc herniation.

Evolution of IL endoscopy was done as an alternative to L5S1 TELD (Transforaminal endoscopic lumbar discectomy). TELD at the L5–S1 level is sometimes technically challenging due to anatomical limitation of surgical access through posterolateral approach due to high iliac crest,

smallest intertransverse space and narrow foramen and wide facet joint [25]. This limitation of approaching L5S1 TF area was addressed by the author’s earlier recommendation [26].

Earlier, IELD (Interlaminar endoscopic lumbar discectomy) was effective mainly in treating nonmigrated or low-grade migrated soft disc at L5–S1 level. Now its indication has extended to far migrated disc herniation, central stenosis, lateral recess stenosis, foraminal stenosis, facet cyst for all the levels including L2 to S1 [8,27].

Approach selection between IL and TF is very crucial for targeted symptomatic nerve root decompression. Plethora of literature is available for individual techniques and their extended indication, but literature on approach selection is lacking. TF approach has limitations in addressing very far migrated disc herniation, central canal stenosis, developmental narrow canal, calcified central disc, and multilevel bilateral pathologies. But due to advancement of techniques, all these pathologies can be addressed by burring the SAP (Foraminotomy), medialization of annulotomy, and various entry point selection methods [26,28].

Similarly, IL approach is challenging for sagittally oriented facet (F1 and F2), foraminal and extraforaminal disc herniation/stenosis is difficult. Adequate decompression without compromising the stability of the motion segment is very crucial for a successful outcome.

Osman, et al. presented a novel comprehensive classification on degenerative spinal motion-segment disease [29,30]. Such comprehensive classification allows standardization of treatment options for various combinations of the pathological processes in the disc, facet joint, ligamentum flavum, and spinal alignment. The classification attempts to assign treatment options to different disease combinations to help standardize surgical management of spinal motion-segments in an era of rapid technological transition to less invasive spine surgery.

The method of approach selection between TF and IL full endoscopic spine surgery is currently lacking in the literature. Facet joint orientation and prevention of facet instability following procedure is the key for the preservation of the motion segment [31]. To achieve a targeted nerve root decompression, there are a lot of factors which needs consideration such as facet joint orientation, anterior (disc herniation/ osteophyte/ discal cyst) or posterior (flavum hypertrophy/ osteophyte/ IAP or SAP facet hypertrophy, facet cyst) compressive pathologies, disc migration, spinal level, and stability. Therefore, the authors recommendation of

Table 5
Mean score for all observers.

Factor	Individual Scores		Vaibhav	Pratik	Prasad	Achyut
F	TF	Mean±SD	0.75±0.28	0.67±0.27	0.62±0.25	0.73±0.28
	IL		0.7±0.31	0.8±0.28	0.82±0.33	0.75±0.25
A	TF		1.98±0.72	2.1±0.71	2.3±0.79	2.3±0.59
	IL		1.88±0.58	1.87±0.68	1.92±0.57	2.02±0.55
P	TF		0.12±0.38	0.2±0.53	0.22±0.41	0.07±0.28
	IL		0.12±0.31	0.23±0.49	0.3±0.53	0.08±0.32
D	TF		0.75±0.31	0.82±0.28	0.57±0.36	0.85±0.26
	IL		0.93±0.25	0.97±0.18	0.8±0.41	0.97±0.18
I	TF		0.42±0.49	0.32±0.46	0.43±0.5	0.57±0.5
	IL		0.43±0.5	0.33±0.48	0.43±0.5	0.57±0.5
S	TF		0.2±0.38	0.07±0.21	NA	0.07±0.21
	IL		0.3±0.46	0.17±0.38	0.07±0.25	0.13±0.34
Total	TF		4.23±1.17	4.17±1.38	4.1±1.31	4.6±0.9
Total	IL		4.32±1.02	4.4±1.14	4.35±1.07	4.55±0.86

Table 6
Intraclass correlation coefficient.

	Individual scores	Intraclass correlation coefficient	95% CI (lower bound)	95% CI (upper bound)
F	TF	0.91	0.838	0.954
	IL	0.893	0.813	0.944
A	TF	0.83	0.703	0.911
	IL	0.885	0.8	0.94
P	TF	0.738	0.545	0.863
	IL	0.729	0.532	0.857
D	TF	0.653	0.403	0.817
	IL	0.533	0.205	0.752
I	TF	0.868	0.769	0.931
	IL	0.877	0.784	0.935
S	TF	0.448	0.018	0.714
	IL	0.844	0.725	0.919
Total	TF	0.873	0.779	0.934
Total	IL	0.882	0.794	0.938

Interpretation of intraclass correlation coefficient.

Values less than 0.5 are indicative of poor reliability, values between 0.5 and 0.75 indicate moderate reliability, values between 0.75 and 0.9 indicate good reliability, and values greater than 0.90 indicate excellent reliability.

the FAPDIS algorithm, which addresses all the factors for symptomatic nerve root decompression without compromising the facet stability, is the new algorithm and workhorse for the full endoscopic spine surgeons.

Facet orientation is crucial in selection of approach between TF and IL, as facet joint is the main stabilizer for the motion segment. IAP contributes to central and lateral recess stenosis, while SAP contributes in lateral recess and foraminal stenosis. Hence, the removal of offending part of facet is important for symptomatic nerve root decompression as well as its preservation plays an equal role in good outcome. Hence, author recommend minimum 20-degree angle between facet inclination and endoscopic approach.

Facet inclination changes from relative sagittal to coronal orientation from L1 to S1. TF approach is easier in upper lumbar spine because of sagittally oriented facet as burring the non-articular part of SAP (foraminotomy) does not lead to instability. In coronally oriented facets, aggressive removal of SAP may lead to iatrogenic instability hence access to dorsally migrated central disc herniation becomes challenging. IL approach became more popular at L5S1 level due to high iliac crest making TF approach more challenging. Whereas, wider IL window and coronal facet orientation makes IL approach feasible, and less likely to create iatrogenic instability. IL approach in sagittally oriented facet, may lead to instability due to aggressive removal of IAP in foraminal and extraforaminal stenosis.

According to the FAPDIS algorithm, Facet orientation has been classified into 4 types (F1 = less than 25, F2 = 26–45, F3 = 46–65, and F4 = 66–90). Selection of approach depends on preoperative orientation of facet angle which could reduce the chance of postoperative motion

segment instability. F1 Facet angle is ideal for TF and F4 facet angle is ideal for IL. For F2 and F3 facet angle, approach selection will need further consideration of other factors of FAPDIS algorithm.

Anterior pathology is mainly due to disc herniation, osteophyte, and discal cyst. It has been divided in 4 parts (A1 = central, A2 = paracentral, A3 = foraminal, A4 = extra-foraminal). A2 and A3 can be accessed by TF and IL approach without difficulty. But, A1 and A4 pathology needs further technical consideration of facet inclination for approach selection. A1 pathology poses a technical challenge for TF endoscopic decompression due to its location, proximity of retroperitoneal structures in the path of the trajectory and difficulty in accessing the herniation [32]. To overcome these problems and to gain direct access to the epidural space, Ruetten et al [24] described a far lateral entry.

Posterior pathology is due to flavum hypertrophy, osteophyte, IAP or SAP hypertrophy, and facet cyst, which can lead to central, lateral recess or foraminal stenosis. It has been divided in 4 categories P1 to P4.

P1 denotes compressive pathology leading to central canal stenosis (Flavum). Hence, author's recommendation for P1 Pathology is IL. P2 pathology has been divided in P2F (lateral canal stenosis due to flavum) and P2FS (Lateral canal stenosis due to flavum with overhanging part of SAP). P3 pathology is due to facet osteophyte in lower foramen. P2 and P3 both can be managed with either approach, but selection depends on facet orientation and other factors of FAPDIS algorithm. P4 denotes upper foraminal compression due to tip of SAP compressing exiting nerve root (SAP syndrome). Recommendation for P4 pathology is TF. P4 component commonly associated with reduced disc space, multifocal compression and facet arthropathy with or without instability.

Hence, judicious selection of surgical procedure is required. In case of full endoscopic decompression ipsilateral TF approach or contralateral IL endoscopic lumbar foraminotomy is required [8,33].

Disc migration has been divided in dorsal, superior, and inferior [34,35]. *Dorsal migration* (either soft or hard) is divided in near or far by the line joining intracanal most medial point of the articular surface of SAP. Near dorsal migration, either soft or hard as well as soft far herniation can be managed by TF approach. Author's recommendation for far migrated calcified disc herniation is IL approach as TF approach carries risk of inadequate decompression, excessive removal of articular part of SAP leading to instability.

Superior or inferior migration has been divided into near, far and very far migration. For near migration, selection of TF or IL approach depends upon the other factor of FAPDIS such as facet orientation, posterior flaval component, and dorsal extent of near migration.

Author's recommendation for far and very far migration is IL over TF approach as TF approach may need aggressive removal of pedicle or SAP. Hence, it becomes more difficult and challenging. The evolution of instruments and techniques has enabled the use of TF approach to assess high migrated lumbar disc herniation. Many spine surgeons have developed novel TF techniques for managing high grade migrated lumbar disc herniation by modified skin entry point, supra-pedicular approach, transpedicular approach, or mobile-in technique. Extending the indication of a single approach makes the procedure more challenging with higher complication rate. Hence, authors recommend IL approach for high grade migration which can address all 3 story of motion segment.

FAPDIS algorithm provides score to TF and IL access. Authors recommend an approach selection based on higher total comparative score (TF:IL). Recommended approach will reduce the chance of complications like inadequate decompression, excessive nerve root handling leading to dysesthesia, excessive facet removal leading to instability, and revision surgery.

This new nomenclature of FAPDIS algorithm is a comprehensive and descriptive surgical classification which will improve communication between spine clinicians. It is reproducible and will allow better surgical decision making for different types of compressive pathologies.

The proposed algorithm is applicable to any TF endoscopic (full endoscopic/ stenoscopic/ endoscopic assisted techniques) and any IL endoscopic (full endoscopic/ unilateral biportal/ endoscopic assisted techniques). With the evolution of full endoscopic spine surgery, this algorithm can be further modified for cervical and thoracic spine pathologies. The multi-centric study will be needed for further validation of this surgical algorithm.

The authors plan to produce FAPDIS calculator (software application) which will take all the component of FAPDIS algorithm. It will make the inference and decision making easier. Sometimes we also find that a full endoscopic approach may require more than 1 access in the same or different stages to avoid open decompression or fusion surgery as an alternative surgical technique.

In the current scenario there are no contraindications to any single technique as many surgeons have mastered different surgical techniques with their own modifications to deal with different types of compressive pathologies. Hence, the FAPDIS algorithm is an attempt to offer recommendations for the beginners to have the safest and easiest way to deal with the particular type of compressive pathologies. Knowing and mastering both the approaches is recommended as they allow 360 degree access for the decompression of thecal sac.

Conclusions

FAPDIS algorithm offers the safest and easiest full endoscopic approach selection to deal with the particular type of compressive pathology for symptomatic nerve root decompression. This comprehensive nomenclature and algorithm is reproducible and, will improve communication between spine clinicians. FAPDIS software and calculator will

make it more user friendly and will further reduce the interobserver variability.

Declaration of Competing Interest

This manuscript is not meant for or intended to endorse any products or push any other agenda other than the associated clinical outcomes with endoscopic spine surgery. The motive for compiling this clinically relevant information is by no means created and/or correlated to directly enrich anyone due to its publication. This publication was intended to substantiate contemporary endoscopic spinal surgery concepts to facilitate technology advancements.

Acknowledgments

The authors declare that they have no known competing financial interests or personal relationships that could have appeared to influence the work reported in this paper.

References

- [1] Kobayashi S. Pathophysiology, diagnosis and treatment of intermittent claudication in patients with lumbar canal stenosis. *World J Orthop* 2014;5(2):134–45.
- [2] Yue JJ, Long W. Full endoscopic spinal surgery techniques: advancements, indications, and outcomes. *Int J Spine Surg* 2015;9:17. doi:10.14444/2017.
- [3] Koo TK, Li MY. A guideline of selecting and reporting intraclass correlation coefficients for reliability research. *J Chiropr Med* 2016;15(2):155–63.
- [4] Hofstetter CP, Ahn Y, Choi G, et al. AOSpine consensus paper on nomenclature for working-channel endoscopic spinal procedures. *Global Spine J* 2020;10(2 Suppl):111S–121S. doi:10.1177/2192568219887364.
- [5] Härtl R. The 6 T's of minimally invasive spine surgery. *Global Spine J* 2020;10(2 Suppl):5S–7S. doi:10.1177/2192568220911617.
- [6] Kim M, Kim HS, Oh SW, et al. Evolution of spinal endoscopic surgery. *Neurosurg* 2019;16(1):6–14. doi:10.14245/ns.1836322.161.
- [7] McGrath LB Jr, White-Dzuro GA, Hofstetter CP. Comparison of clinical outcomes following minimally invasive or lumbar endoscopic unilateral laminotomy for bilateral decompression. *J Neurosurg: Spine SPI* 2019;30(4):491–9.
- [8] Lim KT, Nam HGW, Kim SB, et al. Therapeutic feasibility of full endoscopic decompression in one- to three-level lumbar canal stenosis via a single skin port using a new endoscopic system, percutaneous stenoscopic lumbar decompression. *Asian Spine J* 2019;13(2):272–82. doi:10.31616/asj.2018.0228.
- [9] Lokhande PV. Full-endoscopic interlaminar surgery of lumbar spine: role in stenosis and disc pathologies. *Indian Spine J* 2020;3(1):66–77.
- [10] Kim HS, Raorane HD, Wu PH, Yi YJ, Jang IT. Evolution of endoscopic transforaminal lumbar approach for degenerative lumbar disease. *J Spine Surg* 2020;6(2):424–37. doi:10.21037/jss.2019.11.05.
- [11] Khandge AV, Sharma SB, Kim JS. The evolution of transforaminal endoscopic spine surgery. *World Neurosurg* 2021;145:643–56. doi:10.1016/j.wneu.2020.08.096.
- [12] Chen KT, Jabri H, Lokanath YK, Song MS, Kim JS. The evolution of interlaminar endoscopic spine surgery. *J Spine Surg* 2020;6(2):502–12. doi:10.21037/jss.2019.10.06.
- [13] Kambin P. Arthroscopic microdiscectomy of the lumbar spine. *Clin Sports Med* 1993;12(1):143–50.
- [14] Kambin P, Casey K, O'Brien E, Zhou L. Transforaminal arthroscopic decompression of lateral recess stenosis. *J Neurosurg* 1996;84:462–7.
- [15] Kambin P, Zhou L. Arthroscopic discectomy of the lumbar spine. *Clin Orthop* 1997;337:49–57.
- [16] Destandau J. A special device for endoscopic surgery of lumbar disc herniation. *Neurol Res* 1999;21:39–42. doi:10.1080/01616412.1999.11740889.
- [17] Yeung AT. Minimally invasive disc surgery with the yeung endoscopic spine system (YESS). *Surg Technol Int* 1999;8:267–77.
- [18] Hoogland T. Transforaminal endoscopic discectomy with foraminoplasty for lumbar disc herniation. *Surg Tech Orthop* 2003:1–6.
- [19] Hoogland T, Scheckenbach C. Die endoskopische transforaminale Diskektomie bei lumbalen Bandscheibenvorfällen. *Orthop Prax* 1998;34:352–5.
- [20] Hoogland T, Schubert M, Miklitz B, et al. Transforaminal posterolateral endoscopic discectomy with or without the combination of a low-dose chymopapain: a prospective randomized study in 280 consecutive cases. *Spine* 2006;31:E890–7. doi:10.1097/01.brs.0000245955.22358.3a.
- [21] Hoogland T, van den Brekel-Dijkstra K, Schubert M, et al. Endoscopic transforaminal discectomy for recurrent lumbar disc herniation: a prospective, cohort evaluation of 262 consecutive cases. *Spine* 2008;33:973–8. doi:10.1097/BRS.0b013e31816c8ade.
- [22] Lee S, Kim SK, Lee SH, et al. Percutaneous endoscopic lumbar discectomy for migrated disc herniation: classification of disc migration and surgical approaches. *Eur Spine J* 2007;16:431–7. doi:10.1007/s00586-006-0219-4.
- [23] Choi G, Lee SH, Lokhande P, et al. Percutaneous endoscopic approach for highly migrated intracanal disc herniations by foraminoplasty technique using rigid working channel endoscope. *Spine (Phila Pa 1976)* 2008;33:E508–15. doi:10.1097/BRS.0b013e31817bfa1a.

- [24] Ruetten S, Komp M, Godolias G. A New full-endoscopic technique for the interlaminar operation of lumbar disc herniations using 6-mm endoscopes: prospective 2-year results of 331 patients. *Minim Invasive Neurosurg* 2006;49:80–7. doi:10.1055/s-2006-932172.
- [25] Kim HS, Yudoyono F, Paudel B, et al. Analysis of clinical results of three different routes of percutaneous endoscopic transforaminal lumbar discectomy for lumbar herniated disk. *World Neurosurg* 2017;103:442–8. doi:10.1016/j.wneu.2017.04.008.
- [26] Patgaonkar P, Datar G, Agrawal U, et al. Suprailiac versus transiliac approach in transforaminal endoscopic discectomy at L5-S1: a new surgical classification of L5-iliac crest relationship and guidelines for approach. *J Spine Surg* 2020;6(Suppl 1):S145–54. doi:10.21037/jss.2019.09.14.
- [27] Wu PH, Kim HS, Jang IT. A narrative review of development of full-endoscopic lumbar spine surgery. *Neurospine* 2020;17(Suppl 1):S20–33. doi:10.14245/ns.2040116.058.
- [28] Datar GP, Shinde A BK. Technical consideration of transforaminal endoscopic spine surgery for central herniation. *Indian J Pain* 2017;31(2):86–93] and [32 above patgaonkar sir article.
- [29] Osman SG, Narayanan M, Winters C. Anatomic treatment-based classification of diseased lumbar spinal motion-segment. *IJNSS* 2013;1:1–10.
- [30] Osman SG. Anatomic image-based classification of lumbar intervertebral disc pathologies. *Cureus* 2021;13(8):e16861. doi:10.7759/cureus.16861.
- [31] Jaumard NV, Welch WC, Winkelstein BA. Spinal facet joint biomechanics and mechanotransduction in normal, injury and degenerative conditions. *J Biomech Eng* 2011;133(7):071010. doi:10.1115/1.4004493.
- [32] Lee JU, Park KJ, Kim KH, et al. What is the ideal entry point for transforaminal endoscopic lumbar discectomy? *J Korean Neurosurg Soc* 2020;63(5):614–22. doi:10.3340/jkns.2020.0050.
- [33] Kim JY, Kim HS, Jeon JB, Lee JH, Park JH, Jang IT. The novel technique of uniportal endoscopic interlaminar contralateral approach for coexisting L5-S1 lateral recess, foraminal, and extraforaminal stenosis and its clinical outcomes. *J Clin Med* 2021;10(7):1364. doi:10.3390/jcm10071364.
- [34] Fardon DF, Milette PC Combined Task Forces of the North American Spine Society, American Society of Spine Radiology, and American Society of Neuroradiology. Nomenclature and classification of lumbar disc pathology. Recommendations of the Combined task Forces of the North American Spine Society, American Society of Spine Radiology, and American Society of Neuroradiology. *Spine (Phila Pa 1976)* 2001;26(5):E93–E113. doi:10.1097/00007632-200103010-00006.
- [35] Lee S, Kim SK, Lee SH, et al. Percutaneous endoscopic lumbar discectomy for migrated disc herniation: classification of disc migration and surgical approaches. *Eur Spine J* 2007;16(3):431–7. doi:10.1007/s00586-006-0219-4.