

Cervical Lymph Nodes: Harbinger of Benign Inclusions As Well As Metastatic Deposits of Thyroid Malignancy

Abstract

Lymph nodes can be harbinger to benign epithelial inclusions as well as metastatic deposits. Cervical lymph nodes are home to benign epithelial inclusions from thyroid better known as lateral aberrant thyroid as well as inclusions from salivary gland due to the unique embryologic origins of nodes with these organs. We present a case of a young female suspected of thyroid malignancy who was intraoperative diagnosed by frozen sections with papillary carcinoma of the thyroid along with bilateral cervical nodes (Level I–V) positive for reactive lymphadenopathy with Level II node being positive to benign salivary gland inclusions and Level VI node being positive to metastatic deposits of papillary carcinoma of the thyroid.

Keywords: *Aberrant thyroid inclusions, benign epithelial inclusions, cervical lymph nodes, metastatic deposits*

Introduction

Lymph nodes are unique anatomical stations belonging to the reticuloendothelial system. The lymph nodes not only harbinger primary neoplastic pathologies such as non-Hodgkin's lymphoma and Hodgkin's lymphoma but are also major sites for facilitating spread of malignancies. The histopathology reporting of lymph nodes needs to be judiciously carried out for precise cancer staging. It majorly reflects on the patient's prognostic outcome besides involving critical decisions for therapeutic interventions. However, a treating surgeon and a surgical histopathologist should be extremely aware and cautious regarding the presence of aberrant lymph node inclusions which can masquerade the metastatic and mislead the management through faulty reporting and staging. Depending on the site or group of lymph nodes present near the primary malignancy, the aberrant inclusions expected for the site may vary; hence, a detail anatomical mapping and predictable, normal aberrant inclusions to be expected should be known so as to explicitly demarcate it from metastasis.

Case Report

A 20-year-old female presented to the thyroid clinic with a neck lump and

bilateral lymphadenopathy of 6-month duration, clinical findings, and magnetic resonance imaging were suggestive as multinodular goiter; however, a fine needle aspiration biopsy subsequently reported the lump as suspicious of thyroid malignancy. Because of the dilemma and an inconclusive diagnosis, the case was kept for tentative total thyroidectomy with bilateral neck dissection of cervical nodes subject to intraoperative diagnosis through frozen sections. The lymph nodes resection intraoperatively would aid in restricting the spread of malignancy by removing metastatic lymph nodes and also help in lymph node staging of disease and prognosis.

The intraoperative procedure involved an initial incisional biopsy of the thyroid mass, which on frozen section confirmed papillary carcinoma of the thyroid. Subsequently, bilateral radical neck dissection was carried out. The present case underwent resection of bilateral lymph nodes from Level I–V as well as Level VI lymph node, which were diagnosed on frozen sections as reactive lymphadenopathy (sinus histiocytosis and/or follicular hyperplasia). However, there were two important findings made in the right sided level II and Level VI cervical lymph nodes. The Level II lymph node on histopathology showed reactive lymphadenopathy along with presence

**Samarth Shukla,
Sourya Acharya¹**

*Departments of Pathology
and ¹Medicine, J. N. Medical
College, DMIMS University,
Wardha, Maharashtra, India*

Received: 08 April, 2017.

Accepted: 06 May, 2017.

Address for correspondence:

*Dr. Samarth Shukla,
Department of Pathology,
J. N. Medical College, DMIMS
University, Sawangi (Meghe),
Wardha, Maharashtra, India.
E-mail: samarth21174@
gmail.com*

Access this article online

Website:
www.ijabmr.org

DOI:
10.4103/ijabmr.IJABMR_36_16

Quick Response Code:



How to cite this article: Shukla S, Acharya S. Cervical lymph nodes: Harbinger of benign inclusions as well as metastatic deposits of thyroid malignancy. *Int J App Basic Med Res* 2017;7:210-2.

This is an open access article distributed under the terms of the Creative Commons Attribution-NonCommercial-ShareAlike 3.0 License, which allows others to remix, tweak, and build upon the work non-commercially, as long as the author is credited and the new creations are licensed under the identical terms.

For reprints contact: reprints@medknow.com

of unremarkable epithelial inclusions (acinar and ductal structures) of salivary gland origin [Figure 1] and Level VI lymph node resected was grossly enlarged with cystic degeneration, on cut section brown fluid oozed out, microscopically on frozen sections, node was found to be positive for metastatic deposits of papillary carcinoma of thyroid [Figure 2]. Further, postoperatively, conventional histopathology report confirmed similar findings of the thyroid mass and lymph nodes.

Discussion

Benign inclusions of epithelial and nonepithelial origins are known to occur within lymph nodes.^[1] Benign inclusions are nothing but ectopic tissue rests in lymph nodes, in which different tissue can be seen. The lymph node inclusions commonly encountered are of epithelial origins which include salivary gland tissue, squamous epithelium, thyroid follicles, Mullerian origin structures, breast tissue, and nevus cells; further inclusions of decidual origin have also been reported. Brooks classified the benign lymph node inclusions into three basic divisions inclusive of epithelial, nevomelanocytic, and decidual origin.^[2] The presence of such inclusions in the lymph node can be oversight as metastatic deposits by histopathology.

While reporting cases with primary malignancy of head-neck areas undergoing radical neck dissection, the surgical pathologist should be aware of following important facts.

Primarily, it is mandatory for the reporting surgical pathologist to consider in mind the occurrence of such ectopic rests and/or benign inclusions in the lymph nodes and to identify the same on microscopy. The benign inclusions of salivary gland, squamous epithelium, and thyroid are most common to occur in lymph nodes of the head-neck area. The salivary gland inclusions are usually found in the higher cervical nodes possibly due to common

embryological origin of the lymph nodes of the head-neck area vis-a-vis salivary glands. Rarely, these benign salivary inclusions may also undergo neoplastic transformation into salivary gland tumors in the lymph node itself such as Warthin's tumor or mixed parotid tumor or mucoepidermoid carcinoma.^[3]

Second, while reporting a radical neck dissection, the surgical pathologists should also be aware that lymph nodes metastasis is one of the most common manifestations in case of papillary carcinoma of thyroid occurring. In one study, about 13% of cases were found to be positive for papillary carcinoma of thyroid with cervical lymph node metastatic deposits; however, 67% cases of papillary carcinoma of thyroid remained localized with no spread to lymph nodes, and surprisingly, 20% of cases had lymph nodes positive for deposits of papillary carcinoma with thyroid gland being clinically normal.^[4] In such cases, thorough sampling of the thyroid should be carried out to rule out microfoci of malignancy in the thyroid gland; however, certain studies have shown total lack of malignancy in thyroid gland despite the presence of metastasis in lymph nodes. Microscopically, cervical lymph nodes may at times contain normal rests of thyroid follicles; such cases can prove to be extremely difficult to evaluate for metastatic deposits; in such cases, the presence of characteristic papillae with psammoma body and other cellular and nuclear features may be helpful to endorse the diagnosis of metastasis. However, in frozen sections, the characteristic ground glass (orphan-Ann eye) nuclei are lacking as was in our case, which makes the entire diagnosis all the more challenging.

Third, there should be a clear understanding that benign epithelial inclusions (thyroid/salivary gland) on histopathology distinctly appear near the capsule of the cervical lymph nodes, nearly always occupying the peripheral rim of the lymph node close to the lymphoid follicles, the benign epithelial inclusions are usually solitary and not spread across the entire lymph node. The lymph node architecture remains largely intact. The benign inclusions on histopathology have a normal appearance showing pseudostratification, normal cell shape (cuboidal/columnar), the nuclear features are retained and unremarkable. Malignant

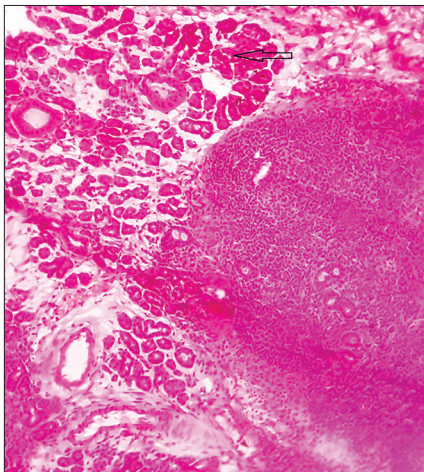


Figure 1: Slide showing lymph node with normal architecture (lymphoid follicles) along with normal salivary gland acinar and ductal structures (depicted by open arrow) (H and E, ×40)

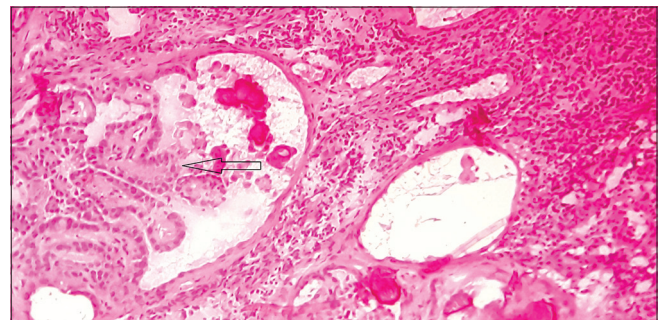


Figure 2: Slide showing cervical lymph node with metastatic deposits of papillary carcinoma of thyroid (depicted by open arrow) (H and E, ×40)

cell deposits are haphazardly spread across the lymph node; the normal nodal architecture is almost always completely effaced, possibly invading the capsule. The cellular features are that of malignancy, with cells showing evidence of pleomorphism, hyperchromatic nuclei with high N:C ratio, abundant mitosis, prominent nucleoli, and necrosis.^[5]

Hence, the surgical pathologist while reporting cases of head-neck-face malignancy undergoing radical neck dissection should keep in mind the above-mentioned key aspects before reporting the case as metastasis as it immensely alters the management protocol and affects the overall prognosis of the patient.

Acknowledgment

We acknowledge the letter to the honorary editor.

Financial support and sponsorship

Nil.

Conflicts of interest

There are no conflicts of interest.

References

1. Longo S. Benign lymph node inclusions. *Hum Pathol* 1976;7:349-54.
2. Brooks JS, LiVolsi VA, Pietra GG. Mesothelial cell inclusions in mediastinal lymph nodes mimicking metastatic carcinoma. *Am J Clin Pathol* 1990;93:741-8.
3. Brown RB, Gaillard RA, Turner JA. The significance of aberrant or heterotopic parotid gland tissue in lymph nodes. *Ann Surg* 1953;138:850-6.
4. Carcangiu ML, Zampi G, Pupi A, Castagnoli A, Rosai J. Papillary carcinoma of the thyroid. A clinicopathologic study of 241 cases treated at the University of Florence, Italy. *Cancer* 1985;55:805-28.
5. Kheir SM, Mann WJ, Wilkerson JA. Glandular inclusions in lymph nodes. The problem of extensive involvement and relationship to salpingitis. *Am J Surg Pathol* 1981;5:353-9.