

## Extremity Necrosis Due to Intrauterine Arterial Ischemia

### Intrauterin Arteriyel İskemiye Bağlı Gelişen Ekstremitte Nekrozu

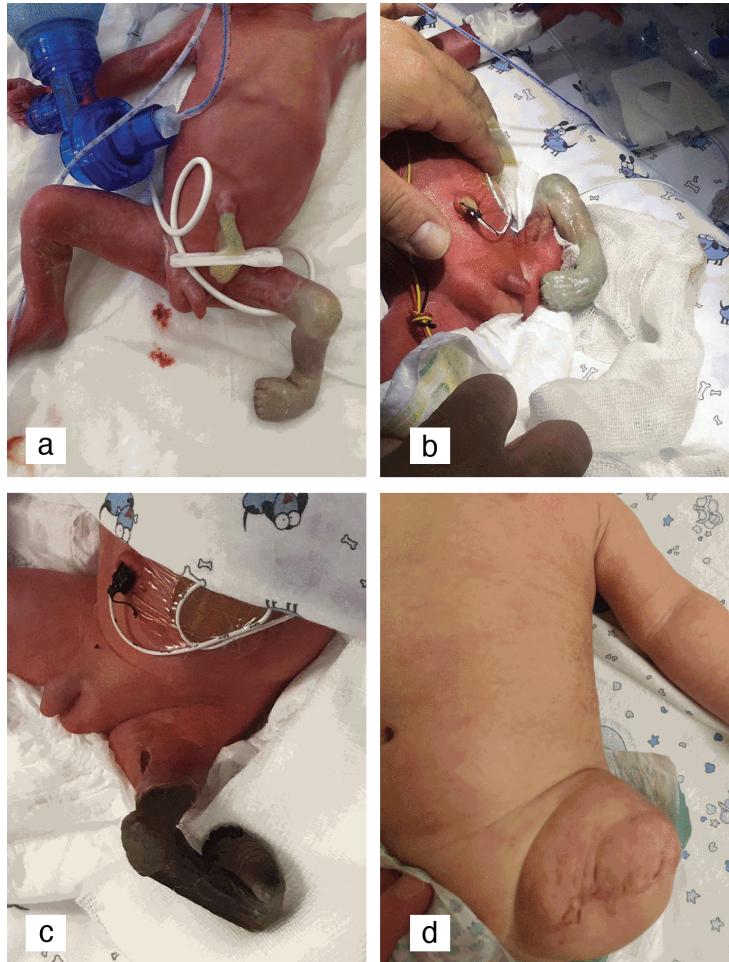
© Serdar Beken<sup>1</sup>, © Kerim Sariyılmaz<sup>2</sup>, © Eda Albayrak<sup>3</sup>, © Arzu Akçay<sup>4</sup>, © Ayşe Korkmaz<sup>1</sup>

<sup>1</sup>Acibadem University Faculty of Medicine, Department of Pediatrics, Neonatology Subdivision, İstanbul, Turkey

<sup>2</sup>Acibadem University Faculty of Medicine, Department of Orthopedics, İstanbul, Turkey

<sup>3</sup>Acibadem University Faculty of Medicine, Department of Pediatrics, İstanbul, Turkey

<sup>4</sup>Acibadem University Faculty of Medicine, Department of Pediatrics, Pediatric Hematology Subdivision, İstanbul, Turkey



**Figure 1.** (a-d) Left lower extremity was rudimentary, pale, shorter than the right, and had a club-foot deformity. The demarcation line became clear on the 5<sup>th</sup> day and amputation was performed under the left hip joint.



A preterm male infant weighing 1230 g was delivered by cesarean section at 32<sup>1/7</sup> gestational weeks. His twin weighed 1300 g and neither required resuscitation. On physical examination, the left lower extremity was rudimentary, pale, shorter than the right, and had a club-foot deformity. Computerized tomographic angiography demonstrated a bluntly filled femoral artery with no distal passage. During follow-up, the demarcation line became clear on the 5<sup>th</sup> day and amputation was performed under the left hip joint (Figure 1).

Laboratory tests including homocysteine, folate, prothrombin time, activated partial thromboplastin time, protein C and S activity, fibrinogen, and antithrombin III activity were within normal limits according to gestational age, except for high D-dimer (4.13 mg/dL). Antiphospholipid and anticardiolipin antibodies were also negative. The patient was found to be homozygous for methylenetetrahydrofolate reductase C677T; thrombosis was not observed in histopathological examination. The patient was successfully discharged from the hospital on the 40<sup>th</sup> day of life.

Arterial ischemia of the limb can be seen after thromboembolic events or vascular interventions [1,2]. Ischemic changes present at birth suggested intrauterine onset causes that might be attributable to occlusive vascular disruption [3]. Diminished blood flow altered normal soft tissue and osseous growth and resulted in ischemia in fetal life, ending with limb loss.

**Keywords:** Newborn, Ischemia, Arterial

**Anahtar Sözcükler:** Yenidoğan, İskemi, Arteriyel

**Informed Consent:** It was received.

### **Authorship Contributions**

Surgical and Medical Practices: S.B., K.S., E.A, A.A., A.K.; Literature Search: S.B., K.S., E.A, A.A., A.K.; Writing: S.B., K.S., A.K.

**Conflict of Interest:** No conflict of interest was declared by the authors.

**Financial Disclosure:** The authors declared that this study received no financial support.

### **References**

1. Wang SK, Lemmon GW, Drucker NA, Motaganahalli RL, Dalsing MC, Gutwein AR, Gray BW, Murphy MP. Results of nonoperative management of acute limb ischemia in infants. *J Vasc Surg* 2018;67:1480-1483.
2. Bekmez S, Beken S, Dinç T, Dursun A, Zenciroğlu A, Dilli D, Okumuş N. Lower extremity amputation in a preterm infant due to MTHFR homozygosity. *Genet Couns* 2014;25:245-249.
3. Turnpenny PD, Stahl S, Bowers D, Bingham P. Peripheral ischemia and gangrene presenting at birth. *Eur J Pediatr* 1992;151:550-554.