

# Recognizing intrapancreatic accessory spleen via EUS: Interobserver variability

Grace E. Kim<sup>1</sup>, John D. Morris<sup>2</sup>, Naveen Anand<sup>3</sup>, Fedele DePalma<sup>4</sup>, Bruce D. Greenwald<sup>2</sup>, Raymond E. Kim<sup>2</sup>, Jeffery Laczek<sup>5</sup>, Woo Jung Lee<sup>6</sup>, Ioannis Papadopoulos<sup>7</sup>, Lance Uradomo<sup>2</sup>, Patrick Young<sup>5</sup>, Peter E. Darwin<sup>2</sup>

<sup>1</sup>Department of Internal Medicine, University of Maryland Medical Center, Baltimore, MD, <sup>2</sup>Division of Gastroenterology and Hepatology, University of Maryland School of Medicine, Baltimore, MD, <sup>3</sup>Division of Gastroenterology and Hepatology, Norwalk Hospital, Norwalk, CT, <sup>4</sup>Delaware Center for Digestive Care, Newark, DE, <sup>5</sup>Department of Gastroenterology, Walter Reed National Military Medical Center and Uniformed Services University, Bethesda, MD, <sup>6</sup>Department of Gastroenterology, Temple University Hospital, Philadelphia, PA, <sup>7</sup>Gastroenterology Service, Madigan Army Medical Center, Tacoma, WA, USA

## ABSTRACT

**Background and Objective:** Accessory spleen (AS) may be encountered as an intrapancreatic lesion on EUS. This can look similar to other pancreatic pathologies and may lead to unnecessary interventions. The goal of this study was to evaluate the accuracy of EUS in distinguishing intrapancreatic AS (IPAS) from other pancreatic lesions. **Materials and Methods:** Twelve sets of endoscopic images of the spleen and various pancreatic lesions confirmed on histology or cytology were gathered. Ten endosonographers were asked to characterize and identify the lesions. The responses were analyzed via Excel and the interobserver agreement was analyzed using Gwet's agreement coefficient statistic via Stata I/C v15. **Results:** In our sample, the interobserver agreement was 0.37 (−1–1; 0–0.2 poor, 0.2–0.4 fair, 0.4–0.6 moderate, 0.6–0.8 substantial, and 0.8–1.0 almost perfect) for determining whether or not the pancreatic lesion is IPAS. The reviewers were able to correctly determine IPAS endosonographically with a sensitivity of 77%, specificity of 74%, and positive and negative predictive values of 50% and 92%, respectively. **Conclusion:** There is a moderate-to-substantial interobserver agreement in describing the sonographic characteristics of the pancreatic lesions, such as the shape, echogenicity compared to spleen, echotexture, and border of the lesions. However, the interobserver agreement is only fair when deciding if the pancreatic lesion is an IPAS. The similar profile of IPAS and pancreatic neuroendocrine tumor could confound the diagnosis of IPAS, thus contributing to the decreased interobserver agreement. This study demonstrates that EUS criteria alone are not accurate for IPAS diagnosis. Fine-needle aspiration (FNA) may be required for a confirmatory diagnosis.

**Key words:** Accessory spleen, EUS, interobserver variability

## INTRODUCTION

Ectopic splenic tissue can arise either from autotransplantation via trauma (“splenosis”) or from a failure of a portion of the spleen to fuse with the main splenic tissue during development (“accessory spleen [AS],”

“splenule,” or “splenunculus”).<sup>[1-3]</sup> The prevalence of AS ranges from 10%–30%,<sup>[2,4]</sup> with the most recent 2017 meta-analysis of over 22,000 patients reporting 14.5% prevalence of AS.<sup>[5]</sup> It can be found anywhere

This is an open access journal, and articles are distributed under the terms of the Creative Commons Attribution-NonCommercial-ShareAlike 4.0 License, which allows others to remix, tweak, and build upon the work non-commercially, as long as appropriate credit is given and the new creations are licensed under the identical terms.

**For reprints contact:** reprints@medknow.com

**How to cite this article:** Kim GE, Morris JD, Anand N, DePalma F, Greenwald BD, Kim RE, *et al.* Recognizing intrapancreatic accessory spleen via EUS: Interobserver variability. *Endosc Ultrasound* 2019;8:392-7.

### Access this article online

Quick Response Code:



Website:

www.eusjournal.com

DOI:

10.4103/eus.eus\_35\_19

### Address for correspondence

Dr. Grace E. Kim, University of Maryland Medical Center, Baltimore, MD, USA. E-mail: Grace.kim@som.umaryland.edu

**Received:** 2019-02-18; **Accepted:** 2019-05-28; **Published online:** 2019-08-13

from the vicinity of its original location to ovaries and testes, the most common location being the splenic hilum (62.1%) followed by the pancreatic tail (5.5%).<sup>[1,2,5-7]</sup> The latter especially can present as a diagnostic dilemma, as it can look similar to other pancreatic pathologies on imaging, such as pancreatic adenocarcinoma and neuroendocrine tumors. Since AS is usually an incidental finding that requires no treatment,<sup>[2,4]</sup> it is important to distinguish intrapancreatic AS (IPAS) from other pancreatic neoplasms to avoid unnecessary interventions.

One of the most common ways to evaluate a pancreas mass is through EUS. Endosonographically, IPAS presents as a round homogenous echotexture similar to the adjacent spleen with increased vascularity, possibly more hypoechoic compared to the surrounding pancreas.<sup>[4,8-11]</sup> These characteristics may also be suspicious for a pancreatic neoplasm, and previous studies have shown that it is still difficult to distinguish benign lesions such as pancreatic cysts from pancreatic malignancies through EUS.<sup>[12-14]</sup>

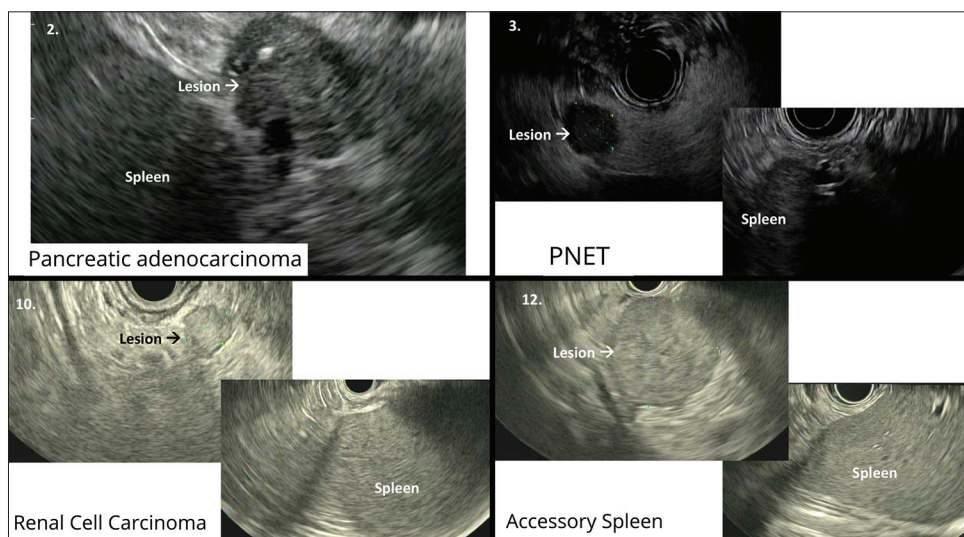
While studies have described the IPAS by EUS criteria, no studies have compared the endosonographic features of IPAS to other pancreatic lesions. Here, we describe the interobserver variability in distinguishing IPAS from other pathology via EUS. This study aims to clearly define the role of EUS and assess its accuracy in distinguishing IPAS from other pancreatic lesions.

## MATERIALS AND METHODS

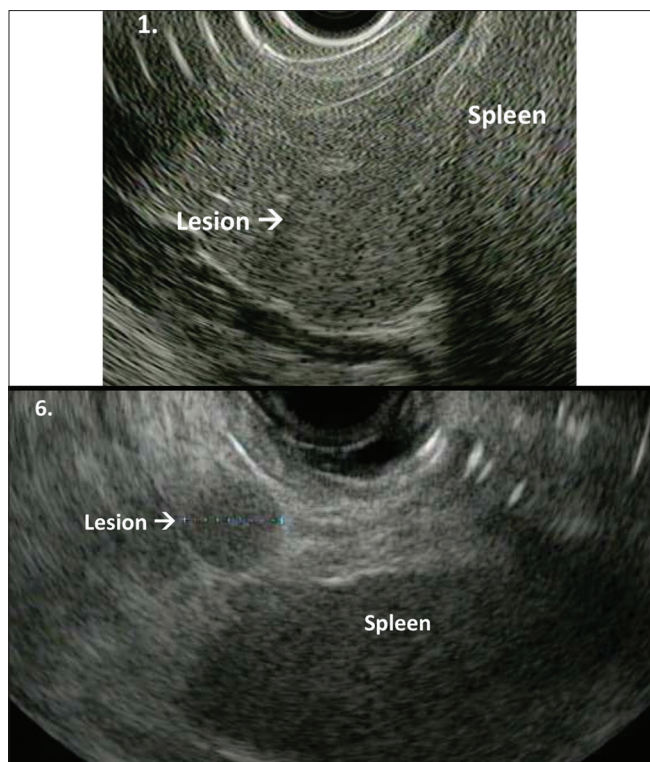
Twelve sets of endoscopic images of the spleen and various pancreatic lesions confirmed on histology

or cytology via EUS-FNA/fine-needle biopsy were gathered from the endoscopic database at the University of Maryland Medical Center. Figures 1 and 2 portray representative pictures of the lesions and spleen. The study was approved by the Institutional Review Board. The images for each set (spleen and lesion) were taken during the same procedure without altering processor gain. The images were deidentified and randomized. Ten gastroenterologists trained in EUS were then given a set of multiple-choice questions that asked to characterize the lesions and identify them as either IPAS or not IPAS. The participants had performed EUS independently from 3 years to over 5 years, with majority in the latter group (7 of 10 endosonographers). With exception to the principal investigator (PI), the rest of the participants were not directly involved in the actual EUS procedures. The PI was blinded from the collection, deidentification, and randomization of the EUS images.

The responses were collected and analyzed via Excel and the statistical measurements such as sensitivity, specificity, positive predictive value (PPV), and negative predictive value (NPV) for diagnosing IPAS were obtained. These values were obtained by evaluating the total number of responses for the IPAS lesions *versus* non-IPAS lesions. For example, as there are three IPAS lesions with ten endosonographers, there are a total of 30 responses. Out of those, the true positives and false negatives were calculated to derive sensitivity. Similarly, as there are nine non-IPAS lesions, a total of 90 responses were generated, from which specificity was calculated.



**Figure 1.** Representative images of endoscopic images of spleen and pancreatic lesions



**Figure 2.** Images of intrapancreatic accessory spleen (study images 1 and 6)

The interobserver agreement was analyzed using Gwet's agreement coefficient (AC) statistic via Stata I/C v15 (StrataCorp, LLC, College Station, TX, USA). Gwet's AC helps to delineate how well individuals agree with each other that is not attributed to chance alone. Gwet's AC ranges from  $-1$  (absolutely no agreement) to  $+1$  (perfect agreement), with  $0.01$ – $0.2$  having poor agreement,  $0.2$ – $0.4$  fair,  $0.4$ – $0.6$  moderate,  $0.6$ – $0.8$  substantial, and  $0.8$ – $0.99$  having almost perfect agreement. Gwet's AC was used rather than conventional kappa to enable weight-based analysis for one of the questions that had a range of answer choices. Specifically, the question asked about the echogenicity of the pancreatic lesion compared to spleen, with answer choices being hypoechoic, isoechoic, mixed, or hyperechoic. Gwet's AC was used to take into account that hypoechoic *versus* hyperechoic would render more of a disagreement than hypoechoic *versus* mixed or isoechoic *versus* hyperechoic, which would render more of a disagreement than hypoechoic *versus* isoechoic, isoechoic *versus* mixed, or mixed *versus* hyperechoic.

## RESULTS

Table 1 depicts the endosonographer's responses to the questionnaire regarding the lesion's shape, echogenicity

of the lesion compared to spleen, echotexture of the lesion, border of the lesion, and whether the lesion was thought to be IPAS. The pancreatic lesions include seven cases of pancreatic neuroendocrine tumor (PNET), one case of pancreatic adenocarcinoma, one case of metastasized renal cell carcinoma, and three cases of IPAS. IPAS was confirmed via surgical resection in one case and FNA in the additional two. Cytology showed a mixed population of mature lymphocytes and occasional vessels. In our sample, Gwet's AC was  $0.75$  (substantial agreement) for describing the shape of the lesion. Gwet's AC weighted for multiple categories of echogenicity of the lesion was  $0.53$  (moderate agreement),  $0.54$  (moderate agreement) for echotexture, and  $0.52$  (moderate agreement) for describing border of the lesion.

Interobserver agreement was  $0.37$  (fair agreement) for determining whether or not the pancreatic lesion is AS. In addition, the reviewers were able to correctly recognize IPAS endosonographically with a sensitivity of  $77\%$ , specificity of  $74\%$ , and positive and negative predictive values of  $50\%$  and  $92\%$ , respectively.

## DISCUSSION

IPAS is a benign congenital finding that may mimic pancreatic neoplasms. With increased use of high-resolution imaging that continuously increases our ability detect discrete lesions, it is important to have IPAS in mind to accurately differentiate benign from malignant lesions. An accurate diagnosis of IPAS may prevent needless surgical intervention.

According to our study, EUS is fair in both ruling in and out AS in the pancreas with  $>70\%$  sensitivity and specificity. NPV is also high, thus if one determines a lesion is not an IPAS, the likelihood of the lesion actually not being IPAS is  $92\%$ . The PPV, however, is  $50\%$ , meaning if one calls the pancreatic lesion an IPAS, it is the same as chance that the lesion is actually an IPAS. This is also in the setting of IPAS being prevalent in  $25\%$  of the lesions in this study. As stated previously, the most recent meta-analysis has shown that the prevalence of overall AS is about  $14.5\%$ ; however, out of the  $14.5\%$  of AS in the general population, IPAS accounts for only  $5.5\%$ , making IPAS an extremely rare finding with an overall prevalence of  $0.79\%$  in the general population. This means that in the real world, the PPV of EUS diagnosing IPAS would be significantly lower than portrayed in this study due

**Table 1. Statistical analyses of the responses from endosonographers**

Image number	Lesion	Shape	Echogenicity*	Echotexture	Border	Accessory spleen (yes/no) - % correct
1	IPAS	90% round/oval	90% isoechoic	90% homogeneous	70% sharp/regular	90% yes
2	Panc AdenoCa	70% lobulated	40% mixed and 40% isoechoic	100% heterogeneous	100% irregular	90% no
3	PNET	90% round/oval	100% hypoechoic	100% homogeneous	90% sharp/regular	90% no
4	PNET	100% round/oval	70% hypoechoic	80% homogeneous	80% sharp/regular	40% no
5	PNET	100% round/oval	40% isoechoic and 40% hyperechoic	70% heterogeneous	90% sharp/regular	80% no
6	IPAS	100% round/oval	90% isoechoic	100% homogeneous	90% sharp/regular	100% yes
7	PNET	90% round/oval	40% isoechoic, 30% mixed and 30% hyperechoic	80% heterogeneous	50% irregular 50% regular	90% no
8	PNET	100% round/oval	50% isoechoic and 50% mixed	100% heterogeneous	100% sharp/regular	50% no
9	PNET	90% round/oval	50% hypoechoic, 30% mixed and 20% isoechoic	100% heterogeneous	90% sharp/regular	80% no
10	RCC met	80% lobulated	50% isoechoic and 40% hyperechoic	50% homogeneous 50% heterogeneous	50% irregular 50% regular	80% no
11	PNET	80% lobulated	50% isoechoic and 40% mixed	80% heterogeneous	80% irregular	70% no
12	IPAS	100% round/oval	90% isoechoic	60% heterogeneous 40% homogeneous	90% sharp/regular	40% yes
Gwet's AC	Overall	0.75	0.53 <sup>†</sup>	0.54	0.52	0.37
Gwet's AC	IPAS	0.93	0.88 <sup>†</sup>	0.62	0.6	0.62
Gwet's AC	PNET	0.81	0.47 <sup>†</sup>	0.6	0.6	0.36

\*Compared to spleen, <sup>†</sup>Weighted for multiple categories. IPAS: Intrapaneatic accessory spleen; PNET: Pancreatic neuroendocrine tumor; RCC: Renal cell carcinoma; AC: Agreement coefficient

to the actual low prevalence of IPAS. This reflects the importance of a follow-up FNA and cytologic as well as histologic confirmatory test to enhance the diagnostic accuracy of intrapancreatic lesions.

Previous interobserver agreement studies for EUS diagnosis have reported a fair-to-good agreement for characterizing various gastroenterological lesions via EUS.<sup>[12,13]</sup> While AS was not evaluated, Gress *et al.* analyzed kappa statistic for different types of submucosal masses and found they varied depending on the lesions, with cystic lesions showing excellent agreement with kappa of 0.8, while leiomyomas had fair agreement with kappa of 0.53.<sup>[12]</sup> Our study provides additional information regarding the role of EUS in characterizing IPAS specifically, and that it does indeed have high interobserver agreement using Gwet's AC. Current literature also acknowledges that the AS has a general set of characteristics found on both sonographic and radiologic imaging. Rodriguez *et al.* showed that an AS tends to be an isoechoic or hypoechoic mass with well-defined, smooth borders on EUS,<sup>[15]</sup> similar to the findings of our study with our endosonographers. On computed tomography (CT), IPAS presents as a hypervascular, well-defined round lesion.<sup>[15]</sup> Nonetheless, studies have also shown that imaging alone is not sufficient to make a confident diagnosis. For example, one recent case series reported

four patients who have undergone both CT, magnetic resonance imaging (MRI), and EUS to assess for IPAS. All modalities of imaging described the IPAS in a similar fashion as above; however, the imaging diagnosis in three out of four cases was neuroendocrine tumor, only to be discovered IPAS after EUS-FNA was performed.<sup>[16]</sup> Similarly, another review reported that out of eleven IPAS cases, only one was diagnosed accurately as IPAS under CT and MRI and the other ten underwent surgical procedure with a misdiagnosis of various pancreatic malignancies.<sup>[16,17]</sup> Although there is a general consensus of both radiologic and sonographic findings of IPAS with homogenous echotexture with regular margins, these have not shown to be specific.<sup>[9,18]</sup> Ahmad *et al.* showed that the interobserver agreement for distinguishing neoplastic *versus* nonneoplastic pancreatic cystic lesions was only fair with kappa of 0.24, indicating there is only a slightly higher than chance that endosonographers can distinguish the two lesions via EUS features alone.<sup>[13]</sup>

Our study supports the current literature that the diagnosis of a benign lesion, specifically IPAS, and distinguishing it from malignant lesions is also only fair with Gwet's AC of 0.37. This further validates why EUS-FNA is essential in diagnosing IPAS to avoid unnecessary surgical intervention. In our study, FNA was performed in two out of three cases of

IPAS. The cytology showed a mixed population of lymphocytes and occasional vessels, consistent with AS. Immunostaining has been reported to aid in this diagnosis;<sup>[19]</sup> CD8 positivity in the endothelial cells of vessels correlated with cytology may aid in a diagnosis of IPAS.

One of the limitations includes the limited number of endosonographers and images which lowers the power of our statistical analysis. Nonetheless, the numbers are comparable to other interobserver studies done regarding EUS. Another limitation is that there were variations to the number of years the endosonographers have independently practiced EUS. Since EUS is a technical skill that gets more refined over time, there could be some variations to the responses depending on the level of expertise. Finally, the Gwet's AC measures the overall agreement of the responses, not necessarily the accuracy. For example, interpreting the echogenicity of the lesion compared to the spleen is especially subjective as some may have answered "hypoechoic" when majority of the lesion is so, as opposed to another who could have chosen "mixed" instead for the same lesion, and neither is incorrect.

We discovered that there is a moderate-to-substantial interobserver agreement in describing the sonographic characteristics of the pancreatic lesions, such as the shape, echogenicity compared to spleen, echotexture, and border of the lesions. However, the interobserver agreement is only fair when deciding if the lesion is an IPAS. One explanation can be seen in the subset analysis of the Gwet's AC for IPAS and PNET. For both IPAS and PNET, most endosonographers have described the lesions as round, homogenous lesion with sharp, regular borders. Their similar profile could confound the diagnosis of IPAS, thus contributing to the decreased inter-observer agreement. Future studies with interobserver variability determination for EUS diagnosis of IPAS compared to that of PNET and other pancreatic lesions with a larger sample can be considered.

Our study demonstrates that EUS criteria alone are not accurate for IPAS diagnosis. While there is a significant agreement on describing the lesion itself, other malignant conditions such as PNET often also have similar sonographic characteristics as IPAS. Consequently, the actual diagnosis of IPAS has only a fair interobserver agreement, which is suboptimal when trying to evaluate further management for patients.

This is also supported by low PPV for diagnosing IPAS, which reflects that it is the same as chance that the lesion would be IPAS when one calls the lesion IPAS. In other words, there is also a 50% probability that this lesion could be a non-IPAS lesion or a malignancy. Given this poor predictive value, it makes sense that endosonographers would hesitate to call a lesion completely benign if this could just as likely be malignant. Furthermore, with such rare prevalence of IPAS at 0.79%, endosonographers may not have had enough exposure to IPAS to distinguish it from other similar-appearing malignant lesions, making it even more difficult to exclude malignancy. There also is a general consensus that EUS is the most difficult endoscopic procedure to learn,<sup>[9,10]</sup> thus it is crucial that the endosonographers have resources available to discern benign from malignant lesions, such as cytological evaluation via EUS-FNA which can better assist in the diagnosis of IPAS *versus* malignant lesions. EUS-FNA is a safe and effective approach with high sensitivity and specificity,<sup>[3,20]</sup> and this should be required for a confirmatory diagnosis of IPAS.

## CONCLUSION

There is only fair interobserver agreement in the diagnosis of IPAS as EUS features overlap with other pancreatic pathology.

### *Financial support and sponsorship*

Nil.

### *Conflicts of interest*

There are no conflicts of interest.

## REFERENCES

1. Saunders TA, Miller TR, Khanafshar E. Intrapaneatic accessory spleen: Utilization of fine needle aspiration for diagnosis of a potential mimic of a pancreatic neoplasm. *J Gastrointest Oncol* 2016;7:S62-5.
2. Guo W, Han W, Liu J, *et al.* Intrapaneatic accessory spleen: A case report and review of the literature. *World J Gastroenterol* 2009;15:1141-3.
3. Conway AB, Cook SM, Samad A, *et al.* Large platelet aggregates in endoscopic ultrasound-guided fine-needle aspiration of the pancreas and peripaneatic region: A clue for the diagnosis of intrapananeatic or accessory spleen. *Diagn Cytopathol* 2013;41:661-72.
4. Marques S, Bispo M, Noia L. Intrapaneatic accessory spleen: A diagnosis not to forge! *Case Rep Gastroenterol* 2016;10:749-54.
5. Vikse J, Sanna B, Henry BM, *et al.* The prevalence and morphometry of an accessory spleen: A meta-analysis and systematic review of 22,487 patients. *Int J Surg* 2017;45:18-28.
6. Radu CC, Muțiu G, Pop O. Accessory spleen. *Rom J Morphol Embryol* 2014;55:1243-6.
7. Halpert B, Gyorkey F. Lesions observed in accessory spleens of 311 patients. *Am J Clin Pathol* 1959;32:165-8.

8. Ardengh JC, Lopes CV, Kemp R, *et al.* Pancreatic splenosis mimicking neuroendocrine tumors: Microhistological diagnosis by endoscopic ultrasound guided fine needle aspiration. *Arq Gastroenterol* 2013;50:10-4.
9. Barawi M, Bekal P, Gress F. Accessory spleen: A potential cause of misdiagnosis at EUS. *Gastrointest Endosc* 2000;52:769-72.
10. Rosch T. Endoscopic ultrasonography artifacts and problems of interpretation. *Gastrointest Endosc* 1996;43:S10-2.
11. Krishna SG, Heif MM, Sharma SG, *et al.* Intrapancreatic accessory spleen: Investigative dilemmas and role of EUS-guided FNA for diagnostic confirmation. *JOP* 2011;12:603-6.
12. Gress F, Schmitt C, Savides T, *et al.* Interobserver agreement for EUS in the evaluation and diagnosis of submucosal masses. *Gastrointest Endosc* 2001;53:71-6.
13. Ahmad NA, Kochman ML, Brensinger C, *et al.* Interobserver agreement among endosonographers for the diagnosis of neoplastic versus non-neoplastic pancreatic cystic lesions. *Gastrointest Endosc* 2003;58:59-64.
14. Topazian M, Enders F, Kimmey M, *et al.* Interobserver agreement for EUS findings in familial pancreatic-cancer kindreds. *Gastrointest Endosc* 2007;66:62-7.
15. Rodriguez E, Netto G, Li QK. Intrapancreatic accessory spleen: A case report and review of literature. *Diagn Cytopathol* 2013;41:466-9.
16. Val-Bernal JF, Martino M, Yllera-Contreras E, *et al.* Intrapancreatic accessory spleen. Report of four cases diagnosed by ultrasound-guided fine-needle aspiration biopsy. *Rom J Morphol Embryol* 2018;59:619-24.
17. Uchiyama S, Chijiwa K, Hiyoshi M, *et al.* Intrapancreatic accessory spleen mimicking endocrine tumor of the pancreas: Case report and review of the literature. *J Gastrointest Surg* 2008;12:1471-3.
18. Schreiner AM, Mansoor A, Faigel DO, *et al.* Intrapancreatic accessory spleen: Mimic of pancreatic endocrine tumor diagnosed by endoscopic ultrasound-guided fine-needle aspiration biopsy. *Diagn Cytopathol* 2008;36:262-5.
19. Lin J, Jing X. Fine-needle aspiration of intrapancreatic accessory spleen, mimic of pancreatic neoplasms. *Arch Pathol Lab Med* 2010;134:1474-8.
20. Bardales RH, Stelow EB, Mallery S, *et al.* Review of endoscopic ultrasound-guided fine-needle aspiration cytology. *Diagn Cytopathol* 2006;34:140-75.