

Percutaneous closure of pseudoaneurysm of the descending thoracic aorta with septal device occlusion technique

Ömer Çelik, Ahmet Anıl Şahin, Mehmet Ertürk
 Department of Cardiology, University of Health Sciences, İstanbul
 Mehmet Akif Ersoy Thoracic and Cardiovascular Surgery Training
 and Research Hospital; İstanbul-Turkey

Introduction

Aortic pseudoaneurysms (APA) typically develop in patients with a history of cardiac or aortic surgery. In addition, any traumatic, inflammatory, or infectious events and spontaneous formation can cause APA (1). The conventional treatment for APA is surgical intervention, which is often associated with high morbidity and mortality, especially in patients with a history of previous cardiac surgery (1, 2). Alternative treatment options include thoracic endovascular aortic repair (TEVAR), coil embolization, thrombin injection, vascular plugs, and off-label use of occluder devices (1-4).

We present the case of a patient who had APA in the descending thoracic aorta at the tenth to eleventh vertebral levels, which is also the region of major visceral arteries, such as the celiac trunk and artery of Adamkiewicz (5). Notably, the distal anterior spinal cord vascular territory was at risk of ischemia in case of damage to the artery of Adamkiewicz during endovascular treatments or surgery. To the best of our knowledge, there is limited information regarding the treatment strategies for APA in the descending aorta and other aortic locations. Herein, we discuss a case of APA treated with transcatheter intervention by using an atrial septal defect (ASD) occluder device.

Case Report

A 65-year-old female with a history of coronary artery bypass grafting; left ventricular ejection fraction of 50%; end-stage renal disease, on hemodialysis; diabetes mellitus, on insulin; and hypertension was admitted to the emergency department with chest pain. During the patient's current hospitalization, a multidetector computed tomography (MDCT) angiography of the thorax and abdomen revealed a large saccular aneurysm in the descending aorta at the tenth to eleventh vertebral levels (the maximum diameter of the aneurysm and APA neck were 43 and 14 mm, respectively) (Fig. 1a-1c). A cardiothoracic surgery evaluation deemed the patient as high risk owing to her comorbidities. Hence, the patient was considered for endovascular therapy. Considering the risk of occlusion of visceral arteries in

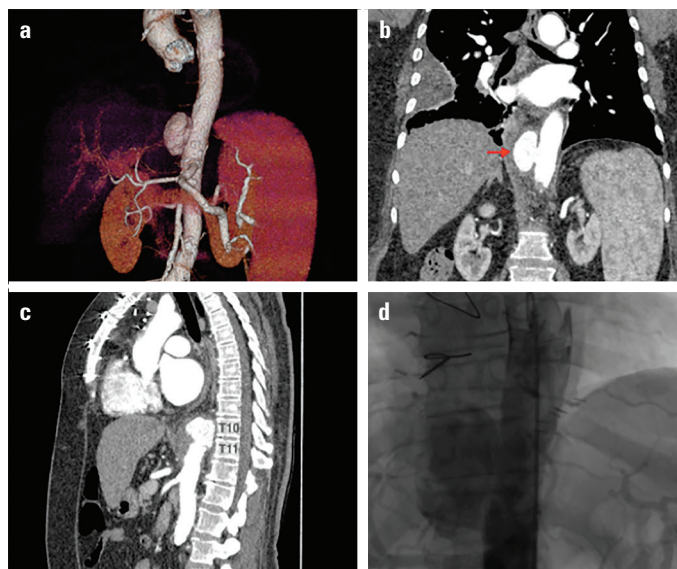


Figure 1. (a) 3-D view of the saccular aneurysm on multidetector computed tomography (MDCT) of the thorax and abdomen. (b) MDCT of the thorax and abdomen revealed a large saccular aneurysm in the descending aorta (red arrow). (c) MDCT of the thorax and abdomen reveals the saccular aneurysm in the descending aorta at the 10th-11th vertebral levels. (d) Aortic angiography showed the saccular aneurysm in the descending aorta during the procedure

the descending aorta during TEVAR, we planned off-label use of occluder device to seal the APA orifice.

The interventional cardiology team performed the endovascular procedure, with the patient under local anesthesia. A cardiothoracic surgeon was on standby. Arterial accesses were obtained in the left and right groin areas, and the preclosure was performed using the ProGlide closure device (Abbott Vascular Devices). A 6-French (Fr) pigtail diagnostic catheter was advanced to the descending aorta for aortic angiography. Aortic angiography revealed the saccular aneurysm in the descending aorta (Fig. 1d). A JR4 diagnostic catheter was used to engage the lumen of APA. Through the JR4 catheter, the APA was wired with an Amplatzer Super Stiff guidewire (Boston Scientific). The catheter was exchanged with a 180-degree 8-Fr AMPLATZER TorqVue Delivery Sheath (AGA Medical, Golden Valley, MN, USA). Once the TorqVue sheath was placed and engaged within the neck of the APA, a 16-mm AGA AMPLATZER® Septal Occluder was advanced into the lesion. The distal disk of the septal occluder device was deployed into the APA sac, the body of the occluder was placed in the neck of the APA, and the proximal disk was deployed on the aortic side (Fig. 2a). Final angiography demonstrated slowing of flow into the pseudoaneurysm, and by the end of the procedure, contrast staining suggested stasis within the cavity (Fig. 2b). Aortic angiography ensured patency of the celiac trunk before deployment of the Amplatzer septal occluder device. The patient recovered uneventfully without any complications. At the 3-month follow-up, MDCT angiography was repeat-

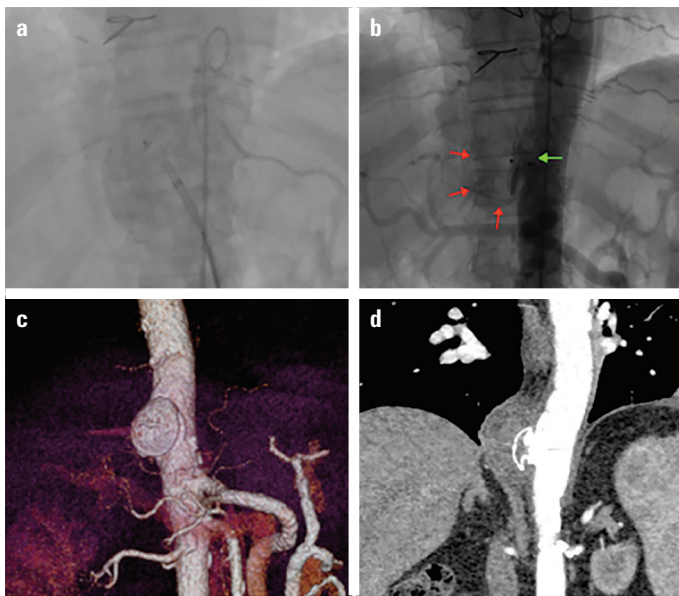


Figure 2. (a) The occluder device is inside the aneurysm, and the distal disk released and ready for positioning. (b) The distal disk of the septal occluder device was deployed into the APA sac (red arrows show the margin of the sac), the body of the occluder was placed in the neck of the APA, and the proximal disk (green arrow) was deployed on the aortic side. (c) 3-D view of occluder device after the procedure on multidetector computed tomography of the thorax and abdomen. (d) Multidetector computed tomography of the thorax and abdomen revealed optimal positioning of the occluder device and no leakage into the sac

ed and demonstrated the device to be in the appropriate position without endoleak (Fig. 2c, 2d) with patent visceral arteries.

Discussion

We present a case of APA that resulted probably from a ruptured penetrating ulcerated plaque in the aorta. The literature has limited knowledge regarding the management of APA. Surgical intervention with direct aortic reconstruction is the conventional treatment strategy in patients with acceptable operative risk (1, 2). Nonetheless, surgery is often associated with high morbidity and mortality, especially in patients with a history of previous surgery. Nevertheless, the lethal nature of APA warrants intervention, and percutaneous interventions have, therefore, garnered tremendous attention in recent years (6). Several percutaneous interventions, such as stent grafting, occluder device, coil, and thrombin injection, can be employed instead of reoperation to repair the APA in high-risk patients (6, 7). We opted for the ASD occluder device after discussion with our heart team members, consisting of cardiovascular surgeons, interventional cardiologists, and a radiologist.

In this case, the practice of off-label use of occluder devices for APA closure provided at least three major advantages over the traditional approach. First, percutaneous device closure has the advantage of avoiding major surgery and general anesthetic. In

addition, transcatheter ASD closure is significantly less invasive than surgery and results in a shorter hospital stay. Second, because of the proximity of APA in the descending thoracic aorta to the major vessels, it is not amenable for exclusion by using a stent-graft because of the risk of fully or partially occluding the ostium of vessels, thereby causing ischemia of the vital organs. Therefore, TEVAR was not an option for our patient because of the proximity of the APA to the visceral arteries, such as the celiac trunk and artery of Adamkiewicz. Third, closure of APA by using coils or thrombin injections, as a standalone therapy, has been reported. However, these are commonly used as adjunctive therapy along with stent-grafts, occluder devices, or vascular plugs. In our case, the size of the APA neck was too large to employ coils and thrombin injections, which could have caused distal embolization.

Quevedo et al. (7) reported a systematic review of 36 cases in which Amplatzer septal occluder devices or vascular plugs were employed, resulting in 75% successful deployment with minor residual flow post-deployment. Hussain et al. (8) applied the Amplatzer device successfully to treat six patients with APA. Two patients had a deployment failure during intervention necessitating surgery during their short-term follow-up. Lyen et al. (6) reviewed 34 cases and reported device migration in 12% (4/34) requiring surgery. Overall, 18% (6/34) of cases had an ongoing leak into the APA with two cases requiring surgery for the ongoing leak. Seven patients underwent combined occlusion and embolization technique, and one patient (14.3%) died from complications related to APA. Five patients had only the occlusion device, and three (60%) died of complications related to their APA. The related reports and reviews reveal that off-label use of septal occluder devices might be beneficial in high-risk patients and facilitate the planning of effective treatment strategies, albeit with potential complications.

Conclusion

This case illustrates that invasive treatment for APA might facilitate safe and early treatment of APA in high-risk patients, even though no known long-term follow-up data are available yet to compare it with open techniques. Nevertheless, the practice of off-label use of occluder devices for APA closure has been restricted to patients with a history of multiple cardiac surgeries and considered unsuitable for other thoracotomy procedures.

Informed consent: Written informed consent was obtained from the patient.

References

- Hussain J, Strumpf R, Ghandforoush A, Wheatley G, Sutherland J. Transcatheter closure of recurrent aortic pseudoaneurysm previously treated by Amplatzer occluder device. *J Vasc Surg* 2010; 52: 196-8.

2. D'Attellis N, Diemont FF, Julia PL, Cardon C, Fabiani JN. Management of pseudoaneurysm of the ascending aorta performed under circulatory arrest by port-access. *Ann Thorac Surg* 2001; 71: 1010-1.
3. Barbetakis N, Xenikakis T, Efstathiou A, Fessatidis I. Percutaneous coil embolisation of a false aortic aneurysm following coronary surgery and mediastinitis. *Hellenic J Cardiol* 2007; 48: 246-8.
4. Lin PH, Bush RL, Tong FC, Chaikof E, Martin LG, Lumsden AB. Intra-arterial thrombin injection of an ascending aortic pseudoaneurysm complicated by transient ischemic attack and rescued with systemic abciximab. *J Vasc Surg* 2001; 34: 939-42.
5. Yoshioka K, Niinuma H, Ehara S, Nakajima T, Nakamura M, Kawazoe K. MR angiography and CT angiography of the artery of Adamkiewicz: state of the art. *Radiographics* 2006; 26 Suppl 1: S63-73.
6. Lyen SM, Rodrigues JC, Manghat NE, Hamilton MC, Turner M. Endovascular closure of thoracic aortic pseudoaneurysms: A combined device occlusion and coil embolization technique in patients unsuitable for surgery or stenting. *Catheter Cardiovasc Interv* 2016; 88: 1155-69.
7. Quevedo HC, Santiago-Trinidad R, Castellanos J, Atianzar K, Anwar A, Abi Rafeh N. Systematic review of interventions to repair ascending aortic pseudoaneurysms. *Ochsner J* 2014; 14: 576-85.
8. Hussain J, Strumpf R, Wheatley G, Diethrich E. Percutaneous closure of aortic pseudoaneurysm by Amplatzer occluder device-case series of six patients. *Catheter Cardiovasc Interv* 2009; 73: 521-9.

Address for Correspondence: Dr. Ahmet Anıl Şahin,
Sağlık Bilimleri Üniversitesi,
İstanbul Mehmet Akif Ersoy Göğüs,
Kalp ve Damar Cerrahisi Eğitim ve Araştırma Hastanesi,
Kardiyoloji Kliniği,
İstanbul- Türkiye

Phone: +90 553 222 76 27

E-mail: aanilsahin@hotmail.com

©Copyright 2020 by Turkish Society of Cardiology - Available online

at www.anatoljcardiol.com

DOI:10.14744/AnatolJCardiol.2020.59251

