



Since January 2020 Elsevier has created a COVID-19 resource centre with free information in English and Mandarin on the novel coronavirus COVID-19. The COVID-19 resource centre is hosted on Elsevier Connect, the company's public news and information website.

Elsevier hereby grants permission to make all its COVID-19-related research that is available on the COVID-19 resource centre - including this research content - immediately available in PubMed Central and other publicly funded repositories, such as the WHO COVID database with rights for unrestricted research re-use and analyses in any form or by any means with acknowledgement of the original source. These permissions are granted for free by Elsevier for as long as the COVID-19 resource centre remains active.



Contents lists available at ScienceDirect

# Japanese Dental Science Review

journal homepage: [www.elsevier.com/locate/jdsr](http://www.elsevier.com/locate/jdsr)

## Review Article

# Current perspectives on dental adhesion: (2) Concepts for operatively managing carious lesions extending into dentine using bioactive and adhesive direct restorative materials



Richard M. Foxton\*

Centre for Dental Education, Faculty of Dentistry, Oral and Craniofacial Sciences, King's College London, United Kingdom

## ARTICLE INFO

### Article history:

Received 19 June 2020

Accepted 24 August 2020

### Keywords:

Caries-affected dentine

Acid-base resistant zone

Colour

## ABSTRACT

This article reviews the current concepts for operatively managing carious lesions extending into dentine with minimal removal of tooth structure and restoring with dentine adhesives and direct composite resin. It looks sequentially at the operative steps involved including remineralisation with bioactive cements, bonding to caries-affected dentine including smear-layer modification using HOCl, creation of an acid-base resistance zone, steps to optimise the performance of all-in-one adhesives, and incremental placement of direct composite resin to improve bond strengths to cavity floor dentine. It explores how understanding the phenomenon of colour-shifting at the composite resin-enamel/dentine restoration borders can help in creating near “invisible” restoration margins through a “chameleon” effect. With the increased risks of transmission of Covid-19 when aerosol generating procedures are carried out in Dentistry, following a minimally invasive approach to managing dental caries should be given serious consideration.

© 2020 The Author. Published by Elsevier Ltd on behalf of The Japanese Association for Dental Science. This is an open access article under the CC BY-NC-ND license (<http://creativecommons.org/licenses/by-nc-nd/4.0/>).

## 1. Introduction

This article reviews the current concepts for operatively managing and restoring carious lesions extending over one-third into dentine with adhesively-retained direct composite resin. The following topics will be discussed: operative management of caries extending into dentine, remineralisation with bioactive cements, bonding to caries-affected dentine including smear-layer modification using HOCl, creation of an acid-base resistance zone, steps to optimise the performance of all-in-one adhesives and incremental placement of direct composite resin to improve bond strengths to cavity floor dentine. An understanding of how the phenomenon of colour-shifting at the composite resin-enamel/dentine restoration borders can help in creating near “invisible” restoration margins through a “chameleon” effect will also be addressed. With the increased risks of transmission of Covid-19 when aerosol generating procedures are carried out in Dentistry, following a minimally invasive approach to managing dental caries should be given seri-

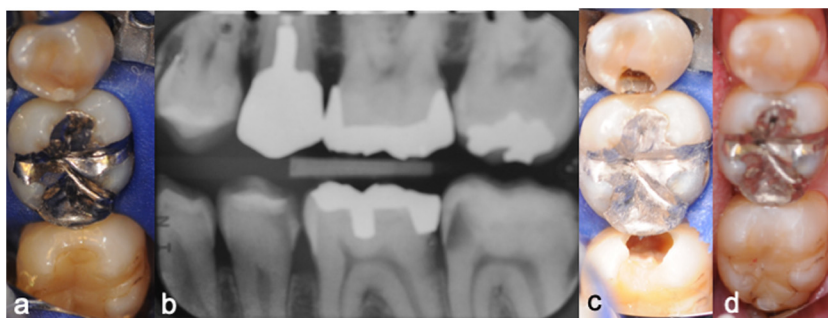
ous consideration with a heavy emphasis on prevention of caries by providing patients with appropriate dietary advice and oral hygiene instruction [1]. Should operative treatment be required, then reducing the amount of tooth structure that is removed, carrying out appropriate caries removal and use of a rubber dam will help lessen the quantity of aerosols generated, which might contain microorganisms that could be inhaled by dental staff involved with treatment [1]. Advances have taken place in understanding how dentine can be remineralised, bonding to caries-affected dentine can be achieved and how the strength and acid resistance of the adhesive interface created by dental adhesives can be improved. These factors can aid the clinical success of adhesive direct composite restorations, which when combined with the adoption of a minimally invasive approach now allow us to minimise the intervention required and these will be discussed in more detail.

## 2. Operative caries management

Carious lesions extending beyond one third from the enamel-dentine junction (EDJ) into dentine will require operative management [2]. Operative management should aim to preserve as much tooth structure as possible. This can be achieved by carefully accessing the dentine caries with as little removal of tooth structure as possible and understanding the pathology of the carious

\* Correspondence to: Senior Clinical Lecturer/Honorary Consultant, Restorative Dentistry, Room 100, Floor 21, Guy's Tower, Guy's Hospital, Great Maze Pond, London, SE1-9RT, United Kingdom.

E-mail address: [richard.foxton@kcl.ac.uk](mailto:richard.foxton@kcl.ac.uk)



**Fig. 1.** a. Intra-oral photograph showing rubber dam isolation of 45, 46 and 47. Distal caries is present in 45 and mesial caries in 47. b. Bitewing radiograph showing distal caries in 45, distal caries in 46 and mesial caries in 47. c. Intra-oral photograph showing small access cavities cut in the 45 and 47 with peripheral soft caries excavated adjacent to EDJ. Deeper caries is left behind to minimise the risk of pulp exposure. d. The prepared cavities in both the 45 and 47 have been restored using Clearfil SE Bond 2 adhesive (Kuraray Noritake Dental Inc., Japan) and Estelite Posterior composite resin (Tokuyama Dental Corp., Japan).

process together with the published research on the clinical management. Fusayama's classification of carious dentine into the two zones of "caries-infected" dentine and "caries-affected" dentine has provided important guidance on how the histology of the dentine carious lesion can be related to the clinical situation [3]. Fusayama advocated removing caries-infected dentine, which is substantially demineralised and is physiologically un-remineralisable [3]. This dentine consists of irreversibly denatured collagen fibrils and to leave behind the caries-affected dentine, which in contrast is minimally infected with bacteria, partially demineralised and physiologically remineralisable [3].

It is not easy clinically to differentiate between caries-infected dentine and caries-affected dentine and it may not matter so much if the floor of the cavity is still caries-infected dentine rather than caries-affected dentine if a seal can be created after restoration. There is no solid evidence that it is necessary to remove all the caries-infected dentine and if present, even all the soft, wet carious dentine. If there is enamel present at the cavity margins then the deeper caries can be "sealed" after removal of superficial soft caries if an adhesive restorative material is used [4]. The classic study by Mertz-Fairhurst's group adhesively bonded composite and amalgam over soft carious dentine that was present even adjacent to the EDJ and although only 50% of the patients presented at recall 10 years later, this approach led to a similar outcome as conventional caries removal [5]. It is accepted that removal of "softened" carious dentine using hand excavators, initially adjacent to the enamel-dentine junction, keeping away from the deeper caries, will lessen the likelihood of a pulp exposure [6]. However, it is important to understand that it is not necessary for the cavity to be completely caries-free as this will result in sound dentine being present on the cavity floor, which will lead to the exposure of dentinal tubules that will cause pain for the patient.

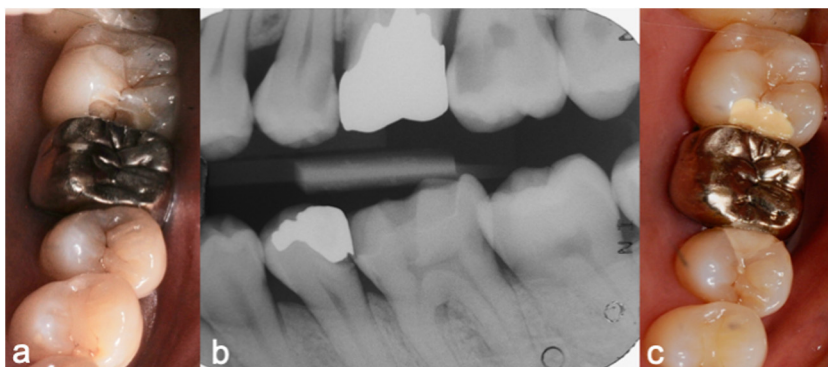
What has been sometimes forgotten is that Fusayama as well as advocating that complete caries removal is not necessary, also introduced the concept of "painless dentistry" [7]. He advocated leaving the cavity floor consisting of caries-affected dentine, where the tubules are filled with whitlockite crystals formed by reprecipitation of calcium and phosphate ions lost during the carious process that can re-mineralise and forms a so-called "barrier" to the underlying pulp. He wrote in 1991, "although dentists have heretofore believed that dental caries treatment must surely be accompanied by pain, our new concept of dental caries pathology reveals that the pain is caused by removing tissue that should not be removed", thereby introducing the concept of "painless" dentistry [7]. Removing "soft" caries carefully with an excavator that will be caries-infected dentine can be often accomplished without causing pain to the patient and this is all the operative intervention that is required on the carious dentine. This will also minimise the risk of post-operative sensitivity. It is not recommended that caries removal should be

taken any further from a biological point of view [6]. We should be thinking biologically and aiming to preserve pulp vitality at all costs (Fig. 1).

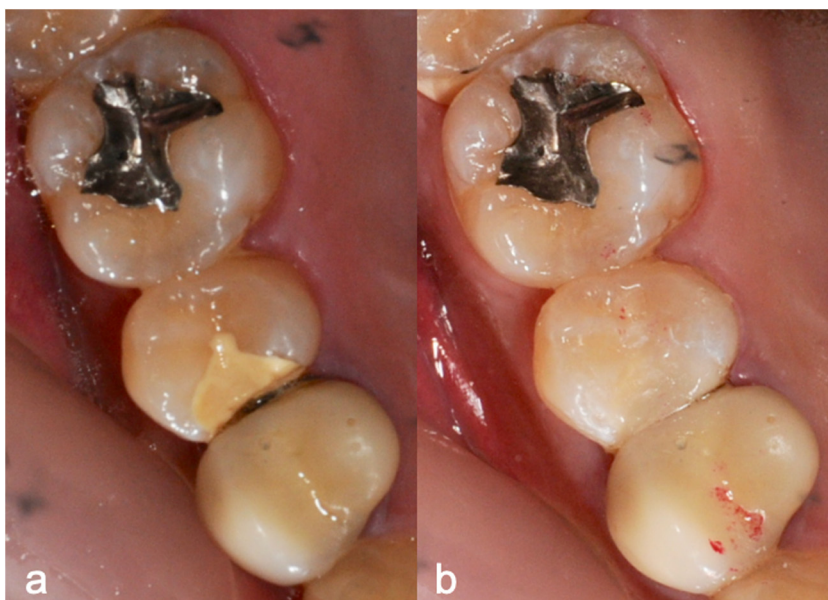
With the increased risks of virus diffusion when carrying out aerosol generating procedures on patients who may have been infected with Covid-19 [1], access cavities for caries ought to be kept as small as possible if using an air turbine, followed by careful excavation of only superficial, soft, wet, "infected" carious dentine. It could be argued that a clinician managing caries for the first time on a tooth carries a great responsibility to preserve as much healthy tooth tissue as possible. Opting if possible, for a restorative material such as an adhesive direct composite resin restoration in the first instance after accessing and managing the caries. This often only requires minor subsequent cavity modifications and there have been several papers published showing its long-term clinical success over a period of 25 years or more [8,9]. On the other-hand, if instead an indirect restoration is chosen, tooth tissue will need to be removed to create a cavity with diverging cavity walls, which is likely to give rise to additional loss of peripheral enamel and most likely sound dentine. Cutting of sound dentine exposes dentinal tubules causing the patient pain and must be sealed to prevent post-operative sensitivity. This could create an additional clinical problem that might otherwise be avoided. This approach therefore does not make sense from a biological point of view where only "diseased" tooth tissue is removed and as much healthy tooth tissue as possible is retained thus ensuring the tooth has the best possible chance of long-term survival.

### 3. Remineralisation of cavity-floor carious dentine

Caries that has extended into dentine most likely leads to the pulp becoming "stressed". In 1982, Abou-Rass introduced the "stressed" pulp as a clinical concept in which the pulp should be considered to be "stressed" if it has been subjected to repeated challenges to pathological changes such as caries [10]. Nowadays, if we believe this to be the case, it would make sense to consider placing a "bioactive" restorative material that may promote repair and remineralisation of the demineralised carious dentine left on the cavity floor, such as a glass-ionomer based or calcium-silicate based material [11]. The setting reaction of glass-ionomer based materials and calcium-silicate materials are unlikely to stress the pulp further and the calcium-silicate cement, Biodentine™ (Septodont, Saint-Maur-des-Fossé, France) in particular may have a therapeutic effect of "pulp-healing" [12] (Fig. 2). Biodentine™ (Septodont, Saint-Maur-des-Fossé, France) or glass-ionomer provisional restorations should be cut back and layered with direct composite resin to provide a durable occluding surface [13]. This could be as little as 1.5–2.0 mm, which could be pain-free for the patient if sound



**Fig. 2.** a. Intra-oral photograph showing 24, 25, 26 and 27. 25 has distal caries and 27 has mesial caries. b. Bitewing radiograph showing distal caries in 25, mesial caries in 27, distal caries in 36 and distal caries in 35. c. Intra-oral photograph showing provisional restorations, which have been placed in 25 and 27. After small access cavities were cut and peripheral soft caries excavated, 25 was provisionally restored with glass ionomer cement (Fuji IX, GC Corporation, Japan) and 27 with Biodentine™ (Septodont, France).



**Fig. 3.** a. Intra-oral photograph showing 14, 15 and 16. The tooth 15 has been provisionally restored with Biodentine™ (Septodont, France) after managing caries, which was present mesially. b. The Biodentine™ provisional restoration in 15 was cut back by 1.5 mm and restored with direct composite resin using Clearfil SE Bond 2 (Kuraray Noritake Dental Inc., Japan) and Estelite Posterior composite resin (Tokuyama Dental Corp., Japan).

dentine is not cut. The cut-back restorative material will act as a “dentine” replacement and the overlying direct composite resin material as the enamel replacement (Fig. 3).

Clinically, a decision has to be made therefore after managing a tooth with deep caries into dentine. The options are to proceed straightaway with a directly bonded resin composite restoration, which will create a “seal” and a durable, aesthetic restoration, or to adopt a two visit technique in which an attempt is made to manage the remaining carious dentine and potentially “stressed” pulp biologically.

#### 4. Adhesion to caries-affected dentine

Partial caries removal and cavity preparation using excavators and burs will leave a smear layer and caries-affected dentine as the substrates at the base of the cavity, which should be managed appropriately prior to applying a dentine adhesive. Nakajima's group have reported that caries-affected dentine compared to sound dentine is softer even though the dentinal tubules are occluded with mineral deposits [14]. Moreover, Nakajima described the smear layer created on caries-affected dentine as being thicker and more enriched with organic components than the

smear layer created on sound dentine because the caries-affected dentine is partially demineralised compared to normal dentine [14]. The remaining caries-affected dentine on the cavity floor is a challenging substrate to bond to. In the era of evidence-based dentistry it is poignant to appreciate that the majority of research on dentine adhesives has been carried out on extracted molars or bovine teeth with sound dentine. However, research on bonding to caries-affected dentine is limited. The clinician has various choices with regards to dentine adhesives and there are two broad groups: etch and rinse adhesives and self-etching adhesives.

With regards to the “etch-and-rinse” adhesives, the phosphoric acid etchant will dissolve the smear layer and demineralise the surface dentine. It can be difficult for the resin monomers to infiltrate to the full depth of demineralised dentine and when a “wet bonding” technique is used, water will also compete with the resin monomers to penetrate to the full depth of demineralisation [14]. The occluded dentinal tubules in the caries affected dentine cannot be completely dissolved by phosphoric acid and this makes them acid resistant [14]. However, because the caries-affected dentine is less mineralised compared to normal dentine, a deeper zone of demineralised dentine is created after phosphoric acid etching, which will result in a thicker hybrid layer after resin

infiltration [15]. On the other hand, beneath the hybrid zone there will be a porous region of dentine that has been created because of the greater depth of demineralisation and the mineral deposits present in the tubules [16]. The net result of this is a reduction in resin-dentin bond strengths to caries-affected dentine compared to sound dentine. This porous zone of weakness below the hybrid layer can be potentially strengthened by the addition of chemical cross linkers, which mechanically strengthen this incompletely resin-infiltrated zone [14].

Self-etching adhesives, in particular the two-step self-etching systems, offer the advantage of not requiring dentine to be etched by phosphoric acid and the acidic self-etching primer will dissolve the smear layer and demineralise a thin zone of underlying dentine. The zone of demineralisation is not as deep in normal dentine as that created by phosphoric acid, which makes it easier for the subsequently applied bonding resin to infiltrate the demineralised dentine resulting in a thin but “high quality” hybrid layer [14]. However, in caries-affected dentine, the hybrid layer created by a self-etching adhesive is thicker, though not as thick when an “etch and rinse” adhesive is used, and a porous zone has been observed beneath the hybrid layer created by a self-etching adhesive [14]. A deeper zone of demineralisation is created in caries-affected dentine and resin infiltration is also hampered by the thicker smear layer, which the mildly acidic self-etching primer is not able to fully dissolve. This results in the self-etching adhesives having lower bond strengths to caries-affected dentine compared to sound dentine [14].

In order to improve the bonding of self-etching adhesives to caries-affected dentine, researchers have looked at modifying the thicker smear layer present on caries-affected dentine [14]. Initially, sodium hypochlorite solution was investigated as this solution can dissolve organic substances and when applied to smear-layer covered caries-affected dentine at a concentration of 6% for 15 s, it was shown that the smear layer was thinned down and dissolved away resulting in significant improvements of the bond strengths of one and two-step self-etching adhesives [17]. Further research by the same research group has investigated the application of a mild acidic solution of HOCl (Comfosy, HaccpperAdvantec Corp., Tokyo, Japan), which has antimicrobial, deproteinising and low cytotoxicity properties on caries-affected dentine and observed that a better quality of hybrid layer was created as well as more stable bond strengths [18].

## 5. Acid-base resistant zone- creation of “super dentine”

It has been mentioned earlier that phosphoric acid etching of dentine may result in the phenomenon of “over-etched” dentine, whereby the resin is unable to fully penetrate to the full depth of demineralisation resulting in a zone of potential weakness beneath the hybrid layer [14]. This zone will be demineralised and not be fully infiltrated with resin and could influence the longevity of a composite resin restoration particularly if placed in a tooth subjected to high occlusal stress. On the otherhand, self-etching adhesive systems do not require prior phosphoric acid etching of dentine and therefore, “aggressive” etching of dentine is avoided [19]. Nikaido previously discovered an “acid-base resistant” zone beneath the hybrid layer, when bonded dentine-composite resin discs were subjected to an artificial secondary caries attack [19]. His research group investigated a two-step, self-etching adhesive, Clearfil SE Bond (Kuraray Noritake Dental Inc., Japan), and observed that the hybrid layer was approximately 1  $\mu\text{m}$  thick after argon ion etching in sound dentine and was slightly thicker in caries-affected dentine [20]. Beneath the hybrid layer of this adhesive, an acid-base resistant zone was observed in both sound and caries-affected dentine bonded specimens, which was observed to be 1  $\mu\text{m}$  thick in

the sound dentine and 1.5  $\mu\text{m}$  thick in the caries-affected dentine [20]. This zone was not observed to be present for adhesive systems that required prior etching with phosphoric acid. It was reasoned that this was because phosphoric acid aggressively etched the dentine and created a zone of demineralisation that was too deep for resin to fully infiltrate [20]. This is potentially significant in that secondary caries will occur at the margins of restorations between the dentine and resin restoration and therefore the presence of an acid-base resistant zone may help prevent secondary caries around a restoration.

It is relevant at this point to mention that in 1985, Nakabayashi described the resin infiltration of tooth structure as follows; “the resin reinforced dentine and enamel is a hybrid of natural tissue and artificial material and is valuable in the prevention of secondary caries after restoration” [21]. And so, even though it was thirty-five years ago when prevention of secondary caries by hybrid layer formation was first proposed, it is interesting that discussion on the effectiveness of the hybrid layer to prevent secondary caries is sometimes omitted in the scientific discussions when adhesive performance is discussed.


Nikaido described the acid-base resistant zone as a combination of dentine and the adjacent hybrid layer which, because it is effectively reinforced, has suggested this region of the adhesive interface should be called “super dentine”, which possesses an ability to prevent primary and secondary caries [22]. This is because it is superior to sound dentine mechanically, chemically and biologically. Nikaido’s proposal is arguably, a further development and extrapolation of the concept of that the hybrid layer can prevent secondary caries formation, as was first described by Nakabayashi in 1985 [21,22].

Having now discussed how we could provide “painless” dentistry by careful removal of soft, caries-infected dentine, seal the cavity and prevent caries progression by adhesive enamel bonding and how the hybrid layer and an acid-base resistant zone offer the ability to prevent primary and secondary caries, it is clear that carefully applied adhesive direct composite resin restorations can offer the patient additional benefits by their ability to fill minimally prepared cavities, offer aesthetically pleasing results and good long-term durability [8]. While the words “minimally invasive dentistry” are mentioned nowadays as if it was a new treatment modality, its origins are surely in the mid 1980s with the work of Fusayama and Nakabayashi who suggested that caries can be prevented by hybrid layer formation at the adhesive interface of direct composite resin restorations. The remainder of this article will discuss some key aspects of direct composite resin placement to obtain good adhesion and colour matching.

## 6. Options for improving adhesive performance at the cavity floor and margins

There are multiple choices for the clinician when selecting which direct composite resin materials should be used as a restorative material. An initial question might be whether a thin layer of a “flowable” composite resin should be placed initially in the cavity? As with many clinical techniques it is often difficult to provide a definitive answer. The rationale of placing a low-viscosity or flowable composite resin as an initial thin layer after curing of the adhesive is that this may dissipate contraction stresses that are created when the composite resin is light-cured by the creating of a stress-absorbing layer that helps preserve the integrity of the bonded adhesive interface [23].

In 2003, Reis and colleagues looked at the effect of filling techniques and a low-viscosity composite liner on bond strength to class II cavities prepared in extracted human third-molar teeth and found that bond strengths were not improved when a low-viscosity



**Fig. 4.** a. Laser scanning confocal micrograph of a sectioned resin-dentine adhesive interface from an *in-vitro* cervical restoration in human extracted premolar (Adper Prompt L-Pop (3 M, USA) and Filtek Supreme, (3 M, USA)). The adhesive was labelled with rhodamine B fluorescent dye. The black arrow indicates water droplets at the adhesive interface between the adhesive and composite resin. b. Laser scanning confocal micrograph of sectioned resin-dentine adhesive interface from an *in-vitro* cervical restoration in a human extracted premolar (Adper Prompt L-Pop and Filtek Supreme, 3 M, USA). The adhesive was labelled with rhodamine B fluorescent dye. The black arrow indicates cracking at the adhesive interface (x100 magnification).

composite resin was used but an incremental filling technique improved bond strengths [24].

Research was then focussed on whether a particular type of adhesive might benefit from a subsequent application of a thin layer of flowable composite resin and work by De Goes' group tried to answer this question by looking at 4 adhesives representing the four classes of adhesives at that time [25]. The occlusal surfaces of extracted third molars were ground to expose dentine and were treated with one of four adhesives: 3-Step etch-and-rinse (Scotch-Bond Multi-Purpose, 3 M, USA); 2-step etch-and-rinse (SingleBond, 3 M, USA); All-in-one self-etching adhesive (Adper Prompt, 3 M, USA); 2-step self-etching adhesive (Clearfil SE Bond, Kuraray Noritake Dental Inc., Japan) [25]. Their results showed that application of an intermediate flowable composite layer improved the bond strength of all four adhesives and this was significant for Clearfil SE Bond (Kuraray Noritake Dental Inc., Japan) [25].

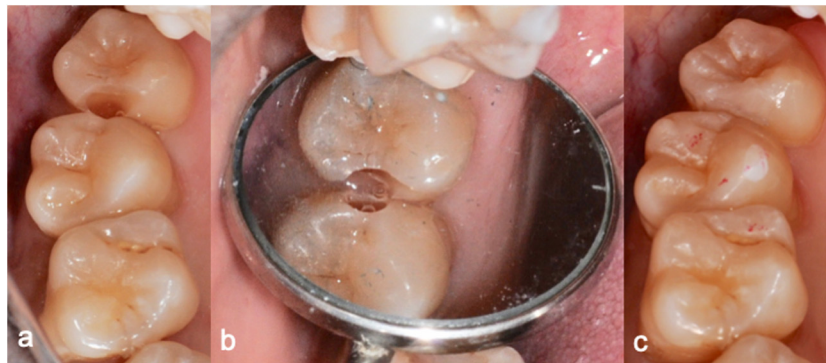Early all-in-one adhesives such as Adper PromptL-Pop (3 M, USA) contained a functional monomer that dissociated into a hydrolytically unstable monomer because of the presence of water at a concentration of 30%–50%. This allowed fluid penetration through the adhesive and led to the hybrid layer being susceptible to cracking after polymerisation of the overlying composite resin [26,27] (Fig. 4). The simplicity of all-in-one adhesives led many researchers to look at ways of improving the durability of the adhesive bond and the mechanical properties of the adhesive interface to withstand the contraction stresses of the overlying composite resin as it polymerised and manufacturers to look at new compositions. The expiry of the patent in 2003 for MDP, which was held by Kuraray Noritake Dental Inc. Japan, has led to several manufacturers, developing new adhesives that contain MDP as the functional adhesive monomer and their terminology has also evolved to “universal adhesives” [28]. MDP has been shown to exhibit ionic bonding to hydroxyapatite more effectively than other adhesive monomers such as 4-MET through the creation of an MDP-Ca salt deposition and nanolayering [29].

Applying the all-in-one adhesive as a double application before curing has been investigated using four, one-step self-etching adhesives (iBond SE, Kulzer GmbH, Germany; Clearfil S<sup>3</sup> Bond, (Kuraray Noritake Dental Inc., Japan; XenoV, Dentsply Sirona, USA; and Scotchbond Universal, 3 M, USA) with extracted human third molars as the bonding substrate under different storage conditions [30]. It was found that iBond SE, Clearfil S<sup>3</sup> Bond and XenoV exhibited significantly higher bond strengths when they were applied as a double layer before light-curing [30].

Another adhesive application technique, “scrubbing” the dentin surface with a micro-sponge, has been suggested for certain one-step self-etching adhesives to increase the bond strength [31]. The effect of scrubbing dentine during application was investigated using two, one-step self-etching adhesives on extracted third molar teeth (SE One, Kuraray Noritake Dental Inc., Japan; and Scotchbond Universal, 3 M, USA) and it was found that scrubbing improved etching ability and significantly improved the bond strength of Scotchbond Universal (3 M, USA) [31].

One more technique proposed to improve the bond strength of universal adhesives is to apply a subsequent coating of a thin layer of a hydrophobic resin, thereby converting the adhesive strategy to a two-step self-etching one [32]. Extracted third molar teeth were used and when a layer of Heliobond (IvoclarVivadent AG, Liechtenstein) was applied to three universal adhesives (All-Bond Universal, Bisco, USA; G-Bond Plus, GC Corporation, Japan; and ScotchBond Universal, 3 M, USA) in their self-etching mode, adhesive performance was improved [32].

What this means for clinical practice is that while the above-mentioned studies using universal adhesives all used extracted third molars, their results do indicate that if a universal adhesive has been chosen by the clinician, then thought should be given not only to its application technique, be it by “scrubbing” or as a double-coat, but whether consideration should be given to applying an additional thin layer of hydrophobic resin before applying the composite resin or a flowable composite resin material.



**Fig. 5.** a. Intra-oral photograph showing small cavities, which have been cut in the distal aspect of 17 and mesial aspect of 18. b. The peripheral soft caries has been removed from 17 and 18. c. The cavities in 17 and 18 have both been restored using Clearfil SE Bond 2 (Kuraray Noritake Dental Inc., Japan) and Estelite Posterior composite resin (Tokuyama Dental Corp., Japan).

## 7. Composite resin placement and colour adjustment at the tooth-composite resin interface

### 7.1. Composite resin placement

It has been established that shrinkage stresses develop in composite resin during polymerisation and if the cavities increase in size then volumetric shrinkage may also increase [33]. Polymerisation shrinkage cannot be avoided, and the adhesive system must possess sufficient mechanical strength to avoid being weakened [34]. Research using simulated occlusal cavities in resin and occlusal cavities cut in extracted human molarsshowed that an incremental filling technique was more effective in improving adhesion to the cavity floor than a bulk filling technique [34,35].

### 7.2. Colour adjustment at the restoration-tooth border

For patients, a good aesthetic outcome is often important and direct composite resin can give excellent results if attention is paid to shade matching with the surrounding tooth structure. The colour of the resin composite is influenced and perceived by various factors; colour elements of hue value and chroma; and optical properties. The optical properties include light transmission characteristics (straight-line and diffusion), translucency, fluorescence, and opalescence, along with the surface characteristics of the composite resin [36]. Composite resin and enamel are translucent materials, which can reflect colours from adjoining substrates, leading to the colour shifting between each other [36]. Obtaining a near “invisible” restoration margin through good colour matching with the adjacent tooth structure can help ensure a pleasing result for the patient (Fig. 5). Several factors come into play when considering how best to get a good colour match with a synthetic restorative material to natural living tooth structure.

Extracted human premolar teeth and four different composite resin restorative materials (Clearfil AP-X, Kuraray Noritake Dental Inc., Japan; Clearfil Majesty, Kuraray Noritake Dental Inc., Japan; Tetric N Ceram, IvoclarVivadent AG, Liechtenstein; and Ceram X mono, Dentsply Sirona, USA) have been used to look at the colour differences in four regions: the resin composite restorations, within the tooth, at the composite border area and at the tooth border area [37]. It was found that colour changes occurred at the borders of the composite resin restoration with the adjacent tooth structure and on both sides of the restoration border, within the tooth structure and the composite restoration [37]. Colour changes in the tooth structure adjacent to the restoration border were therefore due to colour reflection from the composite restoration. Colour changes within the border of the composite restoration were due to colour reflection from the tooth structure. Colour changes in the

tooth structure adjacent to the restoration border, were larger than the colour changes in the composite restoration adjacent to the border [37]. A goniophotometer was also used to investigate how light was transmitted through the four resin composite materials [37]. Ceram-X and Clearfil Majesty showed that light diffused more within the composite material than within Clearfil AP-X and Tetric N Ceram. Different depths of cavity preparation (1.5 mm and 3 mm) were also investigated [37]. For the 3 mm-deep cavities, the values for light diffusivity were compared with the colour differences measured for each material at the different border regions and it was concluded that the materials exhibiting good light diffusivity within the composite resin are able to create a chameleon effect as result of reflection of the surrounding tooth colour and projection of its own colour into the surrounding tooth structure, which would result in good colour matching [37]. On the otherhand, in the cavities that were 1.5 mm deep, it was found that light diffusivity had less influence on the colour changes and the colour rendition of the composite restorations was more influenced by the colour of the cavity floor. In the shallower cavity, the materials which exhibited better straight-line light transmission through the resin in this case, Tetric N Ceram, reflected the background colour better [37].

The clinical relevance of these findings is that in order to successfully colour match a composite restoration with the surrounding tooth structure, consideration must be given to the surrounding tooth structure, which might have to be masked. Moreover, the straight-line and diffused light transmission properties of the composite resin materials must be considered. Further work has been carried out on how the colour of the surrounding tooth structure might influence the colour of the composite restoration border [38].

### 7.3. Effect of tooth age on colour

How the age of the tooth, in particular colour changes that occur in dentine with aging, through factors such as physiological aging and the creation of transparent dentine as a result of mineral deposition in the dentinal tubules, might influence the colour of the restoration at the borders has been investigated [38]. Human premolars extracted for orthodontic reasons (younger teeth, age 20–28 years) and premolar teeth extracted for periodontal reasons (older teeth, age 45–69 years) were used along with four direct composite resins, Kalore (GC Corporation, Japan), Solare (GC Corporation, Japan), Clearfil Majesty (Kuraray Noritake Dental Inc., Japan) and Beautiful II (Shofu, Japan) all of shade A2 [38]. All four materials exhibited colour differences between the restoration borders and the dentine and composite resin in both the “younger” and “older” teeth, indicating “colour shifting” had occurred at the restoration borders [38]. However, when the “younger” and “older” teeth were looked at, colour differences in the older teeth at the restoration

borders were greater than those for the “younger” teeth, indicating that potential for colour adjustment in older teeth would be less than it would be for younger teeth [38]. The straight-line and diffusivity light transmission properties of the young and old dentine were also investigated. The older dentine exhibited higher straight-line light transmission values than younger dentine, indicating better light transmission, whereas the younger dentine exhibited better light diffusion values, indicating less light transmission [38]. Clinically, this would mean that better colour matching would be required when restoring older teeth compared to younger teeth.

#### 7.4. Effect of enamel margins on tooth colour

The effect of the enamel margin on colour adjustment has also been investigated [39]. Three types of enamel margin (non-bevel, 45-degree bevel and 45-degree reverse-bevel) and four composite resin materials (Estelite Asteria A2B, Tokuyama Dental Corp., Japan; Estelite Pro A2E, Tokuyama Dental Corp., Japan; Kalore E2, GC Corporation, Japan; and Clearfil Majesty ES-2 Premium A2E, Kuraray Noritake Dental Inc., Japan) were studied in bovine enamel [39]. The study found that the enamel margin configuration affected colour adjustment at the borders of the restoration with the bevel preparation improving colour adjustment at the borders [39]. With regards to the four composite resin materials, they had different values for straight-line light transmission and light diffusivity within the materials and the degree of colour adjustment at the borders of the restoration was material dependent [39].

If a cavity involved the labial aspect of the tooth, which is likely to be highly visible to the patient, then the orientation of the enamel prisms would differ depending on whether the cavity margin was in coronal or cervical regions of the enamel. Enamel prisms are the most important structure in enamel for influencing light scattering, an important optical property. The effect of enamel prism orientation on colour shifting at the border of composite resin restorations was investigated using bovine enamel and four composite resin materials (Estelite Asteria A2B, Estelite Pro A2E, Kalore E2 and Clearfil Majesty ES-2 Premium A2E) bonded using a one-step self-etching adhesive (Clearfil SE One) [40]. In the coronal enamel, the prisms would be cut diagonally, whereas in the cervical region, they would have been cut longitudinally [40]. Two sizes of composite restoration in enamel were prepared; 1 mm wide and 3 mm wide, both 1 mm thick. The colour shift in the L\* value was greater in the enamel side of the restoration [40]. The colour shift in the L\* value was also significantly greater at the cervical border than the coronal border and the difference in value was also larger in the small cavity [40]. Clinically this would indicate that the potential for colour adjustment, particularly lightness, is greater in the coronal border region of a composite restoration because the gentle colour shifting and larger area of colour shifting would make the restoration border less obvious.

#### 7.5. Effect of layering composite resin on colour

With regards to placement of the composite resin, as mentioned previously, placing the composite resin in increments can aid colour matching, ensure adequate polymerisation of the increment and minimize the effect of contraction stress on adhesion to cavity walls [41]. The effect of layering composite resin using both conventional and bulk-filling techniques on translucency and colour appearance has been investigated [41]. Three resin composites (Estelite Sigma, Tokuyama Dental Corp., Japan; Beautiful II, Shofu, Japan; Clearfil Majesty, Kuraray Noritake Dental Inc., Japan) in both A2 and OA2 shades were evaluated [41]. The universal (A2) shade specimens exhibited higher translucency than the opaque-shade (OA2) specimens, which would indicate that the OA2 shades would be better for masking colour [41]. In addition, layering in 1 mm-thick incre-

ments resulted in less transparency than a 2mm-thick increment indicating light diffusion occurring at the composite-composite joint [41]. Clinically this means that after a shade of composite resin is chosen, the final colour might change depending on how thick the increments of composite resin were when they were placed.

Finally, a restoration will be viewed by the patient from many directions and the effect of the direction of the light illuminating a direct composite restoration has been investigated [36]. It was found that the colour appearance at the border of composite resin restorations is influenced by the light illuminating direction in conjunction with the enamel rod orientation [36]. In other words, the appearance of a patient's restoration around the cavity margin, particularly towards the coronal aspect, will differ depending on the angle at which it is viewed by another person.

#### Conflicts of interest

None.

#### References

- [1] Izzetti R, Nisi M, Gabriele M, Graziani F. Covid-19 transmission in dental practice: brief review of preventive measures in Italy. *J Dent Res*. Available online April 17 2020 from doi.org/10.1177/0022034520920580.
- [2] Schwendicke F, Splieth C, Breschi L, Banerjee A, Fontana M, Paris S, et al. When to intervene in the caries process? An expert Delphi consensus statement. *Clin Oral Invest* 2019;23:3691–703.
- [3] Fusayama T. Two layers of carious dentin: diagnosis and treatment. *Oper Dent* 1979;4:63–70.
- [4] Kidd EAM. How “clean” must a cavity be before restoration? *Caries Res* 2004;38:305–13.
- [5] Mertz-Fairhurst EJ, Curtis JW, Ertle JW, Rueggeberg FA, Adair SM. Ultraconservative and cariostatic sealed restorations: results at Year 10. *J Am Dent Assoc* 1998;129:55–66.
- [6] Thompson V, Craig RG, Curro FA, Green WS, Ship JA. Treatment of deep caries lesions by complete excavation or partial removal. *J Am Dent Assoc* 2008;139:705–12.
- [7] Fusayama T, editor. A simple pain-free adhesive restorative system by minimal reduction and total etching. Ishiyaku Euro-America, Inc.; 1993. p. 1.
- [8] Pallesen U, van Dijken JWV. A randomized controlled 27 years follow up of three resin composites in Class II restorations. *J Dent* 2015;43:1547–58.
- [9] Pallesen U, van Dijken JWV. A randomized controlled 30 years follow up of three conventional resin composites in Class II restorations. *Dent Mater* 2015;31:1547–58.
- [10] Abou-Rass M. The stressed pulp condition: an endodontic-restorative diagnostic concept. *J Pros Dent* 1982;48:264–7.
- [11] Watson TF, Atmeh AR, Sajini S, Cook RJ, Festy F. Present and future of glass-ionomers and calcium-silicate cements as bioactive materials in dentistry: biophotonics-based interfacial analyses in health and disease. *Dent Mater* 2014;30:50–61.
- [12] Hashem D, Mannocci F, Patel S, Manoharan A, Brown JE, Watson TF, et al. Clinical and radiographic assessment of the efficacy of calcium silicate indirect pulp capping. A randomized controlled clinical trial. *J Dent Res* 2015;94:562–8.
- [13] Koubi G, Colon P, Franquin J-C, Hartmann A, Richard G, Faure M-O, et al. Clinical evaluation of the performance and safety of a new dentine substitute, Biodentine, in the restoration of posterior teeth – a prospective study. *Clin Oral Invest* 2013;17:243–9.
- [14] Nakajima M, Kunawarote S, Prasansuttiporn T, Tagami J. Bonding to caries-affected dentin. *Jpn Dent Sci Rev* 2011;47:102–14.
- [15] Nakajima M, Sano H, Burrow MF, Tagami J, Yoshiyama M, Ebisu S, et al. Tensile bond strength and SEM evaluation of caries-affected dentin using dentin adhesives. *J Dent Res* 1995;74:1679–88.
- [16] Yoshiyama M, Tay FR, Doi J, Nishitani Y, Yamada T, Itou K, et al. Bonding of self-etch and total-etch adhesives to carious dentin. *J Dent Res* 2002;81:556–60.
- [17] Taniguchi G, Nakajima M, Hosaka K, Iwamoto N, Ikeda M, Foxton RM, et al. Improving the effect of NaOCl pretreatment on bonding to caries-affected dentin using self-etch adhesives. *J Dent* 2009;37:769–75.
- [18] Kunawarote S, Nakajima M, Foxton RM, Tagami J. Pretreatment effect of mild acidic HOCl solution on adhesive to caries-affected dentin using self-etch adhesive. *Eur J Oral Sci* 2011;119:86–92.
- [19] Nikaido T, Inoue G, Takagaki T, Waidyasekera K, Iida Y, Shinohara M, et al. New strategy to create “super dentin” using adhesive technology: reinforcement of adhesive-dentin interface and protection of tooth structures. *Jpn Dent Sci Rev* 2011;47:31–42.
- [20] Inoue G, Tsuchiya S, Nikaido T, Foxton RM, Tagami J. Morphological and mechanical characterization of the acid-base resistance zone at the adhesive-dentin interface of intact and caries-affected dentin. *Oper Dent* 2006;31:466–72.
- [21] Nakabayashi N. Bonding of restorative materials to dentine: the present status in Japan. *Int Dent J* 1985;35:145–54.



- [22] Nikaido T, Weerasinghe DD, Waidyasekera K, Inoue G, Foxton RM, Tagami J. Assessment of the nanostructure of acid-base resistant zone by the application of all-in-one adhesive systems: super dentin formation. *Biomed Mater Eng* 2009;19:163–71.
- [23] Montes MA, de Goes MF, da Cunha MR, Soares AB. A morphological and tensile bond strength evaluation of an unfilled adhesive with low-viscosity composites and a filled adhesive in one and two coats. *J Dent* 2001;29:435–41.
- [24] Figueiredo Reis A, Giannini M, Ambrosano GM, Chan DC. The effects of filling techniques and a low-viscosity composite liner on bond strength to class II cavities. *J Dent* 2003;31:59–66.
- [25] De Goes MF, Giannini M, Di Hipólito, Carrilho MRO, Daronch M, Rueggeberg FA. Microtensile bond strength of adhesive systems to dentin with or without application of an intermediate flowable resin layer. *Braz Dent J* 2008;19:51–6.
- [26] Van Landuyt KL, Snauwaert J, De Munck J, Coutinho E, Poitevin A, Yoshida Y, et al. Origin of interfacial droplets with one-step adhesives. *J Dent Res* 2007;86:739–44.
- [27] Foxton RM, Melo L, Stone DG, Pilecki P, Sherriff M, Watson TF. Long-term durability of one-step adhesive composite systems to enamel and dentin. *Oper Dent* 2008;33:651–7.
- [28] Alex G. Universal adhesives: the next evolution in adhesive dentistry? *Compend Contin Educ Dent* 2015;1:15–26.
- [29] Yoshida Y, Yoshihara K, Nagaoka N, Hayakawa S, Tori T, Ogawa T, et al. Self-assembled nano-layering at the adhesive interface. *J Dent Res* 2012;91:376–81.
- [30] Taschner M, Kümmerling M, Lohbauer U, Breschi L, Petschelt A, Frankenberger R. Effect of double-layer application on dentin bond durability of one-step self-etch adhesives. *Oper Dent* 2014;39:416–26.
- [31] Thanatvarakom O, Prasansuttiporn T, Takahashi M, Thittaweerat S, Foxton RM, Ichinose S, et al. Effect of scrubbing technique with mild self-etching adhesives on dentin bond strengths and nanoleakage expression. *J Adhes Dent* 2016;18:197–204.
- [32] Muñoz MA, Luque-Martinez I, Malaquias P, Hass V, Reis, Campanha NH, et al. *In vitro* longevity of bonding properties of universal adhesives to dentin. *Oper Dent* 2015;40:282–92.
- [33] Feilzer AJ, De Gee AJ, Davidson CL. Increased wall-to-wall curing contraction in thin bonded resin layers. *J Dent Res* 1989;68:48–50.
- [34] Chikawa H, Inai N, Cho E, Kishikawa R, Otsuki M, Foxton RM, et al. Effect of incremental filling technique on adhesion of light-cured resin composite to cavity floor. *Dent Mater J* 2006;25:503–8.
- [35] Nayif MM, Nakajima M, Foxton RM, Tagami J. Bond strength and ultimate tensile strength of resin composite filled into dentine cavity; effect of bulk and incremental filling technique. *J Dent* 2008;36:228–34.
- [36] Hatayama T, Kano Y, Aida A, Chiba A, Sato K, Seki N, et al. The combined effect of light-illuminating direction and enamel rod orientation on color adjustment at the enamel borders of composite restorations. *Clin Oral Invest* 2019;(Oct 24), <http://dx.doi.org/10.1007/s00784-019-03085-7>.
- [37] Tsubone M, Nakajima M, Hosaka K, Foxton RM, Tagami J. Color shifting at the border of resin composite restorations in human tooth cavity. *Dent Mater* 2012;28:811–7.
- [38] Tanaka A, Nakajima M, Seki N, Foxton RM, Tagami J. The effect of tooth age on colour adjustment of resin composite restorations. *J Dent* 2015;43:253–60.
- [39] Aida A, Nakajima M, Seki N, Kano Y, Foxton RM, Tagami J. Effect of enamel margin configuration on color change of resin composite restoration. *Dent Mater J* 2016;35:675–83.
- [40] Kano Y, Nakajima M, Aida A, Seki N, Foxton RM, Tagami J. Influence of enamel prism orientations on color shifting at the border of resin composite restorations. *Dent Mater J* 2018;37:341–9.
- [41] Horie K, Nakajima M, Hosaka K, Kainose K, Tanaka A, Foxton RM, et al. Influences of composite-composite join on light transmission characteristics of layered resin composites. *Dent Mater* 2012;28:204–11.