

## Case Report

**Odontoid fracture with missed diagnosis of Transverse Atlantal Ligament (TAL) injury resulting in late-onset instability**

Mukesh Kumar Haritwal, Shankar Acharya, Kashmiri Lal Kalra, Rupinder Chahal, Nikhil Jain, Nitin Adsul

Department of Ortho-Spine Surgery, Sir Ganga Ram Hospital, New Delhi, India

E-mail: \*Mukesh Kumar Haritwal - 0788muke@gmail.com; Shankar Acharya - spineshankar@gmail.com; Kashmiri Lal Kalra - kashkalra55@hotmail.com; Rupinder Chahal - rupinder72@hotmail.com; Nikhil Jain - drnikhil.jn@gmail.com; Nitin Adsul - no1.nitinadsul@gmail.com

\*Corresponding author

Received: 13 September 18 Accepted: 11 October 18 Published: 28 November 18

**Abstract**

**Background:** Concurrent injuries to both the odontoid and transverse atlantal ligament are rare and can be easily missed. Failure to diagnose both lesions potentially leads to the late onset of sagittal plane instability and acute myelopathy. Here, we present a patient with an odontoid fracture whose transverse atlantal ligament (TAL) injury was originally missed on magnetic resonance imaging (MRI) and computed tomography (CT) scans. He later developed atlantoaxial instability requiring surgery.

**Case Description:** A 17-year-old male presented with neck pain, restricted cervical range of motion, but a normal neurological exam following a motor vehicle accident. The original X-rays showed a moderately displaced type-3 odontoid fracture. Additional MRI and CT scans excluded ligamentous injury, and he was initially treated with 13 weeks of halo vest immobilization. Radiographs 5 months later showed an enlarged atlanto-dens interval (e.g., >3 mm); the diagnosis of an odontoid fracture with an accompanying TAL injury was established, following which the patient successfully underwent a posterior C1–C2 fusion.

**Conclusion:** Odontoid fractures require strict clinical and radiographic (X-ray, MRI, CT) surveillance to help rule out accompanying TAL injuries that may warrant surgical intervention.

**Key Words:** Atlantoaxial instability, odontoid, transverse atlantal ligament injury

**Access this article online****Website:**[www.surgicalneurologyint.com](http://www.surgicalneurologyint.com)**DOI:**

10.4103/sni.sni\_315\_18

**Quick Response Code:****INTRODUCTION**

C2 fractures account for 20% of all cervical spine injuries, while odontoid fractures comprise 50% of these injuries.<sup>[2]</sup> Simultaneous injuries to both the transverse ligament and odontoid process are rare.<sup>[3,7]</sup> Injuries to the TAL are usually isolated or can be associated with atlas fractures. Early recognition of combined odontoid fractures and TAL injuries is critical to avoid delayed deformity and neurological injury. Here, we present a patient with both an odontoid fracture and TAL injury that was missed on the original MRI and CT studies. When he developed

late onset of atlantoaxial instability, a C1–C2 fusion was warranted.

This is an open access journal, and articles are distributed under the terms of the Creative Commons Attribution-NonCommercial-ShareAlike 4.0 License, which allows others to remix, tweak, and build upon the work non-commercially, as long as appropriate credit is given and the new creations are licensed under the identical terms.

**For reprints contact:** [reprints@medknow.com](mailto:reprints@medknow.com)

**How to cite this article:** Haritwal MK, Acharya S, Kalra KL, Chahal R, Jain N, Adsul N. Odontoid fracture with missed diagnosis of Transverse Atlantal Ligament (TAL) injury resulting in late-onset instability. *Surg Neurol Int* 2018;9:240. [http://surgicalneurologyint.com/Odontoid-fracture-with-missed-diagnosis-of-Transverse-Atlantal-Ligament-\(TAL\)-injury-resulting-in-late-onset-instability/](http://surgicalneurologyint.com/Odontoid-fracture-with-missed-diagnosis-of-Transverse-Atlantal-Ligament-(TAL)-injury-resulting-in-late-onset-instability/)

## CASE REPORT

A 17-year-old male presented 4 days following a motor vehicle accident with neck pain, restricted range of motion, but neurologically intact. X-rays revealed a moderately displaced Anderson & D'Alonzo type-3 odontoid fracture; however, the atlanto-dens interval (ADI) was maintained (e.g., excluding sagittal atlantoaxial instability) [Figure 1a]. Magnetic resonance imaging (MRI) ruled out a ligamentous injury [Figure 1b and c]. On computed tomography (CT), the ADI was less than 3 mm, and the fracture line was oriented from the posterosuperior margin of the odontoid base to the anteroinferior of the body of the axis [Figure 2]. There was no evidence of a transverse ligament injury.

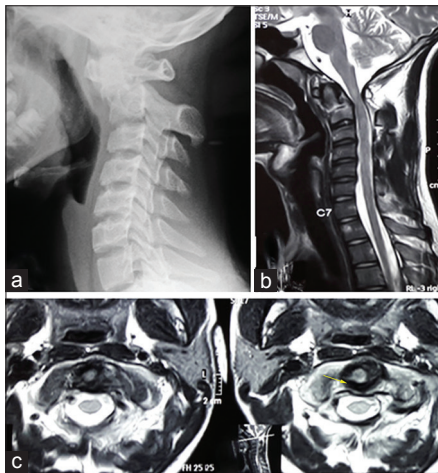
### Surgical intervention

The fracture was managed with closed reduction and halo vest immobilization [Figure 3]. Thirteen weeks

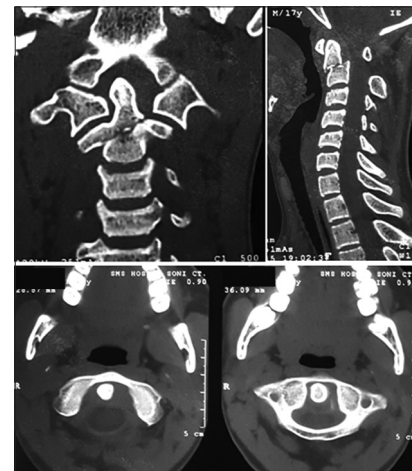
later, the fracture was fused on radiographs, and the halo vest was removed [Figure 4a and b]. At 17 weeks, however, X-rays showed a slight increase in the ADI (3.18 mm) [Figure 5a]. At 5 months, the patient developed frank atlantoaxial instability [e.g., widened ADI (9.18 mm) with cervical kyphosis (C2–C6 kyphosis = 33°) [Figure 5b]. A posterior atlantoaxial C1–C2 fusion was performed utilizing sublaminar wires and iliac crest bone graft [Figure 6a]. Postoperatively, a Philadelphia collar was applied. Solid fusion was achieved at 6 postoperative months [Figure 6b], and the 2-year follow-up showed some improvement in kyphosis (41° – 12° = 33°) [Figure 6c].

## DISCUSSION

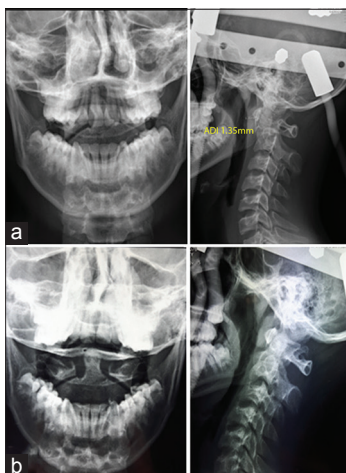
The delayed diagnosis of a TAL associated with an odontoid fracture is rare. In a retrospective review of 77 odontoid fractures, Sayama *et al.* concluded that odontoid fractures do not require MRI screening for TAL injury.<sup>[7]</sup> Similarly, Debernardi *et al.* reported 27 cases of traumatic (type II) odontoid fractures who acutely



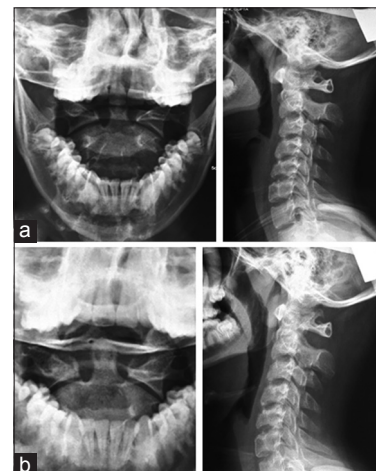
**Figure 1:** (a) Lateral radiograph showing moderately displaced odontoid fracture. (b and c) T2-weighted sagittal and axial MRI scans with no evidence of TAL injury



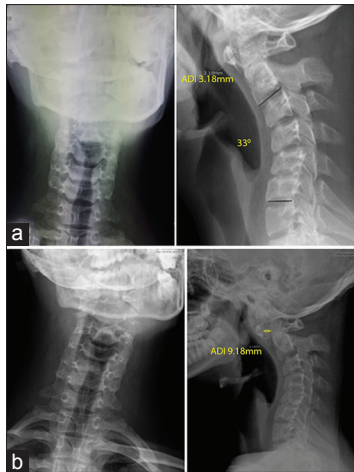
**Figure 2:** Preoperative CT scan showing fracture pattern



**Figure 3:** (a) Acceptable fracture reduction achieved after closed reduction in halo vest. (b) 4 weeks follow-up with well-aligned fracture



**Figure 4:** (a) Follow-up at 10 weeks. (b) Follow-up at 13 weeks



**Figure 5: (a) At 17 weeks, slightly increased ADI (3.18 mm) with C2–C6 cervical kyphosis of 33°. (b) At 5 months, large ADI of 9.18 mm showing frank instability**

underwent MRI (<72 h); they concluded MRI was unjustified for type II odontoid fractures.<sup>[3]</sup>

### Diagnosis and treatment of C1–C2 instability

Anterior widening of ADI more than 3 mm can be seen on mid-sagittal CT reconstructed images. Perez-Orribo *et al.* compared the CT and MRI measurements to detect the transverse ligament injury, they concluded that no current CT-based measurements consistently indicated integrity of transverse ligament.<sup>[6]</sup> The odontoid can fail in both flexion and extension,<sup>[9]</sup> whereas TAL ligament failure results in sagittal atlantoaxial instability (e.g., anterior displacement of C1 on C2).<sup>[11]</sup>

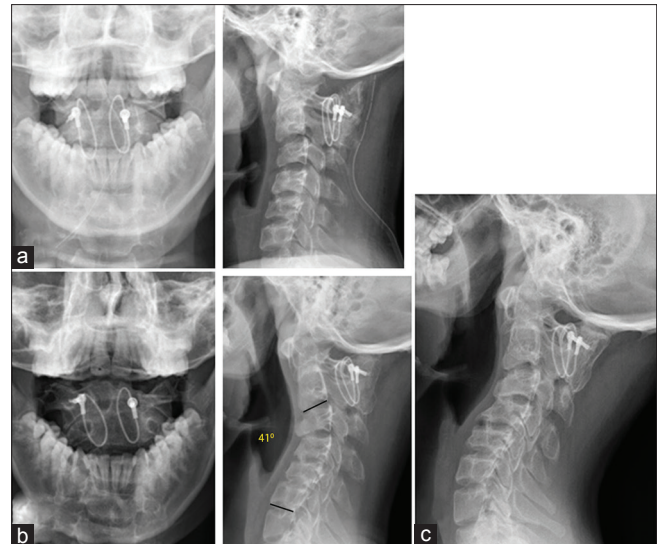
Most odontoid fractures, except for unreducible type II lesions, can be managed nonoperatively with rigid cervical immobilization. Julian *et al.* reported class III evidence for the successful conservative treatment of type III odontoid fractures utilizing rigid cervical immobilization (e.g., halo vest).<sup>[5]</sup> Alternatively, odontoid fractures with concomitant TAL injuries typically require early posterior atlantoaxial fusion. Sherekar concluded that, if the lordosis of the occiput and upper cervical spine increases, the subaxial cervical spine may develop kyphosis.<sup>[8]</sup> Similarly Huang *et al.* reported that surgical over-reduction and hyperlordotic fusion of C1–C2 joint are associated with cervical sagittal malalignment.<sup>[4]</sup>

## CONCLUSION

We recommend screening of odontoid fractures for transverse ligament injury with both MRI and CT. If conservative management is used (e.g., halo device), strict radiographic surveillance is required to look for progressive kyphosis/deformity/instability.

### Declaration of patient consent

The authors certify that they have obtained all appropriate patient consent forms. In the form the



**Figure 6: (a) Postoperative AP and lateral radiographs after posterior fusion with sublaminar wiring and iliac crest bone graft. (b) 6 months follow-up AP and lateral radiographs showing fusion and C2–C6 cervical kyphosis of 41°. (c) 2 years follow-up showing resolution of some of kyphosis**

patient(s) has/have given his/her/their consent for his/her/their images and other clinical information to be reported in the journal. The patients understand that their names and initials will not be published and due efforts will be made to conceal their identity, but anonymity cannot be guaranteed.

### Financial support and sponsorship

Nil.

### Conflicts of interest

There are no conflicts of interest.

## REFERENCES

- Bono CM, Carreras E. Cervical spine fractures and dislocations. In: Rockwood and Green's Fractures in Adults. 7<sup>th</sup> ed. Philadelphia, PA: Wolters Kluwer, Lippincott Williams & Wilkins; 2010. p. 1313-77.
- Bransford RJ, Patt JC, Chapman JR. Odontoid fractures. In: Benzel EC, editor. The Cervical Spine. 5<sup>th</sup> ed. Philadelphia, PA: Wolters Kluwer, Lippincott Williams & Wilkins; 2012. p. 632-64.
- Debernardi A, D'Aliberti G, Talamonti G, Villa F, Piparo M, Cenzato M. Traumatic (type II) odontoid fracture with transverse atlantal ligament injury: A controversial event. *World Neurosurg* 2013;79:779-83.
- Huang J, Qian B, Qiu Y, Yu Y, Ni HB. Surgical overreduction and hyperlordotic fusion of C1-C2 joint are associated with cervical sagittal malalignment. *Arch Orthop Trauma Surg* 2017;137:1631-9.
- Julien TD, Frankel B, Traynelis VC, Ryken TC. Evidence-based analysis of odontoid fracture management. *Neurosurg Focus* 2000;8:e1.
- Perez-Orribo L, Snyder LA, Kalb S, Elhadi AM, Hsu F, Newcomb AG. Comparison of CT versus MRI measurements of transverse atlantal ligament integrity in craniovertebral junction injuries. Part I: A clinical study. *J Neurosurg Spine* 2016;24:897-902.
- Sayama CM, Fassett DR, Apfelbaum RI. The utility of MRI in the evaluation of odontoid fractures. *J Spinal Disord Tech* 2008;21:524-6.
- Sherekar SK, Yadav YR, Basoor AS, Baghel A, Adam N. Clinical implications of alignment of upper and lower cervical spine. *Neurol India* 2006;54:264-7.
- Tay BK, Eismont FJ. Injuries of the upper cervical spine. In: Rothman-Simeone. The Spine. 6<sup>th</sup> ed. Philadelphia, PA: Saunders/Elsevier; 2011. p. 1307-12.