



Case report

A rare case of massive foreign body aspiration mimic asthma

Mohammad Ashkan Moslehi

Pediatric Interventional Pulmonology Division, Shiraz University of Medical Sciences, Namazi Hospital, Namazi Square, Shiraz, Iran



ARTICLE INFO

Keywords:

Foreign body aspiration
Asthma
Pneumonia
Bronchoscopy
Cryotherapy
Massive

ABSTRACT

Foreign Body Aspiration (FBA) remains as one of the leading causes of morbidity and mortality among pediatrics, especially in younger ones. Asphyxia caused by FBA is a main and common cause of this morbidity and mortality. Unfortunately, many FBAs may be misdiagnosed and an appropriate management becomes postponed specially in cases without any vivid evidence. Due to wide spectrum of signs and symptoms, FBA can be easily misdiagnosed with a recurrent pneumonia, asthma and immunodeficiency disorders. In this case report, the author presents the case of a 4-year-old girl who aspirated a massive amount of meat. She had been misdiagnosed with asthma and pneumonia for about 4 months, but eventually the problem was managed by an extraction using bronchoscopy cryoprobe.

1. Introduction

FBA is a common cause of respiratory compromise in early childhood. Aspiration could be presented as a spectrum, ranging from mild transient coughing to more severe events including cyanosis, choking, respiratory distress and or even death. In the group of children up to 3 years, the presence of a foreign body in the respiratory tract accounts for 7% of sudden deaths [1]. The diagnosis of an airway FB is made mostly based on the complete history of aspiration from child's whole family members or caregivers. The classic presentation triad of choking, persistent cough, and unilateral wheezing or decreased air movement in one side are seen in many patients with FBA. Positive chest x-ray findings consist of increased radiolucency of one lung or lobe, consolidation, collapse and sometimes pneumothorax. In up to 30% of cases of FBA, no obvious abnormality is visible in the given chest x-rays [2]. Without a chest x-ray positive suspicious for FB (like metal), this modality is not useful to predict or exclude FBA and should be avoided to reduce x-ray radiation [3]. Major complications of FBA range from pneumonia, atelectasis, bronchiectasis, hemoptysis, pulmonary edema, pneumothorax, pneumomediastinum, hypoxic neurologic damage due to asphyxia and cardiopulmonary arrest. To prevent these complications, early diagnosis and removal of the foreign body are necessary. In this case report, a 4-year-old girl with a large amount of meat in her left main bronchus is presented. To the best of the author's knowledge, the index case is the first pediatric patient with this type of massive meat aspiration managed by using bronchoscopy cryoprobe.

2. Case report

A 4-year-old girl was admitted to Namazi hospital affiliated to Shiraz University of Medical Sciences, Shiraz, Iran in October 2017. She complained about productive coughs, breath shortness and wheezing for approximately 4 months prior to the admission. She was diagnosed with asthma and had been treated with salbutamol and fluticasone for a month. Despite relative symptomatic relief after using bronchodilators, symptoms continuation resulted in multiple physician visits over time. For two times she had a hospital admission with impression of asthma exacerbation and recurrent pneumonia. Since there was a recurrence of the symptoms and no more improvement was observed, the patient was referred to my clinic for further evaluation. On her first visit, her parents revealed she had a history of choking 4 months ago while eating her food in the restaurant. Also, there was not any history of asthma and allergies in her family. Her birth history was normal, too.

During the physical examination, the patient did not have any respiratory distress. On auscultation, there was reduced air entry on the left side with minimal rhonchi and basal crepitation. Other physical examination results were within normal limits. Her vital sign measurements included the following: pulse rate, 95 to 116 beats per minute; respiratory rate, 25 to 30 breaths per minute and axillary temperature 37.3 °C. Except her White Blood Cell (WBC) count (17000 mm³ with 70% polymorphonuclear leukocytes) and C-Reactive Protein (95 mg/L), other laboratory findings were in the normal range. The chest radiography revealed left lung collapse consolidation (Fig. 1). Flexible bronchoscopy was ordered to exclude the possibility of aspiration material blocking the airway. The patient was taken to bronchoscopy suite

E-mail address: ashkanmoslehi@gmail.com.

<https://doi.org/10.1016/j.rmcr.2019.100963>

Received 14 September 2019; Received in revised form 24 October 2019; Accepted 27 October 2019

Available online 31 October 2019

2213-0071/© 2019 Published by Elsevier Ltd. This is an open access article under the CC BY-NC-ND license (<http://creativecommons.org/licenses/by-nc-nd/4.0/>).

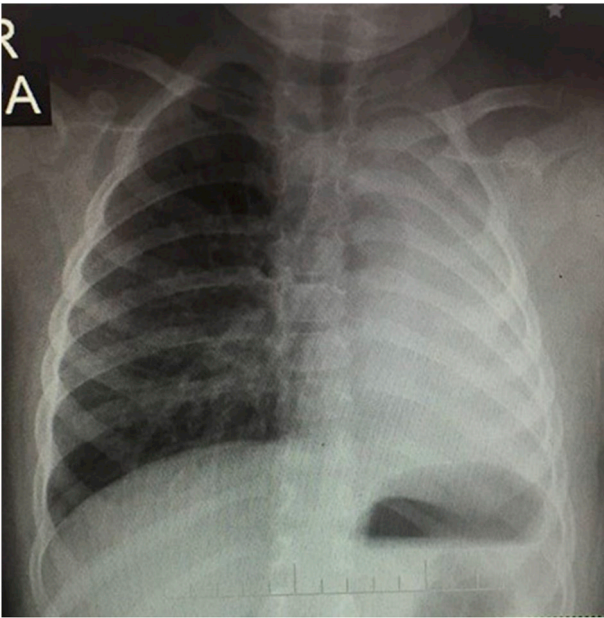


Fig. 1. Left lower lobe collapse and consolidation.

for diagnostic and therapeutic bronchoscopy. The patient was sedated with intravenous Propofol (1 mg/kg), and sedation was maintained within the needed doses of Propofol with maintaining the patient's own spontaneous breathing. Nasopharyngeal canula was placed just above the vocal cord in order to apply the needed oxygenation. Vital signs were carefully monitored by cardiopulmonary monitoring, pulse oximetry and capnography. A pediatric bronchoscope sized 4.2 mm (Olympus, Japan) was introduced through the oral route. There were lots of copious secretion in the left main bronchus and after applying gentle suctioning, a massive amount of meat which fully obliterated the bronchus was noted. The right side was inflamed without any FBs. Due to friable nature of this type of FB, the FB forceps failed to grasp the food chunk. Thus, the author used a flexible cryoprobe size 1.8 mm with the Length of 900 mm (ERBE, Germany). After introducing the probe through the working channel of bronchoscope to the 10 mm deep inside the meat, 10 second freezing was applied. Then, the cryoprobe with the adhered part of the FB was removed en bloc along with the flexible bronchoscope (Fig. 2). As there were massive amounts of meat impaction, the procedure was repeated five times until no more meat remained and the bronchus became fully opened (Fig. 3).

Thereafter, the bronchoalveolar lavage was applied as there was large amounts of thick secretions that were trapped behind the FB. The total extraction procedure time was about 10 minutes. No acute or post procedure complications were happened. Antibiotics and dexamethasone were ordered after the procedure. The patient awaked quickly having good condition. The post operation chest x-ray was normal (Fig. 4).

3. Discussion

Foreign body aspiration (FBA) into the larynx, trachea and bronchi can cause a lot of morbidity and mortality by obstructing the airways and disrupting the oxygenation and ventilation. The classic presentation triad of choking, persistent cough, and unilateral wheezing or decreased air movement in one side are seen in many patients with FBA. An accurate history of an acute choking episode followed by coughing or wheezing is helpful in the establishment of an FBA diagnosis. Retained FBs and delayed diagnosis of FBA specially in pediatric age groups can account as one of the most challenging problems for interventional bronchoscopist and may result in chronic wheezing, persistent cough and serious complications such as pneumonia, atelectasis, abscess

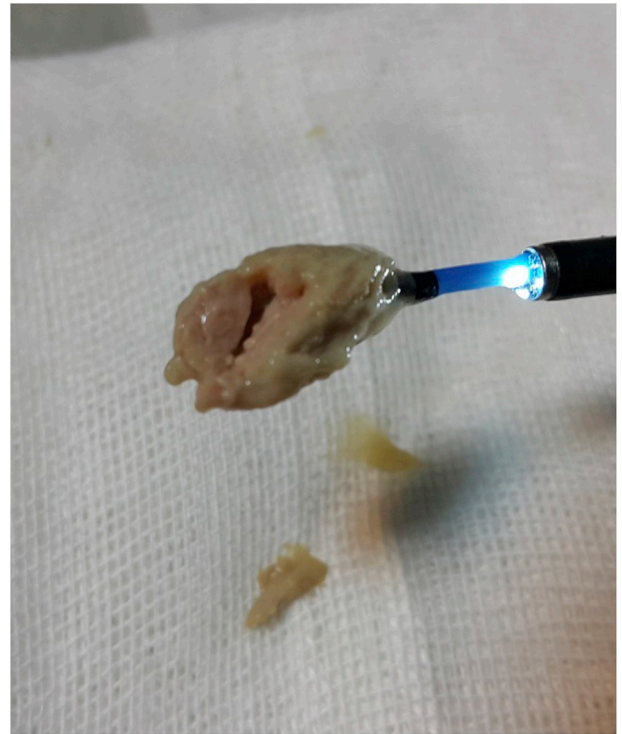

Fig. 2. Flexible bronchoscope with cryoprobe and the adhered foreign body (Meat).

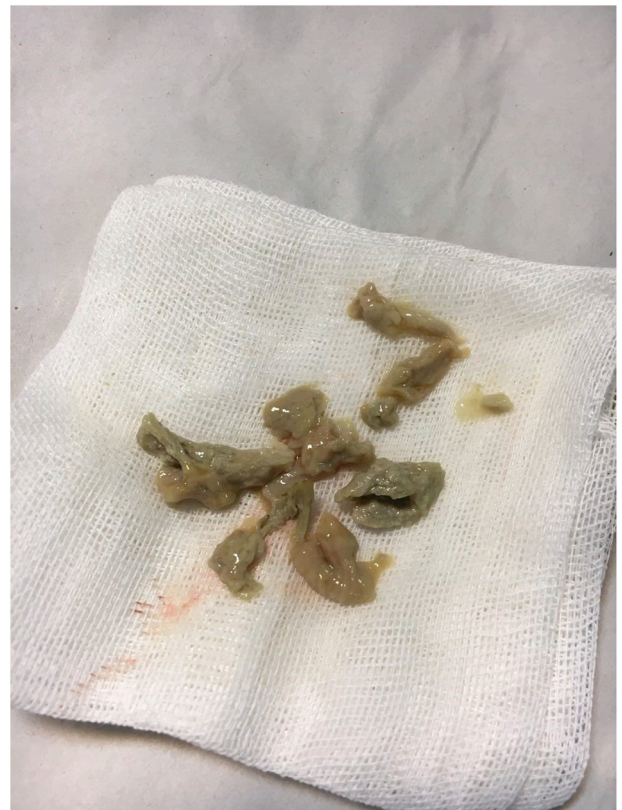

Fig. 3. Massive meat after extraction.

formation, hemoptysis and bronchiectasis. In the index case, the child had asthma like symptoms for about four months. She received medications for asthma but the symptoms remained and progressed. In her

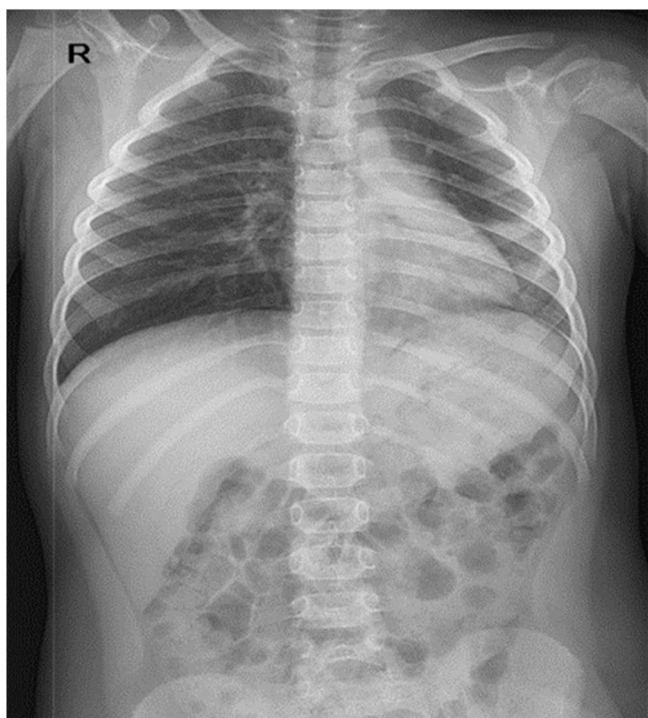


Fig. 4. Normal Post operation Chest x-ray.

chest x-ray, there was a collapse and consolidation due to a retained FB which fully obliterated the left main bronchus, shifting the mediastinum toward the left side and compensatory right lung hyperinflation with herniating to the left side.

Rigid bronchoscopy is the treatment of choice in cases with confirmed foreign bodies due to better airway patency control, good visualization and more power for the removal of the foreign objects in this method. Although rigid bronchoscopy was formerly the preferred treatment method for the removal of a foreign body in the airway [4], flexible bronchoscopy is a less invasive and more cost-benefit method and is recommended in children with insufficient findings for definite diagnosis of FBA with newer wide variety of forceps, baskets and flexible cryoprobes. Thoracotomy is another method for the removal of the foreign objects that cannot be removed by bronchoscopy in more complicated cases.

Although there are many reports of vegetable aspiration, the cases of meat aspiration seem to be few and only were reported in adults mostly with Café Coronary syndrome which was first reported as a sudden collapse at restaurants while dining and was found to be due to the fatal occlusion of the upper airway with large pieces of food [5].

Three other fatal meat aspiration cases were reported by Ben Dhiab et al., in 2012. All these three patients died due to the complete obstruction of the airways. One of these patients had larynx obstruction in autopsy and other two patients consumed excessive amount of alcohol. In this study, old age, alcohol consumption, and poor dentition were considered as the main risk factors of fatal aspiration in adults [6].

Another study reported a piece of meat and bone lodged in the left main stem bronchus in a 48-year-old male brought to the emergency department after an out-of-hospital cardiac arrest following FBA. The foreign body was removed with the bronchoscope and the patient clinically improved with full neurological recovery [7].

The most recent report in 2018 described a twelve-year-old boy with chicken meat aspiration. He was admitted due to a traumatic brain injury but during craniotomy procedure, the O₂ saturation decreased to a level of 80% and on auscultation, there was a reduced air entry on the left side. An urgent bronchoscopy was performed for him to exclude the possibility of aspiration. A 3 cm piece of chicken meat (was) removed via bronchoscopy and the saturation immediately raised to 100% [8].

To the best of the author's knowledge, this case is the first case with this amount of solid food aspiration. Previous reports on meat aspiration showed acute and fatal symptoms. But in this case, despite the large size of the aspirated particles, the patient indicated chronic symptoms. The bronchoscopy with cryotherapy was performed for this case to remove a massive aspirated meat, mucous plugs and granulation tissues.

The index case emphasized that a potential Airways FBs should be considered in the differential diagnosis of any patient with acute onset and recurrent respiratory symptoms without any previous history of allergic manifestations and recurrent pneumonia, especially in those who did not respond to antiasthma or antibiotic treatments. Prompt diagnosis and bronchoscope-assisted removal of foreign body were found to be successful to reduce morbidity and mortality. Nowadays, cryoprobes in experts' hands can managed many types of FBs especially the friable types.

Funding

This research did not receive any specific grant from funding agencies in the public, commercial, or not-for-profit sectors.

Declaration of competing interest

The authors have no conflicts of interest to disclose.

References

- [1] H. Rizk, S. Rassi, Foreign body in halation in the pediatric population: lessons learned from 106 cases, *Eur. Ann. Otorhinolaryngol. Head Neck Dis.* 128 (2011) 169–174.
- [2] K. Polat, A. Ali, K. Ismail, et al., Low-dose MDCT and virtual bronchoscopy in pediatric patients with foreign body aspiration, *AJR* 183 (2004) 1771–1777.
- [3] J. Kaufmann, M. Laschat, U. Frick, Determining the probability of a foreign body aspiration from history, symptoms and clinical findings in children, *Br. J. Addict.: Br. J. Anaesth.* 118 (2017) 626–627.
- [4] M. Oncel, G.S. Sunam, S. Ceran, Tracheobronchial aspiration of foreign bodies and rigid bronchoscopy in children, *Pediatr. Int.* 54 (2012) 532–535.
- [5] R. Wick, J.D. Gilbert, R.W. Byard, Café coronary syndrome-fatal choking on food: an autopsy approach, *J. Clin. Forensic Med.* 13 (3) (2006 Apr) 135–138.
- [6] M. Ben Dhiab, M. Jdidi, N. Ben Mansour, et al., Fatal meat aspiration: a report of three cases and review of the literature, *J. Clin. Pathol. Forensic Med.* 3 (2) (December 2012) 12–16.
- [7] M. Kashif, H. Rizwan Talib Hashmi, M. Khaja, Early recognition of foreign body aspiration as the cause of cardiac arrest, *Case Rep. Crit. Care* (2016) 4.
- [8] N. Afeef Mohd Ariff, M. Zulfakar Mazlan, M. Erham Mat Hassan, et al., Undiagnosed chicken meat aspiration as a cause of difficult-to-ventilate in a boy with traumatic brain injury, *Respir. Med. Case Rep.* 23 (2018) 93–95.