

CONCEPTS

General Medicine

Evaluation and management of urethral foreign bodies and description of a novel ultrasound-guided catheter-based extraction technique

Scott B. Crawford MD | Drew Lowry DO | Susan H. Watts PhD

Department of Emergency Medicine, Texas Tech University Health Sciences Center El Paso, El Paso, Texas, USA

Correspondence

Scott B. Crawford, MD, Department of Emergency Medicine, Texas Tech University Health Sciences Center El Paso, 210 Rick Francis Suite 302 F, El Paso, TX 79905, USA.
Email: Scott.crawford@ttuhsc.edu

Funding and support: By *JACEP Open* policy, all authors are required to disclose any and all commercial, financial, and other relationships in any way related to the subject of this article as per ICMJE conflict of interest guidelines (see www.icmje.org). The authors have stated that no such relationships exist.

Abstract

There are numerous reports in the medical literature documenting urethral foreign bodies with nearly all cases found in men and often associated with underlying psychiatric disorders, autoerotic stimulation, and/or intoxication. Patients most commonly presented with localized penile pain, hematuria, dysuria, and occasionally obstruction. Although endoscopic removal by a urologist is often the first-line treatment, this report describes evaluation and management considerations and presents a novel extraction technique that may allow emergency physicians in consultation with urology to perform removal of some unusual urethral foreign bodies in the emergency department. We report a novel extraction technique using a pediatric foley catheter under ultrasound guidance that has been applied during multiple encounters with 2 individuals who have each presented multiple times at a single emergency department (ED) for evaluation because of urethral foreign body insertion. The foreign body materials have ranged from small pieces of rubber to cellophane to styrofoam and most commonly plastic utensils. Urologic extraction may be required in some cases, but ED removal can be considered. A final discussion of the creation of a multidisciplinary care plan to address resource use concerns also is described.

KEYWORDS

catheter, foreign body, penis, ultrasound, urethra, urethral sounding

1 | INTRODUCTION

Reports detailing care for urethral foreign bodies have been recorded in the medical literature since the 1950s. Nearly all cases have been reported in men, with the majority of cases being attributed to underlying psychiatric disorders, autoerotic stimulation, intoxication, and rarely self-mutilation.¹⁻⁶ Appropriate and accurate physical examination with a thorough history of present illness (HPI) in the

emergency department can improve both patient care, resource use, and emergency department (ED) throughput. Early evaluation with ultrasound imaging may assist with patient management decisions; advanced imaging generally is not required. Similarly, specialist care by a urologist is not always indicated or required. In appropriately selected cases, emergency physicians are qualified to attempt removal of penile/urethral foreign bodies. We report 3 encounters from 2 separate patients who have each presented to the ED dozens of times for evaluation and care of urethral foreign body insertion, also called "urethral sounding."⁷

Supervising Editor: Lara N. Goldstein, MD, PhD.

This is an open access article under the terms of the [Creative Commons Attribution-NonCommercial-NoDerivs](https://creativecommons.org/licenses/by-nc-nd/4.0/) License, which permits use and distribution in any medium, provided the original work is properly cited, the use is non-commercial and no modifications or adaptations are made.

© 2021 The Authors. *JACEP Open* published by Wiley Periodicals LLC on behalf of American College of Emergency Physicians

2 | CASE PRESENTATIONS

Over a span of 18 months, a man in his 40s presented to a county hospital ED over 24 times for urethral foreign body insertion. Of these, 14 objects were removed by urology in the operating room and 7 were successfully removed by the emergency physician and 1 was removed by a urologist using forceps at the bedside. On 2 occasions, the patient refused treatment and was discharged to outpatient urology for follow-up care. The patient had a history of schizophrenic disorder, traumatic brain injury, bipolar disorder, obsessive compulsive disorder (OCD), post-traumatic stress disorder, and anxiety. He had no substance abuse history. Another patient also in his 40s presented over 30 times in a 2-year period for recurrent foreign body placement. He most commonly received urologic consultation and cystoscopy and even required repeated treatment during 1 visit for repeated placement while admitted. He described a history of “sounding” behavior for over 20 years. He also had a reported history of schizophrenia and anti-social personality.

Both patients had general reports of dysuria, local discomfort, hematuria, and mild difficulty with urination but neither ever experienced complete urethral obstruction. The recurrence of these patient visits prompted the development of a systemwide coordination of care plan to address resource use and treatment. Three example encounters from these patients are reviewed to highlight the benefits of ultrasound imaging in patient evaluation as well as a novel removal technique.

3 | ULTRASOUND IMAGING EVALUATION OF DISTAL URETHRAL FOREIGN BODY

The patient presented with urethral pain and reported inserting a plastic spoon handle into his urethra. A point-of-care ultrasound was performed using a linear 13–6 MHz probe placed on the proximal dorsal penis, allowing visualization of the palpated foreign body that demonstrated increased echogenicity and artifact/shadowing (Figure 1). Point-of-care ultrasound also confirmed that the object had not migrated further up into the proximal urethra, prostate, or bladder. Ultrasound findings negated the need for radiographic imaging and eliminated further delay in care, which would have occurred if computerized tomography imaging had been necessary. Removal was performed at bedside using hemostats after instillation of lidocaine gel into the urethral meatus.

4 | ULTRASOUND IMAGING FOLLOWED BY BEDSIDE EXTRACTION USING A PEDIATRIC FOLEY CATHETER

The patient presented to the ED complaining of penile pain, hematuria, and difficulty with urination owing to self-insertion of rubber from the sole of his shoe into his urethra. Physical examination noted a palpable

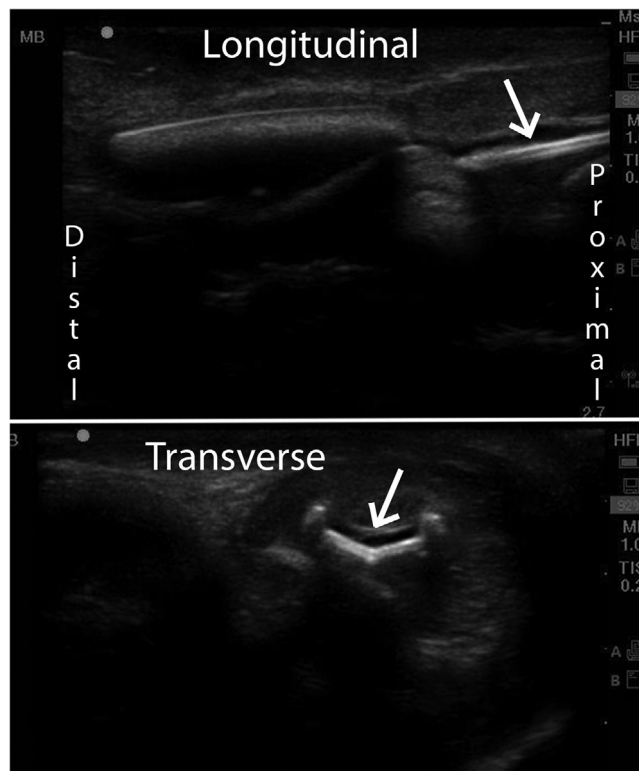


FIGURE 1 Ultrasound examination of a urethral foreign body in longitudinal and cross-sectional views. The object shown is a plastic spoon handle

foreign body at the base of the penile shaft with irregularly shaped borders that were firm, pliable, and without rigidity. A small amount of blood was noted in the urethral meatus but there were no other external signs of trauma or injury.

After visualization and confirmation of a foreign body by point-of-care ultrasound, removal was performed under direct ultrasound visualization. First, 10 cc of 2% viscous lidocaine was administered into the urethra followed by manual occlusion of the urethral meatus to retain the lidocaine within the urethra. After 5–7 minutes of local intraurethral anesthetic, a 6-french pediatric silicone foley catheter was passed into the urethra and past the foreign body, all visualized using real-time ultrasound. The foley catheter balloon was then inflated proximal to the foreign body using the recommended 2 cc of sterile saline. Under real-time ultrasound visualization, the catheter and inflated balloon were gently and slowly withdrawn (Figure 2). The balloon successfully guided the foreign body distally through the urethra toward the meatus and was successfully removed (Figure 3). The procedure was well tolerated by the patient and there were no complications.

A follow-up retrograde urethrogram plain film X-ray was performed after the removal of the foreign body the first time this procedure was performed. This demonstrated there was no extravasation or signs of stricture, laceration, fistulous track, and/or obstruction. The patient was discharged with instructions to follow up with his primary care physician.

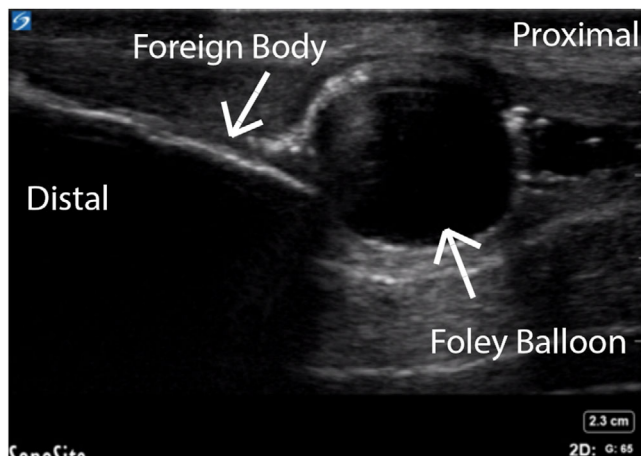


FIGURE 2 Longitudinal view of urethra with foley balloon (right) used to remove foreign body (left)

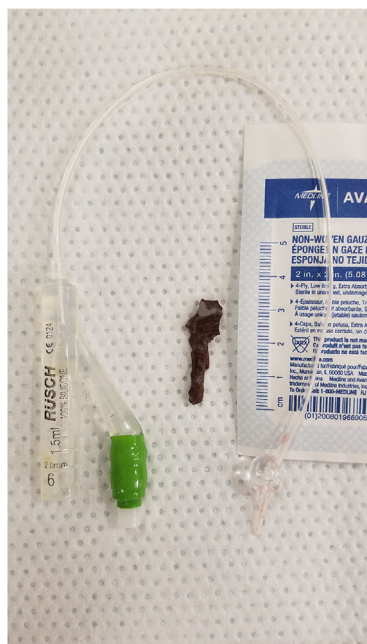

FIGURE 3 Extracted foreign body from Example 2 and demonstration of the size of the inflated pediatric foley catheter balloon are shown

5 | ULTRASOUND EVALUATION AND REMOVAL OF MULTIPLE FOREIGN BODIES WITH PEDIATRIC FOLEY CATHETER

This patient arrived with a reported insertion of 2 foreign bodies into his urethra the night before. He described local discomfort and some difficulty with urination but not complete obstruction. The patient directed the examiner to the location of the foreign bodies palpable in the proximal urethra between the scrotum and shaft of the penis. He reported they were 2 pieces of smooth plastic from a prior hospital identification band. A point-of-care ultrasound examination was performed to evaluate for bladder distention and to identify the location

and size of the foreign body (Video S1). Linear shadowing $\sim 1 \times 2.5$ cm was identified at the proximal urethra (close to the prostate). After discussion of the procedure with the patient, 10 cc of 2% urethral lidocaine gel were instilled and the distal meatus occluded to achieve anesthesia. Under real-time visualization with a linear ultrasound probe placed on the proximal ventral aspect of the penis, a 6-french pediatric foley was inserted and observed to pass beyond the foreign body without advancing the obstruction (Video S1). Then, 2 cc of sterile saline were used to inflate the foley balloon and gentle traction was applied to sweep the foreign body toward the urethral meatus under continuous observation (Video S1). Subsequent urinalysis revealed WBCs without bacteria and the patient was provided a prescription of oral cephalexin for 5 days.

6 | DISCUSSION

There are numerous reports in literature describing urethral foreign body insertion¹ with nearly all cases being in males; only 1 case has been reported in a female.^{1,2} The first recorded case of a foreign body being applied to the penis dates back to 1755. Since this time, the variety of objects applied to or within the penis/urethra is diverse. Documented objects include but are not limited to manufactured erotic toys, electrical wires, razors, plastic utensils, screws, tubing, writing utensils, light bulbs, watches, mechanical tools, animals and/or their parts, plants, fluids, and powders.^{1,2,5} The documented reasons for self-insertion of urethral foreign bodies most commonly involve eroticism with sexual intent, attention seeking, psychiatric/mental illness, incarcerated/institutionalized individuals, mimicking, attempts to evacuate urine, ceremonial acts, and intoxication.^{1-6,8-11}

7 | CLINICAL MANAGEMENT

Patients who present multiple times are not uncommon, especially among incarcerated/institutionalized individuals.⁸⁻¹⁰ Symptoms and clinical presentation range from asymptomatic to full obstruction with severe bladder distension, swelling of external genitalia, injury to partner, dysuria with or without gross pyuria, or possible derangement of genitalia if self-mutilation was the intent.^{5,6,10} In addition to urethral foreign bodies, subcutaneous penile foreign bodies placed on the penile shaft, particularly in incarcerated patients, have also been reported and may require evaluation for urethral or corporal body injury.^{12,13} Many patients may have already made multiple attempts at self-removal or have delayed seeking help, sometimes because they don't want to openly discuss the actual cause of their complaint and are hoping to avoid embarrassment.^{5,10,11}

The first step in the management of such cases is to determine the location, size, and nature of the object. If the object is distal, palpable, mobile, and small, no imaging is required.² When appropriate, non-invasive bedside imaging (bedside ultrasound and/or radiographs) is the recommended modality. Once the object has been assessed, the management and removal of the object can be undertaken.

TABLE 1 Care Plan Outline—Outline of topics and considerations in the multidisciplinary coordination of care plan created to expedite care and minimize resource use

Care plan outline
<ul style="list-style-type: none"> Emphasize the importance of removing access to foreign objects Ultrasound imaging to evaluate for the presence of a foreign body and/or bladder obstruction
<ul style="list-style-type: none"> Temperature monitoring to evaluate for signs of systemic infection Urinalysis to identify for local urinary tract infection
<ul style="list-style-type: none"> Timing and expectation for urology consultation; immediate removal if possible, or scheduled removal with delay up to 24–48 hours if no signs of infection

Manual extraction in the ED can be attempted if the object is in the distal urethra and is palpable, mobile, small, and if there is no evidence of gross hematuria.² Forceps/graspers may be considered for proximal objects but should not be used for any object inserted more proximally than the distance from the tip to the fulcrum of the instrument because of potential trauma or inability to open the instrument once the foreign body has been located.

If the initial attempt for removal by manually sweeping (expressing) the urethra is unsuccessful, then removal assisted by a 6-french pediatric foley catheter could be considered, as described previously, especially when the foreign body is located in the proximal urethra and is closer to the less compliant perineal/prostatic tissue. The foley catheter approach was well tolerated by the patients described and has been successful in all 5 cases in which it was implemented by the authors. This method was undertaken because the overall average diameter of the male urethra from the posterior urethra to the urethral meatus is 8–9 mm (range 8–12 mm).¹⁴ The 6-french foley catheter has an ~1 cm balloon (Figure 3), which produces minimal additional dilation to the urethral tissue past its resting diameter. When the balloon is filled with 0.5–2cc of fluid, it will not exceed the maximum dilated width of the male urethra; which was found to be 28.49 french (9.5 mm) in a recent study in Indian males.¹⁵ Compared to the use of forceps/graspers, a pediatric foley catheter may reduce trauma to the urethra.

This novel procedure may be appropriate in the setting described here, but if the foreign body is large, nonpalpable, reportedly sharp, immobile, associated with gross hematuria, or is in the most proximal portion of the urethra, then consultation with urology is recommended. Management in these cases will likely require cystourethroscopy, open urethrotomy, and/or open cystostomy.²

Although the primary goal of treatment is foreign body removal, one must also consider potential short- and long-term complications that include stricture, urethral diverticula, erectile dysfunction, and incontinence. These are dependent on the depth of the initial insertion, repetition of foreign body insertion, and the extraction modality necessary for removal.² A common short-term complication is urinary tract infection. Foreign body insertion into the urethra is traumatic and warrants antibiotic prophylaxis. Because of the urethra's thin sub-

mucosal layer and the high vascularity from the surrounding corpus spongiosum, bacteria may easily enter the hematologic system even in the absence of intimal tears.¹⁴ Infection may initiate progressive inflammation with possible progression to systemic sepsis and/or Fournier's gangrene.² When appropriate, psychiatric evaluation and follow-up may help prevent this behavior.⁵ Along with evaluation of direct effects on the patient, one must also consider the effect that repeat presentations create on the healthcare system and the need to break the cycle through novel approaches.^{8,10}

Because of significant resource use, a “coordination of care plan” was created by the hospital staff for 1 of these patients to safely expedite his medical evaluation and minimize possible secondary gain. This plan involved case review by physicians from emergency medicine, psychiatry, internal medicine, urology, and hospital leadership. Implementation allowed a pop-up window to appear in the electronic health record whenever the patient was registered (Table 1). The treatment goal was to allow safe removal while minimizing use of medical resources. This ultrasound-guided removal technique was included in that plan in consultation with the urologist on call. If allowed by the patient after an informed consent discussion it could be discussed with the urologist. It was also determined that in absence of obstruction or infection that 24–48-hour follow-up for cystoscopic removal was a potential option to decrease inpatient resource use. Decision-making capacity, especially in patients with underlying psychiatric illness, requires careful discussion and establishment of rapport to ensure that the patient understands the risks and benefits to any proposed procedure.

8 | CONCLUSION

Additional research regarding the ultrasound-guided foley catheter removal technique described here is warranted. Ultrasound can increase understanding about the nature of a urethral foreign body and support the decision for when urologic consultation should be sought or identify if bedside extraction can be safely performed. Bedside removal of urethral foreign bodies could save hospital admissions and reduce the need for operative endoscopic removal procedures. A multidisciplinary care plan may be needed to safely address repeat

visits in patients with a pattern of recurrent urethral foreign body placement.

CONFLICT OF INTEREST

The authors declare no conflict of interest for this article.

REFERENCES

1. Van Ophoven A, De Kernion JB. Clinical management of foreign bodies of the genitourinary tract. *J Urol*. 2000;164(2):274-287.
2. Palmer CJ, Houlihan M, Psutka SP, Ellis KA, Vidal P, Hollowell CM. Urethral foreign bodies: clinical presentation and management. *Urology*. 2016;97:257-260.
3. Nazir A, Runyon LC, Chowdhary S. From urethra with shove: bladder foreign bodies. A case report and review. *J Am Geriatr Soc*. 2006;54(9):1477-1478.
4. El Bote H, Hage E, Fares R. Corps étranger inhabituel intra-urétral: à propos d'un cas [An unusual intraurethral foreign body: a case report. *Pan Afr Med J*. 2017:27.
5. Mitterberger M, Peschel R, Frauscher F, Pinggera GM. Allen key completely in male urethra: a case report. *Cases J*. 2009;2(1):7408.
6. Raslan M, Donaldson J, Royle J. Penile self-harm: a case report and concise clinical review. *Scand J Urol*. 2015;49(4):341-343.
7. Breyer BN, Shindel AW. Recreational urethral sounding is associated with high risk sexual behaviour and sexually transmitted infections. *BJU Int*. 2012;110(5):720-725.
8. Smith PM, Harbias A, Robinson R, Palmer A, Grey BR. Isiris: a novel method of removing foreign bodies from the lower urinary tract to avoid unnecessary hospitalization and anesthesia. *J Endourol Case Rep*. 2016;2(1):144-147.
9. Floyd Jr M, Mistry R, Williamson E, Machin D, Baird A. Urology on the inside: managing the needs of the incarcerated. *J Clin Urol*. 2013;6(2):100-105.
10. Floyd Jr MS, Baird AD. An unusual case of polyembolokolamania: urethral avulsion from foreign object use during sexual gratification. *Can Urol Assoc J*. 2016;10(9-10):357.
11. Tseng H-J, Hanna TN, Shuaib W, Aized M, Khosa F, Linnau KF. Imaging foreign bodies: ingested, aspirated, and inserted. *Ann Emerg Med*. 2015;66(6):570-582.e575.
12. Kirkham CL, Monks SM, Crawford SB. Complications of subcutaneous penile modifications: a discussion of emergency department presentations and management. *Int J Emerg Med*. 2019;12(1):1-5.
13. Fischer N, Hauser S, Brede O, Fisang C, Müller S. Implantation of artificial penile nodules—a review of literature. *J Sexual Med*. 2010;7(11):3565-3571.
14. Talati J. Urethral dilatation. *J Pak Med Assoc*. 1989;39(3):79.
15. Bhat GS, Shivalingiah M, Nelivigi GG, Ratkal C. The size of external urethral meatus on maximum stretch in indian adult males. *Indian J Surge*. 2014;76(1):85-89.

SUPPORTING INFORMATION

Additional supporting information may be found online in the Supporting Information section at the end of the article.

How to cite this article: Crawford SB, Lowry D, Watts SH. Evaluation and management of urethral foreign bodies and description of a novel ultrasound-guided catheter-based extraction technique. *JACEP Open*. 2021;2:e12398. <https://doi.org/10.1002/emp2.12398>