

Fusing of Preoperative Magnetic Resonance and Intraoperative O-arm Images in Deep Brain Stimulation Enhance Intuitive Surgical Planning and Increase Accuracy of Lead Placement

Hideki ATSUMI¹ and Mitsunori MATSUMAE¹

¹Department of Neurosurgery, Tokai University School of Medicine, Isehara, Kanagawa, Japan

Abstract

Intraoperative fluoroscopy and microelectrode recording (MER) are useful techniques for guiding lead placement in deep brain stimulation (DBS). Recent advances in magnetic resonance imaging (MRI) have enabled information on the location of the basal ganglia, as the target of DBS, to be obtained preoperatively. However, intraoperative images with few artifacts are required to enable accurate fusion of preoperative imaging data with intraoperative lead position data. With our method, we first fuse preoperative MRI and pre-frame fixed computed tomography (CT) images, then fuse the CT images exactly after mounting the frame, using this fusion image as a *platform image*. Compared with before and after frame fixation, the pre-frame fixed CT has less artifacts, facilitating the identification of soft tissues such as the ventricles and cortical surface on pre-frame fixed CT images. By fusing the structural information for these soft tissues between pre-frame fixed CT and MR images, this fusion process can provide improved accuracy that is intuitively understood by the surgeon. Using *platform images*, surgical planning and intraoperative lead positioning can then be evaluated on the same coordinate axis. Positional data on the lead acquired as three-dimensional (3D) data are then added to the platform image. The proposed surgical steps permit the acquisition of accurate lead position data.

Keywords: deep brain stimulation, computed tomography, magnetic resonance imaging, image fusion, stereotactic procedure

Introduction

In deep brain stimulation (DBS), accurate electrode placement and the avoidance of complications are key goals of surgery.¹⁾ Recent advances in magnetic resonance imaging (MRI) have proven helpful in providing positional data on the basal ganglia, as the target of the procedure, for surgical planning.²⁾ Using imaging software to fuse positional data on the target obtained from preoperative MRI with positional data on the lead obtained from intraoperative computed tomography (CT) provides an understanding of the relationship between the target and the lead, improving surgical accuracy. If

three-dimensional (3D) images are scanned intraoperatively, software that can reconstruct images in any desired cross-section from multi-slice images is very helpful to surgeons, making it easier to grasp the relationship between the positions of the lead and the target. Intraoperative CT is currently coming into use to obtain 3D data on lead placement during the procedure.³⁾ The O-arm (Medtronic, Minneapolis, MN, USA) is widely used for intraoperative cone-beam CT. Since the first report describing the use of this device for DBS surgery by Caire et al.,⁴⁾ it has come to be used for DBS as a device capable of providing both two-dimensional (2D) fluoroscopy and 3D CT images. However, the scope of 3D imaging with the early O-arm was limited, resulting in difficulty including the entirety of the Leksell frame CT indicator. With the advent in 2016 of the next-generation O-arm 2 (O-arm) (Medtronic), the 3D imaging area expanded from 21 cm × 16 cm to 40 cm × 30 cm, enabling the entire head to be imaged with

Received September 15, 2020; Accepted January 7, 2021

Copyright© 2021 by The Japan Neurosurgical Society This work is licensed under a Creative Commons Attribution-NonCommercial-NoDerivatives International License.

Table 1 Summary of cases

Case	Preparation time (min)	Procedure	DAP total (mGy·cm ²)	Irradiation (sec)	Shots (times)	DLP total (mGy·cm)	Euclidean distance (Surgical planning - 3DCT in mm)
Case 1		Fluoroscopy	10085	208.0			
Bilateral STN-DBS	180	3D image acquisition			5	1154	1.51
Case 2		Fluoroscopy	1052.5	19.7			
Unilateral GPi-DBS	120	3D image acquisition			7	4744	2.56
Case 3		Fluoroscopy	740.8	12.8			
Bilateral STN-DBS	74	3D image acquisition			9	3581	1.32
Case 4		Fluoroscopy	797.2	16.0			
Unilateral STN-DBS	45	3D image acquisition			3	1518	1.48
Case 5		Fluoroscopy	1021	18.1			
Bilateral STN-DBS	62	3D image acquisition			4	1378	1.62

3D: three-dimensional, CT: computed tomography, DAP: dose-area product, DBS: deep brain stimulation, DLP: dose-length product, Gpi: globus pallidus internus, STN: subthalamic nucleus.

the Leksell frame CT indicator fitted. We have devised a method using the O-arm that starts by fusing preoperative MR and CT images, then fuses this preoperative MRI-CT fusion image with intraoperative CT images, including data on stereotactic positional relationships with the stereotactic surgery device and intracranial structures as a new step in DBS surgery. We here describe the utility of this method as a DBS surgical technique, the optimum CT imaging procedure, and exposure associated with CT scanning.

Technical Note

Between July 2019 and July 2020, four patients underwent subthalamic nucleus (STN)-DBS and one underwent globus pallidus internus (GPi)-DBS to treat Parkinson's disease. Unilateral DBS was conducted in two cases and bilateral DBS in three, with surgery performed using the O-arm (Table 1).

Surgical steps (Fig. 1)

All patients underwent 3-T MRI (Ingenia 3.0-T; Philips Medical Systems, Best, the Netherlands). Fluid-attenuated inversion recovery (FLAIR)-3D volume isotropic turbo spin-echo acquisition (VISTA) scans were obtained before the day of surgery. Additional preoperative volumetric CT (Siemens SOMATOM Definition Flash; Siemens Healthcare, Erlangen, Germany) imaging was performed in three cases (Cases 3–5) (Fig. 2A).

These preoperative images were transferred to StealthStation S8 (Medtronic). Surgical planning and intraoperative navigation were performed using FrameLink software (Medtronic). In the operating room, patients underwent O-arm 3D CT imaging using an open CT indicator (Elekta AB, Stockholm, Sweden) after the Leksell G frame (Elekta AB) was fixed to the head. Preoperative and intraoperative images were integrated on the StealthStation S8 and used for surgical planning. Anatomical targeting was performed using MRI for DBS targeting, and CT images were used to integrate the preoperative and intraoperative O-arm 3D CT images. Preoperative MRI and pre-frame fixation images were used primarily to confirm the integration accuracy of the anatomical structures such as ventricles and cortical surface, and bone information from pre- and post-frame fixation CT images was used to confirm the accuracy of integration for preoperative and intraoperative images, as *platform images* (Figs. 2B and 2C).

The DBS procedure was undertaken by the usual method with the use of microelectrode recording (MER) for intraoperative electrophysiological recording (Fig. 2D). After MER, microelectrode position was confirmed by O-arm fluoroscopy and O-arm 3D-CT (Fig. 3A). The DBS lead was then positioned, O-arm 3D CT was performed, and data were transferred to the StealthStation for fusion with *platform images* using FrameLink to enable intraoperative confirmation

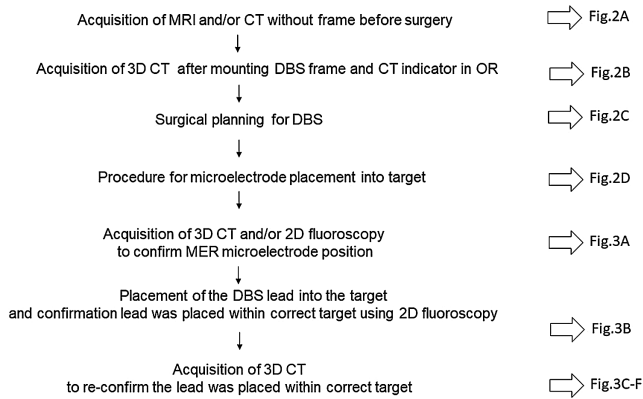


Fig. 1 DBS surgical procedure using the O-arm. 3D: three-dimensional, 2D: two-dimensional, CT: computed tomography, DBS: deep brain stimulation, MER: microelectrode recording, MRI: magnetic resonance imaging, OR: operating room.

that the lead has been guided into the target (Figs. 3B–3F).

Study parameters

We investigated device interference, image quality, time from entering operating room to establishment of the preoperative plan, electrode tip coordination from intraoperative O-arm 3D CT and the preoperative surgical plan, number of scans, and CT exposure.

Interference between treatment apparatus and CT

The aperture of the O-arm gantry was sufficient for the use of the Leksell frame and Multipurpose Stereotactic Arc, and the device provided good-quality 2D and 3D images for intraoperative confirmation of the electrode position (Fig. 3). Images scanned after the Open CT indicator was fitted

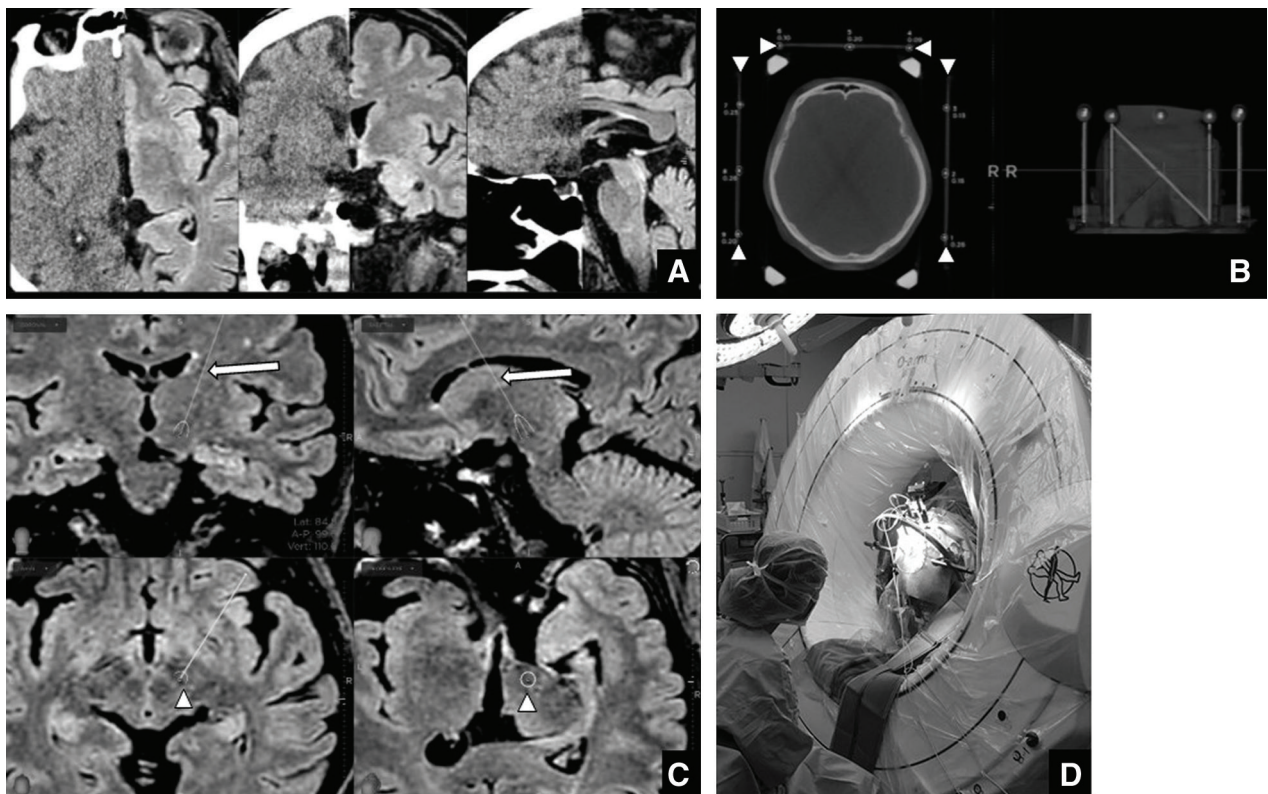


Fig. 2 Steps for image fusion and surgical planning. (A) Process of fusion image production from preoperative MRI and CT images by O-arm using FrameLink. (B) 3D image by O-arm after fitting the stereotactic frame and CT indicator. This shows the recognition of the CT indicator (arrowheads) on FrameLink. (C) To start, a platform with common coordinates for the different modalities is produced by fusing the preoperative MRI and CT images with the 3D CT images by O-arm. Next, the target (arrowheads) is designated on FrameLink using MR images on the common platform, via a route (arrows) that avoids the cerebral sulcus, cerebral ventricles, and vascular structures. (D) Intraoperative MER being conducted near the O-arm 2 gantry does not interfere with the O-arm being used for DBS. CT: computed tomography, DBS: deep brain stimulation, MER: microelectrode recording, MRI: magnetic resonance imaging, 3D: three-dimensional.

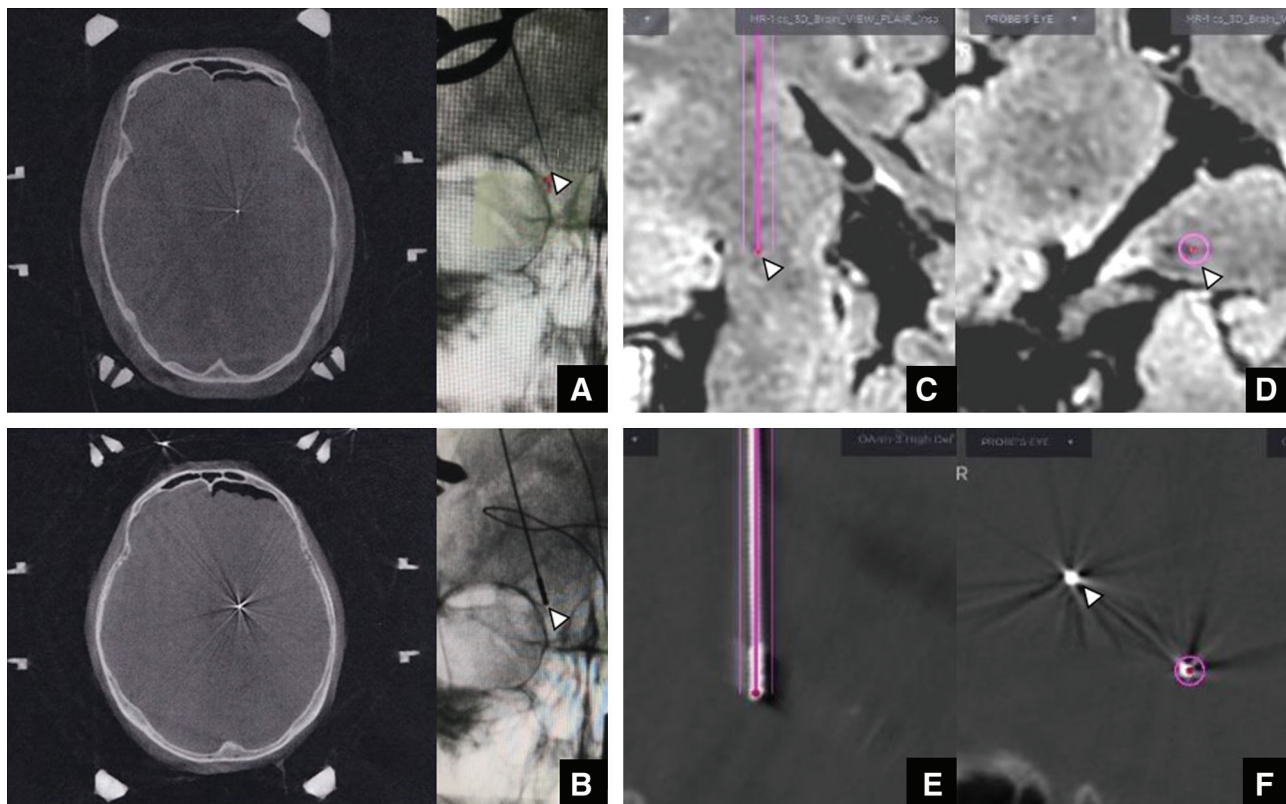


Fig. 3 The view of intraoperative imaging and confirmation of the lead position on surgical planning. (A) Microelectrode placement on 3D CT and 2D fluoroscopy images by O-arm. (B) Lead placement on 3D CT and 2D fluoroscopy images by O-arm. On the 2D fluoroscopy image, positions of the microelectrode and lead (arrowhead) coincide. (C, D) Surgical planning for the target (arrowhead) on MRI on the platform with the same coordinate system as computed tomography (CT by O-arm) images. (E, F) Images from 3D CT by O-arm of the inserted lead (thick white line) in two different axes on the platform with the same coordinate system as the MRI. The pink line shows the surgical plan. The lead can be seen to be inserted toward the target following the surgical plan shown by the pink line. In (F), the DBS electrode already inserted at the target on the opposite side is also visible in the same slice (arrowhead).

covered the entire extent required for treatment, including the CT indicator (Fig. 2B).

Image quality

Images scanned after the Leksell frame had been fixed contained artifacts caused by the head pin, but the images acquired were sufficient to identify the positioning of microelectrode and DBS lead. We were therefore able to fuse preoperative MRI scans with CT images from which the shapes of the cerebral ventricles and cerebral parenchyma were identifiable, enabling the determination of a provisional target from the anterior commissure–posterior commissure line and the red nucleus, which are indirect indicators in DBS surgery, as well as the STN and GPi as the direct targets, on MRI using the fusion image. We next fused preoperative and intraoperative CT images using the cranium as the indicator, creating images containing stereotactic

positional data on the surgical apparatus and intracranial structures. The O-arm is capable of 3D imaging, enabling reconstruction in any direction by means of multi-planar reconstruction. Subsequently, the directions of insertion and the tips of the microelectrode and lead were identified using data obtained from FrameLink and from 2D fluoroscopy and 3D CT updates carried out during the procedure as required using the O-arm with the frame fitted. This enabled the orientations and depths of the microelectrode and lead to be adjusted as appropriate while checking for differences between actual positions and the surgical plan, resulting in safe completion of surgery (Fig. 3).

Time required for the procedure, number of scans, and exposure

Previously, CT indicator images had to be scanned by moving the patient to a CT scanning room after

the frame was fitted in the operating room, then returning them to the operating room. The use of the O-arm offers two advantages in this regard: first, it eliminates the time-consuming transfer to a CT scanning room; and second, the scan is conducted with the patient in the same position in which surgery is performed. When the O-arm was first installed, the determination of surgical coordinates was a time-consuming process of trial and error. However, as shown in Table 1, after a steep learning curve, this has improved to the point where the time required for surgical planning for bilateral surgery has been shortened to only 62 minutes. 3D scanning with the O-arm took 26 seconds, and 4–5 minutes was required for image transfer and integration by the program.

CT exposure with the O-arm to confirm the positions of the microelectrode and lead was kept to the absolute minimum (Table 1). To reduce the number of 3D scans performed, 2D fluoroscopy using the O-arm was also conducted when required to visualize the relationship between the position of the lead and its target and to adjust the position of the lead tip, enabling total exposure to be reduced as a result. Table 1 shows the exposure during each procedure. Although some differences existed between uni- and bilateral surgeries, 2D fluoroscopy was used frequently in Cases 1 and 2 and 3D CT was used frequently in Cases 2 and 3, whereas in Cases 4 and 5, appropriate numbers of 2D fluoroscopy and 3D CT scans were successfully determined.

Accuracy of lead implantation

Euclidean distances between the electrode coordinates of the 3DCT images taken intraoperatively and the electrode coordinates from the preoperative surgical plan were measured, ranging from 1.32 to 2.56 mm (Table 1).

Discussion

Value of 3D image acquisition and MRI fusion images

Previously reported intraoperative CT methods have simply fused MRI and intraoperative CT⁵⁾ or preoperative MRI and intraoperative CT after electrode implantation,⁶⁾ or used fiducial markers on the scalp.⁷⁾ None of those three reports mentioned the image quality of intraoperative CT, particularly artifacts from the frame and lead. The present paper offers some originality as the first to perform soft-tissue fusion between MRI and pre-frame fixed CT, providing an image without artifacts. We then took steps to fuse the pre-frame fixed CT and MRI with the fixed CT image exactly after frame placement, using the bony structures. The result is an image

in which the coordinate axes after fixed the frame is completed, so we use this fusion image as a *platform image*. Using this platform image, surgical planning and intraoperative lead positioning can be evaluated on the same coordinate axis thereafter.

In the field of neurosurgery, surgical assistance with the O-arm makes it easy to use 3D images in combination with a surgical navigation system, and use of this option in spinal surgery is expanding.⁸⁾ Compared with MRI, 3D CT images provide limited resolution of soft tissue. Particularly in DBS surgery, the presence of the stereotactic brain surgery apparatus generates artifacts that make the assessment of brain structures more difficult. Currently, generation of artifacts due to the head frame or other surgical devices is unavoidable when preoperative MRI and intraoperative CT images are fused, and the acquisition of intraoperative data on electrode position is dependent on either 2D fluoroscopy or electrophysiological judgments using MER.⁹⁾ We therefore started by fusing data on the STN or GPi as the target and the surrounding structures obtained from preoperative MRI with 3D CT images providing information on intracranial structures such as the cerebral ventricles that were scanned before fitting the Leksell frame. We then carried out image processing using FrameLink software, obtaining data on the electrode position from intraoperative 3D CT data acquired as needed as the procedure progressed, to increase the surgeon's level of confidence in the treatment plan. Thus incorporating CT images lacking any artifacts caused by the surgical apparatus between preoperative MRI and intraoperative CT images and sharing stereotactic data obtained via both modalities, we have been able to make use of the excellent visualization of the lead provided by intraoperative CT in performing DBS, and report this here as a technical note.

Exposure

Table 1 shows the radiation exposure entailed in surgery. Although exposure is not an accurate measure of the dose received by the patient, the dose-length product for unilateral procedures was around the same as that of a single regular CT scan (1000–1500 mGy cm²). The index for standard patient exposure during endovascular therapy for an aneurysm is described as the dose entailed by around 4–6 cranial CT scans, suggesting that even the estimated dose for bilateral DBS is within acceptable limits.¹⁰⁾

Accuracy

Overall positional error for the O-arm is reported to be within 0.5 mm.¹¹⁾ Studies of the accuracy of the position of the microelectrode tip on MRI scans after DBS using the O-arm have found that a mean

error of 1.55–1.65 mm, with no detectable difference compared with conventional DBS.^{12,13)} Many sources of error are conceivable, including scanning-related artifacts and errors arising during the fusion of the images used, but those errors arising when a stereotactic brain surgery frame is used are considered to remain within acceptable limits. Factors such as intraoperative CSF leakage, degree of pneumocephalus, body position, burr hole sealing, and number of punctures have been investigated as causes of lead position accuracy.¹⁴⁾ However, the resolution of the O-arm makes it difficult to confirm brain parenchyma misalignment intraoperatively. Reduction of pneumocephalus during sedated DBS can improve the accuracy of electrode position, and the use of intraoperative imaging remains a potential way to identify and improve the accuracy of intraoperative pneumocephalus.

Conclusions

We adapted the imaging procedures used in DBS surgery by first fusing preoperative MRI and CT images, then using imaging software to fuse the resultant image with intraoperative CT images that included the stereotactic apparatus, using a platform for sharing 3D images between modalities. We concluded that the O-arm facilitated identification of the position of the electrode tip in three dimensions, providing meaningful data that enabled the operator to confidently proceed with the operation while also reducing radiation exposure to the patient.

IRB

This study was approved by the ethics committee of our institution (titled “Usefulness for intraoperative mobile CT (O-arm type2) for stereotactic functional surgery” accepted on August 3, 2020; No. 20R-144.)

Acknowledgment

The authors thank Dr. Tanefumi Baba for his clinical assistance.

Conflicts of Interest Disclosure

The authors report no conflicts of interest for this work.

References

- 1) Sugiyama K, Nozaki T, Asakawa T, Koizumi S, Saitoh O, Namba H: The present indication and future of deep brain stimulation. *Neurol Med Chir (Tokyo)* 55: 416–421, 2015

- 2) Toda H, Sawamoto N, Hanakawa T, et al.: A novel composite targeting method using high-field magnetic resonance imaging for subthalamic nucleus deep brain stimulation. *J Neurosurg* 111: 737–745, 2009
- 3) Hunsche S, Maarouf M, Neudorfer C: High-resolution O-arm data reconstruction for optimized intraoperative imaging of deep brain stimulation leads: a preclinical study. *Oper Neurosurg (Hagerstown)* 18: 403–408, 2020
- 4) Caire F, Gantois C, Tornay F, Ranoux D, Maubon A, Moreau JJ: Intraoperative use of the medtronic O-arm for deep brain stimulation procedures. *Stereotact Funct Neurosurg* 88: 109–114, 2010
- 5) Mirzadeh Z, Chapple K, Lambert M, Dhall R, Ponce FA: Validation of CT-MRI fusion for intraoperative assessment of stereotactic accuracy in DBS surgery. *Mov Disord* 29: 1788–1795, 2014
- 6) Frizon LA, Shao J, Maldonado-Naranjo AL, et al.: The safety and efficacy of using the O-arm intraoperative imaging system for deep brain stimulation lead implantation. *Neuromodulation* 21: 588–592, 2018
- 7) Holloway K, Docef A: A quantitative assessment of the accuracy and reliability of O-arm images for deep brain stimulation surgery. *Neurosurgery* 72: 47–57, 2013
- 8) Mao G, Gigliotti MJ, Myers D, Yu A, Whiting D: Single-surgeon direct comparison of O-arm neuro-navigation versus Mazor X robotic-guided posterior spinal instrumentation. *World Neurosurg* 137: e278–e285, 2020
- 9) Maruo T, Saitoh Y, Hosomi K, et al.: Deep brain stimulation of the subthalamic nucleus improves temperature sensation in patients with Parkinson's disease. *Pain* 152: 860–865, 2011
- 10) Rehani MM, Ciraj-Bjelac O, Vano E, et al.: ICRP Publication 117. Radiological protection in fluoroscopically guided procedures performed outside the imaging department. *Ann ICRP* 40: 1–102, 2010
- 11) Katisko JP, Kauppinen MT, Koivukangas JP, Heikkinen ER: Stereotactic operations using the O-arm. *Stereotact Funct Neurosurg* 90: 401–409, 2012
- 12) Shahlaie K, Larson PS, Starr PA: Intraoperative computed tomography for deep brain stimulation surgery: technique and accuracy assessment. *Neurosurgery* 68: 114–124; discussion 124, 2011
- 13) Smith AP, Bakay RA: Frameless deep brain stimulation using intraoperative O-arm technology. *Clinical article. J Neurosurg* 115: 301–309, 2011
- 14) Ko AL, Magown P, Ozpinar A, Hamzaoglu V, Burchiel KJ: Asleep deep brain stimulation reduces incidence of intracranial air during electrode implantation. *Stereotact Funct Neurosurg* 96: 83–90, 2018

Corresponding author: Hideki Atsumi, MD, PhD

Department of Neurosurgery, Tokai University School of Medicine, 143 Shimokasuya, Isehara, Kanagawa 259-1193, Japan.
e-mail: h-atsumi@is.icc.u-tokai.ac.jp